

A CASE REPORT OF CAPITELLUM FRACTURE TREATED USING HERBERT SCREW.

ABSTRACT:

Capitellar fractures are intra-articular elbow injury & it is a uncommon type of elbow injuries that can cause and affect severe functional limitation if not treated correctly. Various treatment options have evolved, from cast immobilization, closed reduction fixation to open reduction fixation. This treatment options allows excellent fixation to the fracture site and helps in achieving a stable joint that help in early mobilization of the elbow joint after trauma. This is a case report of capitellar fractures, a typical Hahn-Steinthal fracture of left elbow joint in a 14 year old adolescent male treated using Herbert's screw fixation. Here after three months of post-op follow-up it shows good interfragmental compression, early mobilization, excellent recovery & Implant removal is rarely necessary.

INTRODUCTION:

Capitellar fractures are uncommon type of fractures that represent only 1% of all elbow injuries. These types of fractures are less common under the age of 12; since it is formed by cartilaginous composition makes it resistant to stress^{1,2}. Whereas in older children it become prominent to shear injuries. Capitellum fractures are intra-articular fracture where it does not involve the growth plate or condyles³. This kind of fractures are often get confused with fracture of lateral humeral fracture. So it is important diagnosis correctly and plan for surgery accordingly.

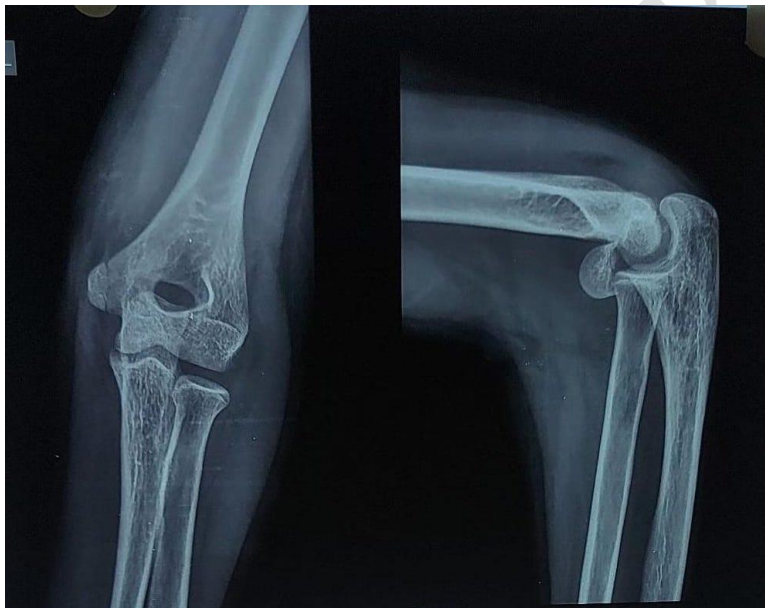
CASE REPORT:

14year old adolescent male presented with complaints of pain over the left elbow joint associated with swelling around the elbow joint. Patient had alleged H/O Trauma after which he developed pain & swelling around the joint. Patient had restriction of motion due to severe pain, without any neurovascular deficit.

ON RADIOGRAPHIC EXAMINATION:

X-Ray shows left capitellum fracture (Bryan and morrey classification type -1 (Hahn-steinhal) fracture. CT study of left elbow shows – Displaced fracture of capitellum of humerus with ulno-humeral and proximal radio-ulnar joint alignment grossly maintained surrounding fat tissue edematous changes around the elbow joint noted.

Fig 1:



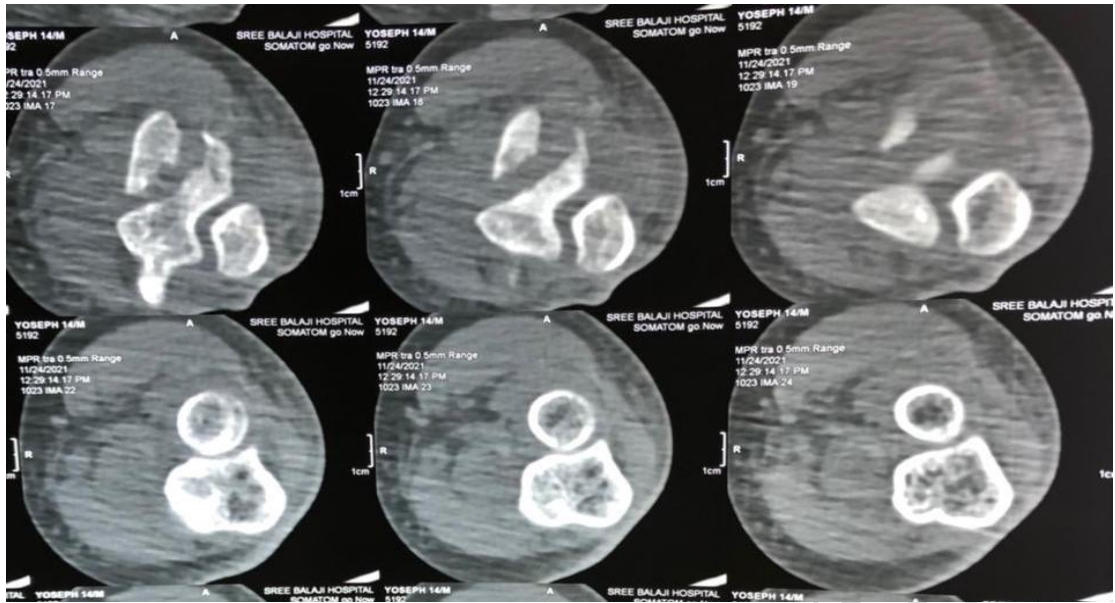
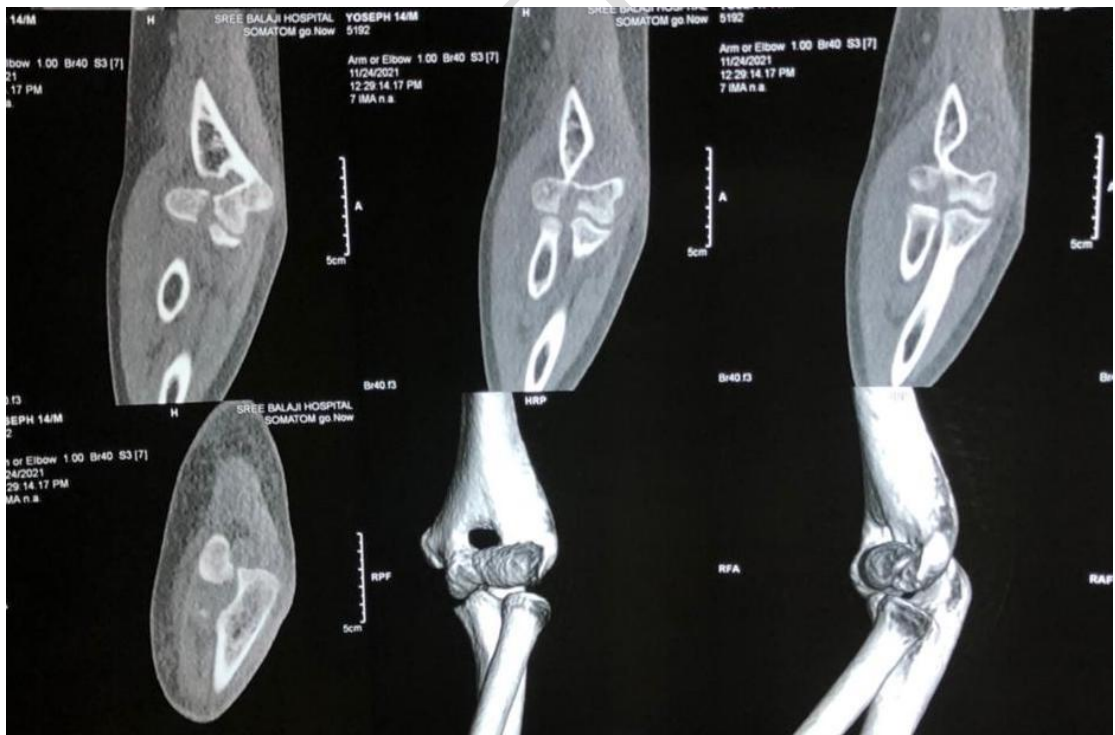


Fig 2:

Fig 3:



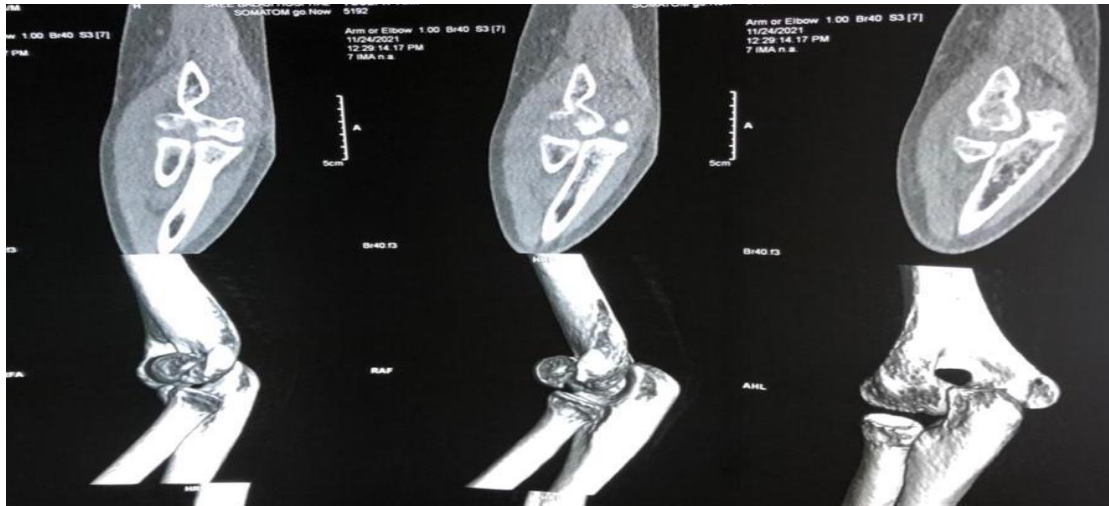
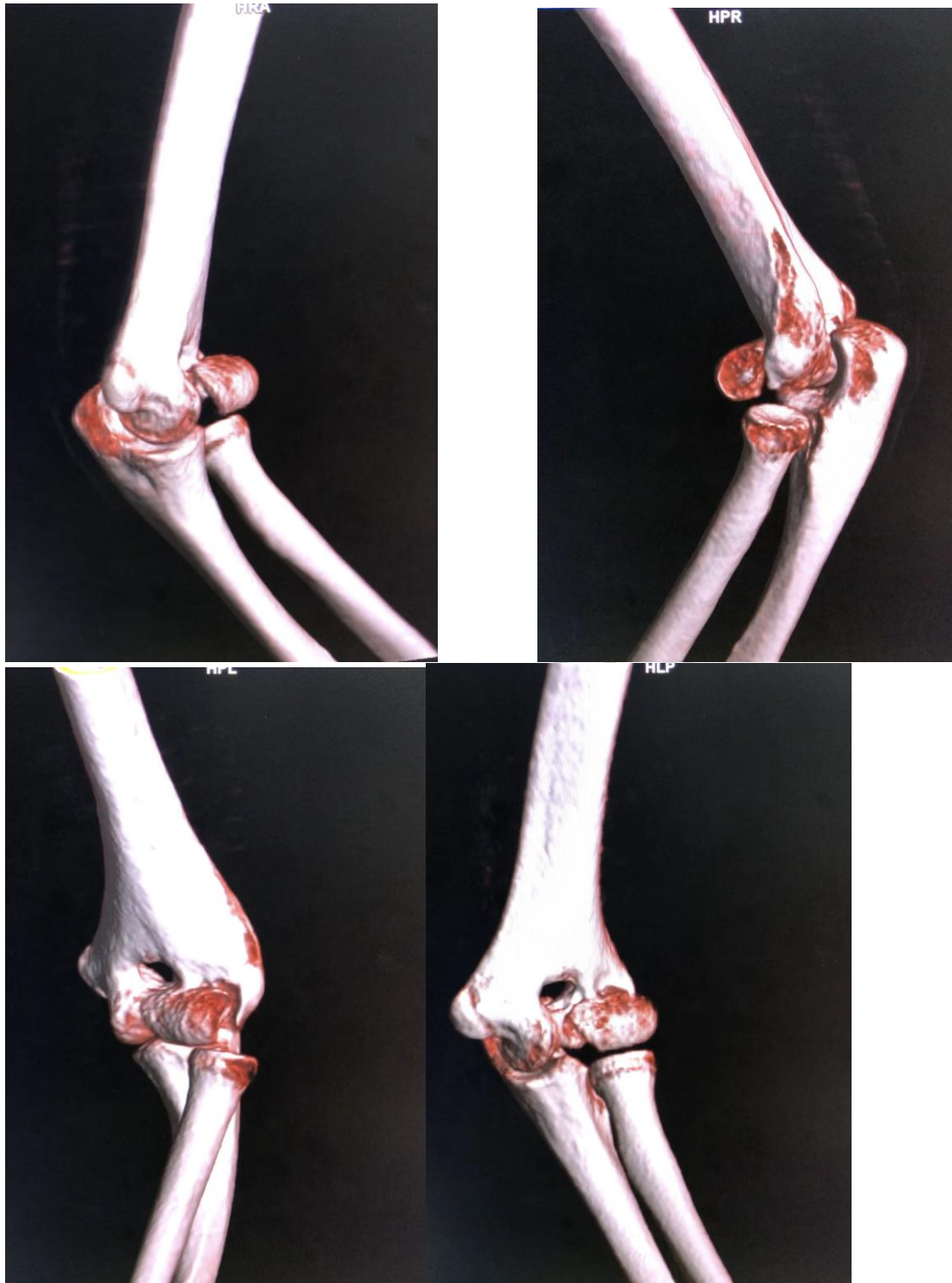


Fig 4:

UNDER PEER REVIEW



Since the x-ray and CT images are consistent with diagnosed of Capitellum fracture. Patient was performed open reduction internal fixation with Herbert's screw fixation. Patient in supine position, approach – posterolateral (KOCHER'S), Incision of size 10cm made over the lateral epicondyle. Proximally extending along the lateral supracondylar ridge distally extending in the line of radial head. Skin & subcutaneous tissue cut and retracted, Anconeus and extensor carpi ulnaris muscles are identified ,

cut and retracted. Fracture site identified & annular ligament is surgically dissected, fracture site reduced using Guide wire & Herbert screw of size 2.5 x 22mm & 2.5 x 28mm placed in position. Fracture site reduced. Annular ligament tied and suture. Wound closed in layers. Above elbow slab applied.

Image 1: INTRA-OP PICTURES

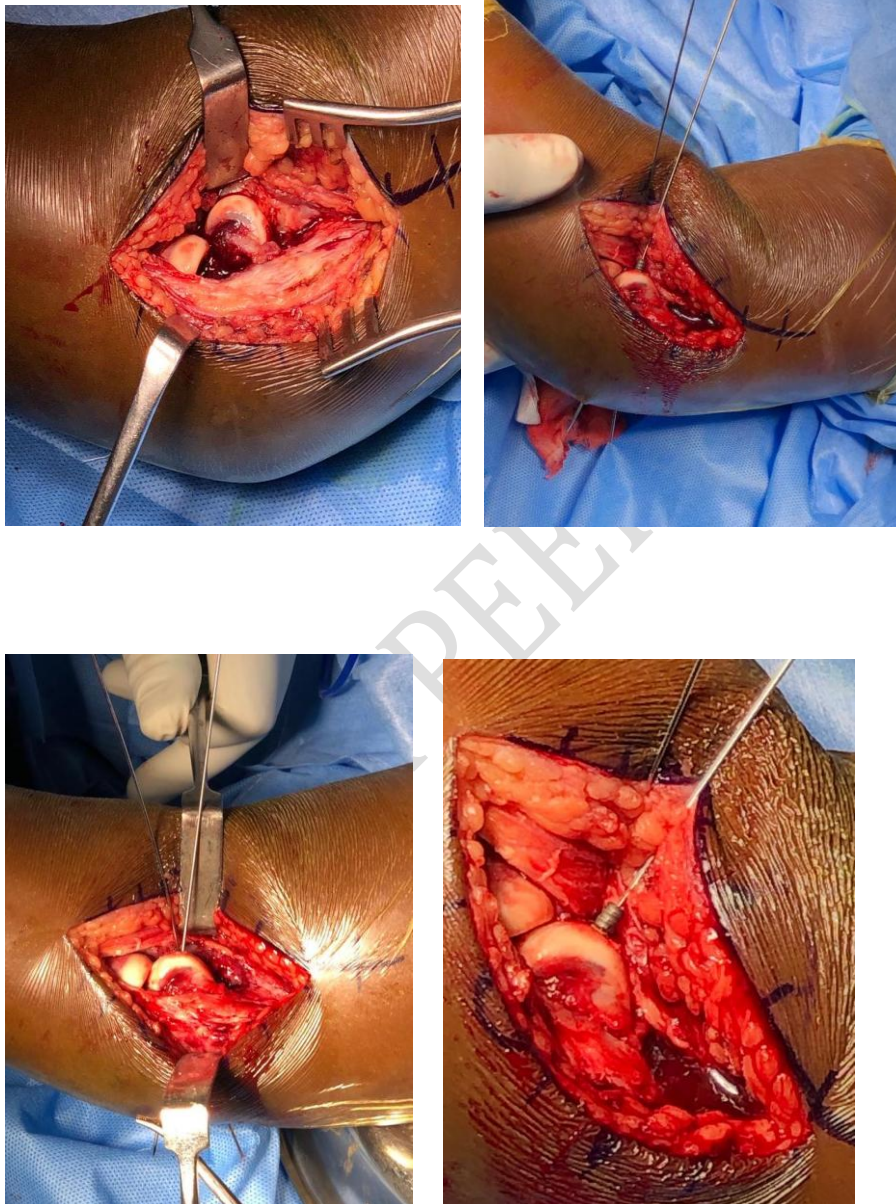


Image 2 C-ARM PICTURE :

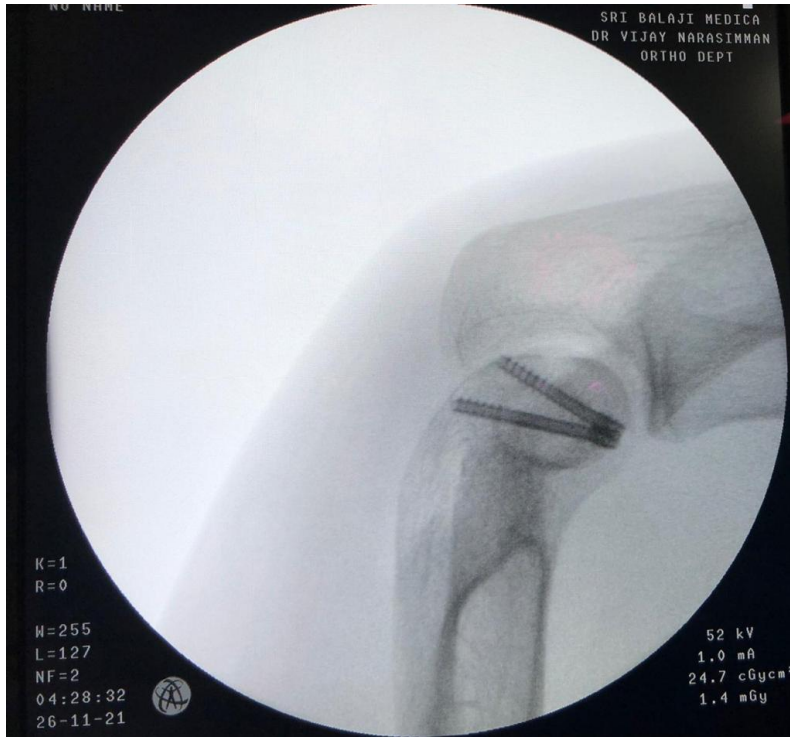
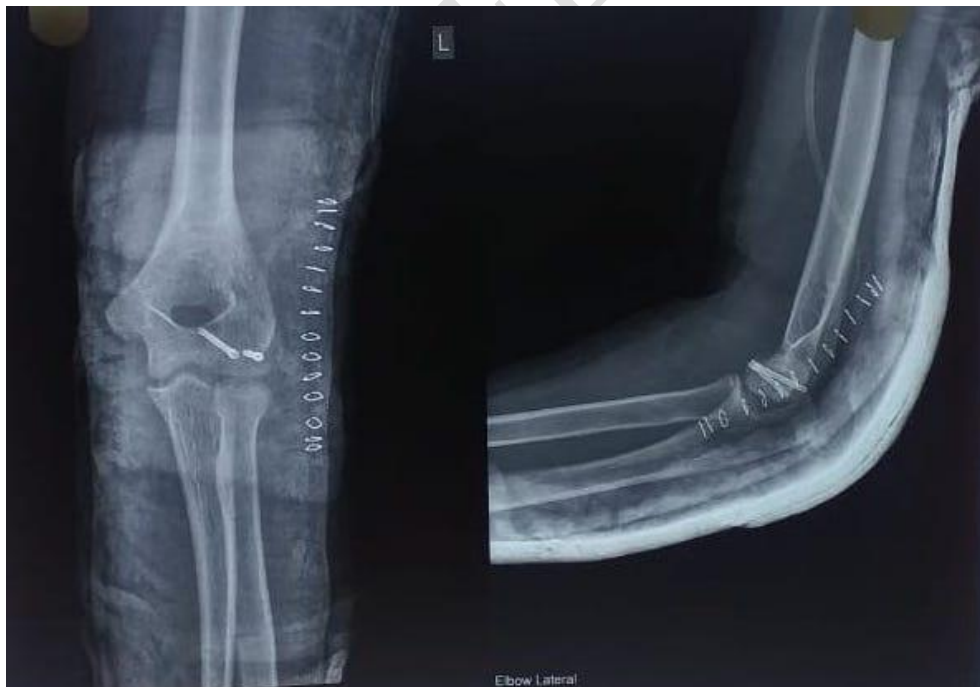
Image 3 Post-op x-ray:



DISCUSSION :

Capitellum fracture type -1 Hahn-Steinthal fracture is uncommonly seen in children below the age of 12years. It is important to diagnosis correctly because its often get mis-diagnosed due to its fracture pattern, that can lead to significant joint instability and restriction of motion. So its always significant to do CT scan with 3D reconstruction to find out the fracture pattern, articular impaction & whether any condylar comminution is associated or not⁶.

Closed reduction internal fixation is one of the treatment option that can used to reduced the fracture fragment but it is difficult to achieve fracture reduction correctly and may lead to poor union & reduced range of motion, whereas in internal fixation with K-wire is one of the preferable method but however it penetrate the articular surface & also does not provide stable fixation⁵. So, Herbert screw fixation provides absolute fracture fixation and early mobilization of the elbow joint.

In our case, it is a capitellum fracture - Bryan and morrey (type-1), the treatment option chosen was open reduction internal fixation with Herbert screw fixation. With allow accurate inter-fragmentally compression & stability. Which provide excellent recovering phase by allowing early mobilization & achieve full range of motion⁷. Early fixation also reduced the chance of avascular necrosis & other complications like heterotopic ossification that can be caused due to prolonged immobilization⁸.

CONCLUSION :

Type -1 Hahn-steinthal capitellar fracture must be fixed anatomically to regain the articular congruity and achieve full range of motion of the elbow joint. This goal is achieved by fixing the fracture using ORIF with Herbert screw fixation. The main advantages being providing excellent interfragmental compression and early joint motion & the implant need not to be removed. Thus early surgical intervention and Herbert screw fixation help to achieve excellent functional outcomes among this age group.

REFERENCES:

1. Bryan RS, Morrey BF; fractures of distal humerus. The elbow and its disorders by Morrey BF. Philadelphia.
2. Poynton AR, Kelly IP, O'Rourke SK; fractures of the capitellum; a comparison of two fixation methods. Injury.1998.
3. Pradhan B, Bhasin D, Krom W: Capitellar fracture in a child; the value of an oblique radiograph. A Case report.
J Bone joint surg Am.
4. Pogliacomi F, Concari G, Vailenti E: Hahn-steinthal Fracture: report of two cases. Acta Biomed. 2005.
5. Boeck H, Pouliart N: fractures of the capitellum humeri In adolescents. Int Orthop. 2000
6. Johansson J, Rosman M: fracture of the capitellum Humerus in children: a rare injury, often misdiagnosed. Clin Orthop.1980.
7. Herring JA: Tachdjian's pediatric orthopaedics.2008, Philadelphia: saunders Elsevier.
8. Mckee MD, Jupiter JB, Bamberger HB; Coronal shear Fractures of the distal end of the humerus. J bone joint surg AM.1996.