

Original Research Article

Neuroimaging Assessment of Aggressive Pituitary Adenomas

Abstract

Aggressive pituitary adenomas (APA) are adenomas that show rapid growth, invasiveness, frequent or multiple relapses, or are resistant to conventional therapies. Clinical-imaging assessment of aggressive pituitary adenomas ~~using the aid~~ plays an important role in early ~~predicting~~ and predicting further disease outcomes and aggressive behavior of adenomas.

Purpose of the study was to assess the correlation of neuroimaging data with the hormonal activity of APA. **Materials and methods.** The study included 74 patients with aggressive pituitary adenomas. The average age of the patients was from 12 to 69. The patients underwent a basal assessment of the level of pituitary hormones: prolactin (PRL), GH(growth hormone), insulin-like growth factor-1 (IGF-1) and blood cortisol by the RIA method, as well as an MRI study. Knop's classification was used to assess the invasion. **Results.** The ~~results of hormonal research have established that inactive pituitary adenomas prevail~~ among aggressive adenomas.

No correlation was found between the hormonal activity of aggressive adenomas and the volume of pituitary adenomas. ~~According to MRI data, it was also found~~ that invasion into the cavernous sinus of the III degree and heterogeneity of the adenoma ~~can become~~ equivalents of aggressiveness. **Conclusion.** The established patterns ~~determine~~ the need for visualization assessment of aggressive pituitary adenomas and ~~designation of their~~ degree of aggression based on tumor ~~heterogeneity~~, chiasm compression, hypo- and iso-intensity in T1 mode and hyperintensity in T2 modes.

Key words: aggressive pituitary adenomas, neuroimaging.

Introduction

Determination of aggressive behavior of pituitary adenomas relies heavily on imaging assessment of adenomas. ~~One of the criteria for aggressiveness is~~ the rapid growth of the tumor, invasiveness in adjacent tissues and tolerance to traditional therapy. [7] ~~As can be seen from the above, at least~~ 2 criteria are diagnosed by using magnetic resonance imaging (MRI), which emphasizes the essential role of MRI in the diagnosis of aggressive pituitary adenomas. [2]

In addition, MRI ~~diagnostics~~ can provide a prognostic assessment of tumor aggressiveness before surgical treatment. Moreover, the diagnosis of pituitary carcinoma (PC) is established only if imaging methods have revealed craniospinal or systemic metastases, which in turn

Comment [GG1]: "with the aid of magnetic resonance imaging (MRI)"

Comment [GG2]: "prediction"

Comment [GG3]: "Hormonal workup showed prevalence of inactive pituitary adenomas..."

Comment [GG4]: "Moreover, MRI data indicated..."

Comment [GG5]: "may be considered as..."

Comment [GG6]: support

Comment [GG7]: strongly suggest the evaluation of the

Comment [GG8]: heterogeneity

Comment [GG9]: "The criteria for aggressiveness include..."

Comment [GG10]: "in fact, at least the first ..."

Comment [GG11]: examination

determines the key role of MRI in the differential diagnosis of APA and PC. Accordingly, MRI examinations for patients with aggressive pituitary tumors should be assessed adequately and accurately as the primary prognostic diagnostic method. [3]

Comment [GG12]: Consequently,

Comment [GG13]: "examination" (singular)

Thus, in connection with the above, the role of visualization assessment of APA is sharply increased not only for establishing the correct diagnosis, but also for predicting the subsequent behavior of pituitary adenoma.

Comment [GG14]: (to be deleted)

Purpose of the study: to assess the correlation of neuroimaging data with the hormonal activity of APA.

Materials and research methods

We examined 74 patients with APA (35.1% men (n = 26) 64.8% women (n = 48)) The average age of the patients was from 12 to 69 (the average age was 46.5 ± 4.09 years). The diagnosis of APA was established on the basis of a carefully collected history, clinical-hormonal and imaging studies, and MRI results.

Comment [GG15]: range of the

In order to identify the hormonal activity of adenomas, all patients underwent a basal assessment of the levels of pituitary hormones as: PRL, GH, IGF-1 and blood cortisol level measured by the RIA method. All patients were divided into 4 groups depending on their hormonal activity: prolactinomas, ACTH-dependent Cushing's syndrome (ACTH.d.CS), acromegaly/GH-secreting adenomas and non-functional pituitary adenomas (NFPA).

All patients were treated with the introduction of contrast agents according to indications. Scanning technique: T2-TSE transversal projection, T2-TSE sagittal projection, T1-TSE, coronal projection, T1-TSE sagittal projection.

Comment [GG16]: "received"

Comment [GG17]: "The following Scanning technique was used."

According to the classification, the following visualization features were assessed:

1. The size of the adenoma was estimated in three projections.

Comment [GG18]: -

The adenoma volume was calculated using the Di-Chiro-Nelson 2 ellipsoid formula. The intersection of the tumor from the intercarotid lines (Knops) was assessed.

Comment [GG19]: -

Comment [GG20]: {No 2. Missing??}

Comment [GG21]: "assessed as"

- 0th degree, intact cavernous sinus
- 1st degree, spread of the tumor to the intracarotid line.
- 2nd degree, spread of the tumor to the lateral line of the tumor
- 3rd degree, spread of the tumor beyond the lateral line
- 4th degree, complete surrounding of the cavernous segment of the ICA with a tumor

3. Involvement of the sphenoid sinus.

4. Compression of the chiasm.

5. The shape of the tumor, a sign of lobular structure and non-uniformity.

6. Intensity in T1 and T2 modes.

7. Tumor necrosis and / or adenoma degeneration.

8. Apoplexy.

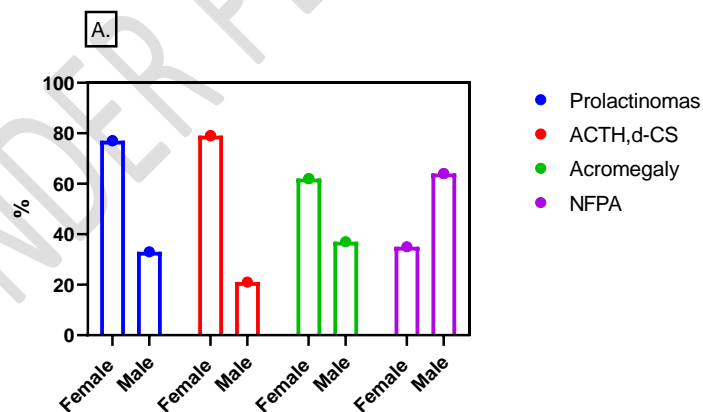
Statistical analysis of data was performed using Graphpad Prism 9 software. In descriptive analysis, continuous variables were summarized and expressed as median and inter or mean and standard deviation (based on distribution), and categorical variables were expressed as absolute values and percentages.

Pearson's coefficient and r^2 were calculated to assess the correlation.

Research results

According to the results of a hormonal study, prolactin-secreting pituitary adenoma was diagnosed in 29.3% (n = 22) of patients. From these, 77% are women (n = 17) 33% are men (n = 5). The mean age in the group was 36.14 (SDS ± 12.36). ACTH-dependent Cushing's syndrome was diagnosed in 25.3% (n = 19) of patients. From these, 79% are women (n = 15) and 21% are men (n = 4). The average age of the subjects was 32.42 (SDS ± 10.43). Somatotropin-secreting pituitary adenoma accounted for 21.3% (n = 16) of the studied, where 62% (n = 10) were women and 37% were men (n = 6). The average age in this group was 42.81 (SDS ± 12.04). 22.9% (n = 17) of patients were in the group of non-functional pituitary adenomas (NFPA) with an aggressive course, where the female gender was 35% (n = 6) and 64% were men (n = 11). The average age of patients in this group was 43.35 (SDS ± 15.93) (Fig. 1A, B)

Comment [GG22]: the Hormonal workup



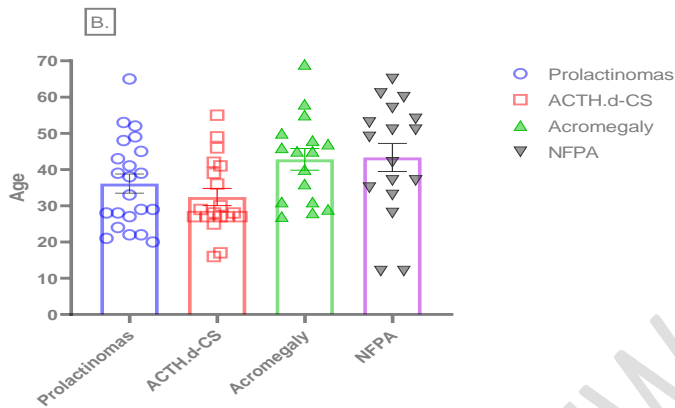


Figure 1. Age and sex characteristics of the main groups

The correlation between the hormonal activity of aggressive adenomas and the volume of pituitary adenomas was studied. According to the results of the study, in all study groups, there was no significant relationship between the levels of hormones such as prolactin ($P = 0.8884$), IGF-1, growth hormone ($P = 0.678$) and blood cortisol ($P = 0.02$) with the volume of adenoma (Fig. 2.A, B. and 3).

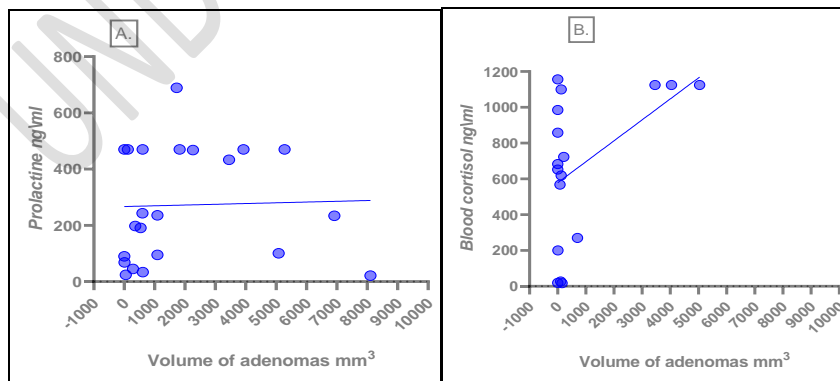


Fig 2. Correlation between the hormonal activity of prolactinomas (A) and ACTH.d.CS (B) with the volume of adenomas. Correlation coefficient according to Pearson (r) A = 0.03178; B = 0.5204; (R2) A = 0.001; B = 0.2708

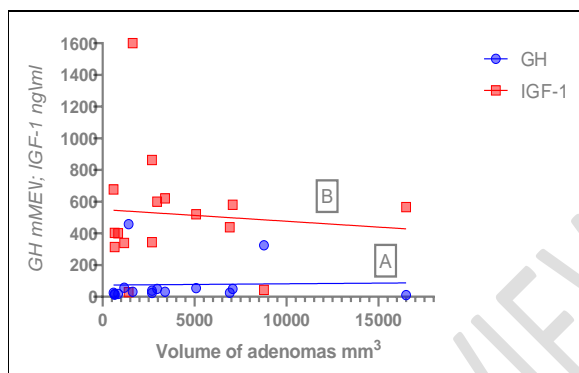


Fig 3. Correlation of hormonal activity of GH-secreting adenomas GH (A), IGF-1 (B) with the volume of adenomas. Correlation coefficient according to Pearson A = 0.02805; B = -0.08665. (R2) A = 0.0007870; (R2) B = 0.007509

Thus, the level of hormonal activity and the volume of adenoma cannot be predictors of aggressive behavior of adenoma.

Comment [GG23]: "were not"

Invasion into the cavernous sinus in the studied patients with aggressive pituitary adenomas was present in varying degrees. Grade 0 (intact cavernous sinus) -20% (n = 15), Grade I - 13.5% (n = 10), Grade II - 21.6% (n = 16), Grade III - 29.3% (n = 22) accounted for the largest part, where Grade IV-15.6% (n = 11). (Fig. 4A)

MRI studies showed that in patients with Grade III according to the Knosp Scale, an irregular tumor shape prevailed 49% (n = 10), a sign of lobular structure and heterogeneity in 61.1% (n = 13), and visual disturbances in the form of chiasmal syndrome 60.8% (13). In 36% (n = 7) of the subjects, focal erosion of the main sinus was observed, where the main symptom was rhinorrhea. 18.9% (n = 4) had a focal lesion of the central nervous system (CNS), where the complaint of patients with hypoacusia and ataxia prevailed. Destruction of adenoma and apoplexy, respectively, were observed in 27% and 9% of patients. (Fig. 4 B)

Comment [GG24]: heterogeneity

Comment [GG25]: "respectively."

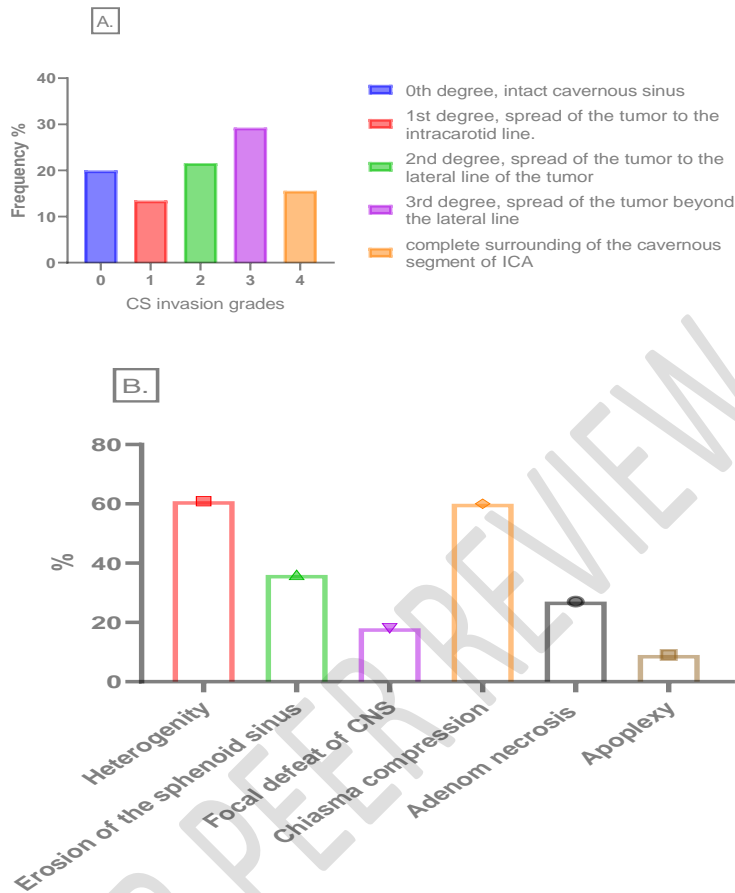


Figure 4.B: Knops classification of adenoma invasion into the cavernous sinus. B. Features of MRI imaging studies in patients with Grade III-invasion.

According to MRI data, invasion of the cavernous sinus of the III degree and heterogeneity of the adenoma can become equivalents of aggressiveness.

Comment [GG26]: "heterogeneity"

Comment [GG27]: "may be considered as.."

Comparative analysis of intensity in two modes of MRI T1 and T2 showed that APAs are iso-intensive (57.875% SD = ± 20.34) and hypointense (37.625% SD = 22.46) in T1 mode. In T2 mode 46.6% (SD = ± 16.85) hyperintense, 31.15% ((SD = ± 12.4) hypointense and 22.3% (SD = ± 16.8) isointense (Fig.5).

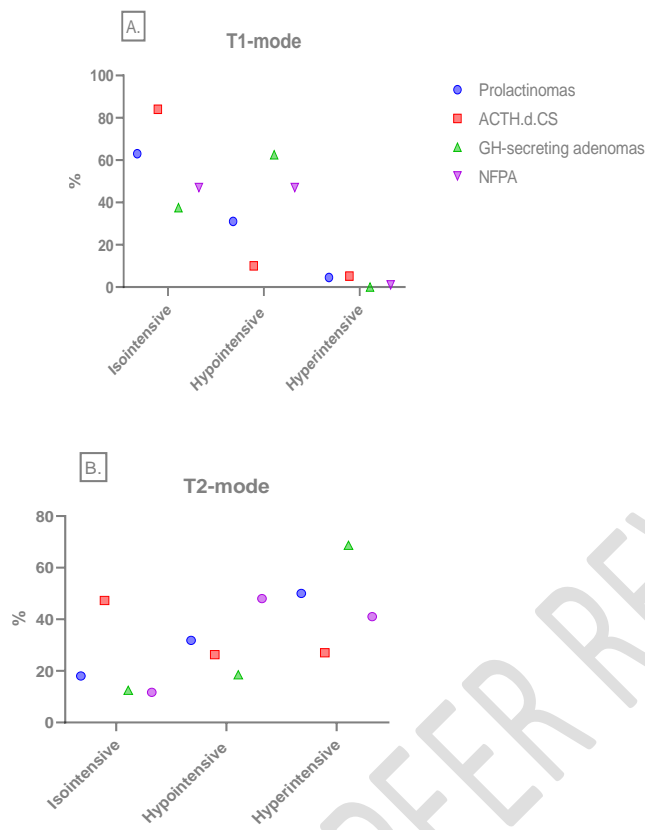


Fig 5. Intensity of AAG adenomas in T1 (A) and T2 (B) modes.

Discussion

Rapid growth is the main criterion for determining the aggressiveness of the tumor, but the volume of the adenoma is difficult to determine at an early stage, and dynamic MRI is usually performed every 6 months or every year. Today, in oncological practice, 3D-MRI is used to calculate changes in tumor volume, but this method is difficult to apply in the case of small sellar formations or remnants of the remnant tissue. In this regard, the main goal of APA diagnostics is to obtain the best reproducibility of MRI images and to compare the vertical, axillary and transverse diameters of the tumor on coronal sections with the calculation of the volume of the adenoma. [1]Adenoma growth progression is considered significant if > 20% at 6 months.

Invasion is the spread of an adenoma beyond a natural barrier such as bone or meninges. Assessing the extent of adenoma invasion into the basilar sinus or the cavernous sinus is challenging. Invasion into the sphenoid sinus is determined by the destruction or deformation of

Comment [GG28]: "to be determined"

the bone of the walls of the ~~sella turcica~~. In addition, with bone erosion, the tumor can progress through the sphenoidal sinus, towards the nasal cavity in front, destroying the hard palate and grow inside the oral cavity ~~from~~ below, affecting the clivus ~~from~~ behind and, finally, grow towards the occipital bone [9]. The coverage of the cavernous sinus gives a certain danger of surgical access, since this sinus plays a huge role in the regulation of intracranial blood circulation and the implementation of venous outflow from the brain and orbits. [5]

Comment [GG29]: "sella turcica" (2 words)

Comment [GG30]: -

Comment [GG31]: -

Moreover, the cavernous sinus occupies a special place due to the fact that branches of the internal carotid artery pass through it, as well as cranial nerves, such as the oculomotor nerve, the trochlear nerve, the branch of the orbital nerve, the maxillary nerve and the abducens nerve.

Thus, ~~on the one hand, invasion of the adenoma into the cavernous sinus is considered almost equivalent to the aggressiveness of pituitary tumors. At the same time, invasion of the cavernous sinus is only one criterion~~ for tumor aggressiveness. [6]

Comment [GG32]: "...there is a tendency, invasion of the adenoma into the cavernous sinus to be considered as almost an.."

Comment [GG33]: "...although it only represents one strong criterion.."

In fact, invasion of the cavernous sinus does not always mean aggressiveness, as some prolactinomas involving the cavernous sinus may respond to treatment with dopamine antagonists. But, despite significant progress in pituitary surgery, invasion of the adenoma into the cavernous sinus leads to surgical inaccessibility and remnant of the remnant tissue, which is especially evident for hormonally active pituitary adenomas. The coverage of the cavernous sinus by pituitary adenomas in most cases is unilateral, while the normal pituitary gland displaced to the side "protects" the contralateral cavernous sinus.

Cottier [4] suggests that the percentage of narrowing of the internal carotid artery by tumor tissue of more than 67% makes the invasion definite, ie, the positive predictive value is 100%. If this value is less than 25% or if the tumor does not pass the line connecting the medial wall of the intracavernous and supracavernous segments of the internal cavernous sinus, invasion can be excluded. However, it should be noted that the criteria based on Cottier MRI have been compared with the results of surgical interventions observed before the era of endoscopic neurosurgery, which is now considered more accurate for imaging cavernous sinus invasion. According to the observations of another scientist Sol [10], it was found that the capture of the membrane and narrowing of the internal carotid artery by an angle equal to 136.5° of the intracavernous ICA, was associated with a high probability of invasion into the cavernous sinus. According to the classification of E. Knosp [8], anatomical landmarks can help in the diagnosis of invasion of the cavernous sinus. According to this classification, invasion is "very likely" if the tumor extends laterally and passes a line drawn between the centers of the cross-section of the supra- and intracavernous segments of the internal carotid artery. But it is interesting to note that Xu [11] found sensitivity in only 47% of Knosp assessments in surgical practice with

Cushing's disease. In fact, if Knosp landmarks ~~can be~~ useful for classifying pituitary macroadenomas and are largely used in the literature, their practical interest is less ~~for individual cases, as well as for~~ differentiating true invasion from compression, and especially for limited invasion of the cavernous sinus located in its back.

Comment [GG34]: "are"

Comment [GG35]: ", but"

Comment [GG36]: when

Conclusions

1. The frequency of distribution of aggressive adenomas with invasive growth was ~~most frequent~~ in patients with inactive pituitary adenomas, in second place in patients with acromegaly and in third place in patients with prolactinomas.

Comment [GG37]: "higher"

2. Hormonal ~~assessment~~ showed that the level of hormonal activity and the volume of adenoma are not correlated, which confirms the fact that these indicators are not informative for assessing the aggressive behavior of adenoma.

Comment [GG38]: "workup"

3. Invasion of the 3rd degree was the most ~~frequent~~ among all patients, which ~~should be considered~~ the equivalent of aggression.

Comment [GG39]: "frequent finding"

Comment [GG40]: "could be considered as.."

4. ~~Visualization predictive of adenomas by MRI~~ showed that tumor heterogeneity, chiasm compression, hypo- and iso-intensity in T1 mode and hyperintensity in T2 modes ~~are~~ the most significant ~~in~~ assessing the aggressive behavior of pituitary adenoma.

Comment [GG41]: "The MRI visualisation of the adenomas"

Comment [GG42]: "were"

Comment [GG43]: "predictive features"

COMPETING INTERESTS DISCLAIMER:

Authors have declared that no competing interests exist. The products used for this research are commonly and predominantly use products in our area of research and country. There is absolutely no conflict of interest between the authors and producers of the products because we do not intend to use these products as an avenue for any litigation but for the advancement of knowledge. Also, the research was not funded by the producing company rather it was funded by personal efforts of the authors.

References

1. Bette S, Butenschön VM, Wiestler B, von Werder A, Schmid RM, Lehmberg J, Zimmer C, Meyer B, Kirschke JS, Gempt J. MRI criteria of subtypes of adenomas and epithelial cysts of the pituitary gland. Neurosurg Rev. 2020 Feb;43(1):265-272.

2. Bonneville JF, Potorac J, Beckers A. Neuroimaging of aggressive pituitary tumors. Rev EndocrMetabDisord. 2020 Jun;21(2):235-242.

3. Conficoni A, Feraco P, Mazzatenta D, Zoli M, Asioli S, Zenesini C, Fabbri VP, Cellerini M, Bacci A. Biomarkers of pituitary macroadenomas aggressive behaviour: a conventional MRI and DWI 3T study. *Br J Radiol.* 2020 Sep 1;93(1113):20200321.

4. Cottier JP, Destrieux C, Vinikoff-Sonier C, Jan M, Herbreteau D. Etude IRM de l'invasion des sinus caverneux par les adénomeshypophysaires [MRI diagnosis of cavernous sinus invasion by pituitary adenomas]. *Ann Endocrinol (Paris).* 2000 Sep;61(3):269-74. French. PMID: 10970953.

5. Hornyak M, Couldwell WT. Multimodality treatment for invasive pituitary adenomas. *Postgrad Med.* 2009 Mar;121(2):168-76.

6. Knosp E, Steiner E, Kitzi K, Matula C. Pituitary adenomas with invasion of the cavernous sinus space: a magnetic resonance imaging classification compared with surgical findings. *Neurosurgery.* 1993 Oct;33(4):610-7; discussion 617-8.

7. Mete O, Lopes MB. Overview of the 2017 WHO Classification of Pituitary Tumors. *Endocr Pathol.* 2017 Sep;28(3):228-243.

8. Micko A, Oberndorfer J, Weninger WJ, Vila G, Höftberger R, Wolfsberger S, Knosp E. Challenging Knosp high-grade pituitary adenomas. *J Neurosurg.* 2019 May 31;132(6):1739-1746.

9. Sav A, Rotondo F, Syro LV, Di Ieva A, Cusimano MD, Kovacs K. Invasive, atypical and aggressive pituitary adenomas and carcinomas. *Endocrinol Metab Clin North Am.* 2015 Mar;44(1):99-104.

10. Sol B, de Filette JMK, Awada G, Raeymaeckers S, Aspeslagh S, Andreescu CE, Neyns B, Velkeniers B. Immune checkpoint inhibitor therapy for ACTH-secreting pituitary carcinoma: a new emerging treatment? *Eur J Endocrinol.* 2021 Jan;184(1):K1-K5.

11. Xu K, Yuan Y, Zhou J, Yu J. Pituitary adenoma apoplexy caused by rupture of an anterior communicating artery aneurysm: case report and literature review. *World J Surg Oncol.* 2015 Jul 30;13:228.