

## Case report

### LONG COVID Syndrome presenting as Hyperferritenemia associated Toxic encephalopathy in a Deferoxamine compliant patient of Beta Thalassemia

#### Abstract:

Ferritin overload is a frequent problem encountered in patients with beta thalassemia amounting to various complications. One of rare but important complication of ferritin overload is ferritin overload induced toxic encephalopathy. Serum ferritin has been recognised as a important marker of inflammation and cytokine storm in COVID19. We present a case of LONG COVID syndrome presenting as toxic encephalopathy in a case of beta thalassemia in spite of the patient being compliant to desferroxaminetherapy. This report highlights the synergistic effect of Severe Acute Respiratory Syndrome Coronavirus. 2(SARS CoV 2) mediated neuroinflammation along with hyperferritenemia resulting in toxic encephalopathy in a beta thalassemia major patient who was already prone to develop hyperferritenemia. It is important to recognise and treat this condition in order to prevent mortality and morbidity in patients of beta thalassemia who contract COVID19

**Keywords:** Beta-thalassemia, Long COVID, Encephalopathy

#### Introduction :

Since 2019, health care professionals around the world are battling an enormous pandemic of COVID19. In the present uncertainty of treatment of COVID along with absence of proper research there has been a major drawback in identifying unexpected manifestations of COVID19. Amongst the general population, patient with comorbidities are at higher risk of contracting COVID19 and developing complications (Jain et al., 2020). Increased inflammation in COVID19 has led to serious complications ranging from neuroinflammation to increased vascular inflammation (Talwar et al., 2021). Serum ferritin is an important marker of inflammation being used to identify and treat the cytokine storm of COVID19. Increased serum ferritin is also associated with iron overload in beta thalassemia due to increased blood transfusions received by the patients. With increase in intoxications of toxins by industrial, iatrogenic, industrial and environmental pollution there is increase in harmful effects caused due to toxins such as prooncogenic, teratogenic, neurological and psychiatric complications. In the Beta Thalassemia disorder the production of beta globin chains of haemoglobin are defective which results in erythropoiesis which is ineffective along with microcytic type of anemia. The clinical phenotype varies and therefore the clinical care which is required is different. Most severe form of the disease may require regular red blood cell transfusions starting from the first year of life whereas the less severe form of this disease may only require occasional blood transfusions when the need of red blood cell increases such as during growth or pregnancy and during infections. While chronic anemia has attained a good level of control but multisystem involvement due to iron overload continues to be a problem worldwide while treating all phenotypes of thalassemia patients. This iron overload is as a result of blood transfusion as well as ineffective erythropoiesis along with increased gastrointestinal absorption of iron (approximately three to four times than of a normal individual). Each unit of red blood cell transfused contains about 200-250 mg of iron which challenges the capability of the body to excrete the increased amount of

Comment [PS1]: Spacing

Comment [PS2]: Spacing

Comment [PS3]: Please explain on synergistic effect

Comment [PS4]: Spelling error

Comment [PS5]: Spacing

Comment [PS6]: Spacing

Comment [PS7]: Spacing

Comment [PS8]: Spacing

Comment [PS9]: Spelling mistake

Comment [PS10]: Referencing required

iron leading to increased ferritin levels and multiorgan iron poisoning. Detection of iron overload before the manifestation of organ damage enables in tailoring a chelation therapy plan to prevent multi organ failure and to revert the early changes of iron toxicity. The monitoring of iron levels is therefore of utmost importance and it relies on serum ferritin levels, however it does not strictly depict the tissue iron overload in all the organ systems. A direct approximation of iron stores is only achievable through biopsy (eg biopsy of the liver) which is a invasive procedure and can not be done easily or repeatedly for all organ systems. Iron chelation therapy with desferrioxamine has proved to be a game changer in beta thalassemia patients enabling to control iron overload. However, we report a case of hyperferritinemia induced toxic encephalopathy seen as a complication of Long COVID Syndrome in a beta thalassemia patient who was compliant with deferoxamine therapy.

Comment [PS11]: Spacing

Comment [PS12]: Cannot

Comment [PS13]: Spacing

Comment [PS14]: Spacing

Comment [PS15]: Reference for the above mentioned paragraph

### CASE REPORT:

A 32 years old male patient presented with chief complaints of vomiting, nausea, decreased appetite and abdominal distension. Vomiting and decreased appetite was since 5 days and distension of abdomen was present since 7 days. Patient was a known case of beta thalassemia major and was on regular blood transfusion once a month since many years. He was also compliant with desferrioxamine therapy. Patient also had a history of covid-19 positive status in December 2020. Patient was a known case of diabetes mellitus since many years and was insulin for the same. Patient also went under splenectomy in 2010. On examination: General condition was poor, pulse : 64/min, blood pressure: 90/60 mmhg, raised jugular venous pressure, bilateral pedal oedema present, clubbing present, icterus present, pallor present. On systemic examination: Respiratory system: Bilateral crepitations were present in infra mammary region, however air entry was equal. Cardiovascular system: heart sounds normal, no abnormal sounds heard. Per abdomen: distended and soft, tender, with evidence of hepatomegaly. On central nervous system examination patient was drowsy with normal deep tendon reflexes and bilateral plantar were mute. A CT Scan of brain was done which was normal. HRCT Chest was also done which was also normal. Patient's cerebrospinal fluid was sent for study which was normal. Patient's serum ferritin level was 8200 and interleukin 6 as well as LDH were found to be raised. Patient was started on steroids, antibiotics along with desferrioxamine therapy. During the course of hospital stay patient's serum ferritin level reduced to 6000/dl however he remained in toxic encephalopathy. Patient's condition deteriorated further and he ultimately succumbed on day 16 of admission .

Comment [PS16]: Spacing

Comment [PS17]: Spacing

Comment [PS18]: Spelling mistake

Comment [PS19]: Spelling mistake

Comment [PS20]: 64/min

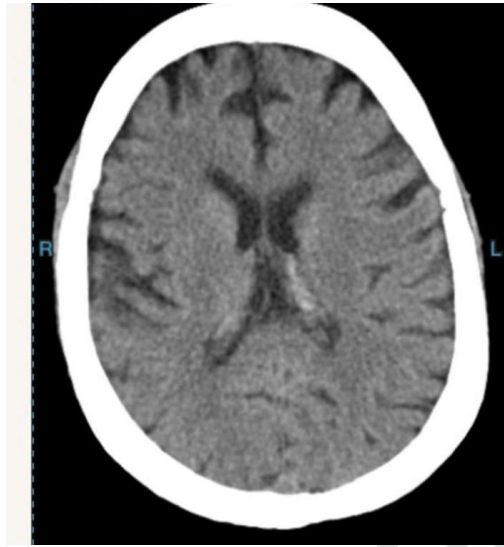
Comment [PS21]: 90/60

Comment [PS22]:

Comment [PS23]:

Comment [PS24]: Space

Comment [PS25]: Space



**Figure 1:** Showing CT Scan of the case with no obvious abnormality

CBC	Hb-8.4gm/dl MCV-78 fl Platelet count-90000/dl WBC Count-7900/dl
LFT	Total Protein-5.4gm/dl, Albumin2.7gm/dl, Globulin2.7gm/dl, aspartate aminotransferase 50 units/l , alanine aminotransferase 44 units/l, AlkanlinePhophatase99IU/l, Total Bilirubin :3.3mg
KFT	Creatinine:1.6mg/dl,  Urea 58mg/dl,  Sodium 139 mmol/l,  Potassium -4.6mmol/l
CRP	79.7mg/dl
D-Dimer	1.29
Serum Ferritin	8200ng/ml

Serum LDH	400 U/L
Interleukin 6	271pg/ml

**Table 1:** Showing lab investigations of the case

**Comment [PS26]:** Rephrase the Table Title

## Discussion

Involvement of the nervous system in beta thalassemia has emerged as a evident problem in beta thalassemia patients with the increase in life expectancy with blood transfusion and chelation therapy. Cognition is a major concern with regards to several cognitive fields to be compromised in beta thalassmiapatiens. Lower cognitive performances in beta thalassemia patients is attributed to disease related chronic ischemia, side effects of the treatment and increased number of hospitalisations starting from the initial years of life. Brain iron overload has been postulated to be a cause of potential brain injury and neurotoxicity in Beta thalassmiapatiens. Previous studies on MRI have supported this postulate with detection of iron overload areas in cortical and subcortical brain structures with a possible role in neurocognition .The lack of evidence of neural tissue iron overload seems to be the drawback in establishing a conncection of brain iron overload with cognitive impairment(Giri et al.,2021). Choroid plexus iron overload seems to be another possibility of neurodegeneration in beta thalassemia. Production of free radicals in the cerebrospinal fluid or in the neuronal tissues responsible for cognition can be a potential mechanism of neuronal impairment in beta thalassemia but it needs further studies for verification and lack of association between the levels of iron and cognitive impairment makes this possibility less likely. Iron chelation therapy form the mainstay of treatment of hyperferritenemia in beta thalassemia. It is interesting to note that our patient was compliant with iron chelation therapy and his serum ferritin levels still rose to dangerous levels causing toxic encephalopathy. Another cause of this encephalopathy being precipitated in our patient might be the synergistic effect of neuroinflammation by severe acute respiratory syndrome coronavirus 2 (SARS CoV 2). There are Angiotensin Convertase Enzyme 2 receptors present on the neurons and the SARS CoV2 binds to these receptors to mediate their action while effecting the expression of ACE 2 receptor(Gomez et al.,2020).(Figure 2).

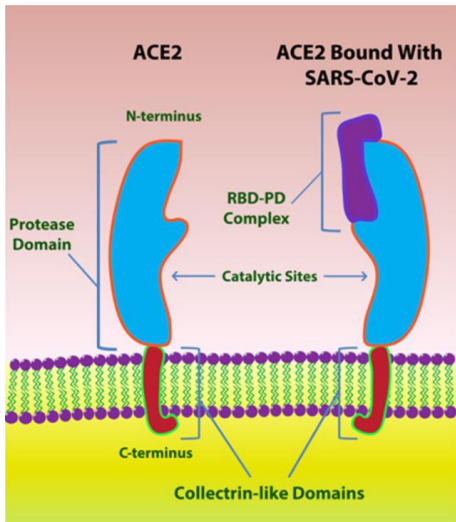
**Comment [PS27]:** Space

**Comment [PS28]:** Spelling

**Comment [PS29]:** Spelling

**Comment [PS30]:** Spelling

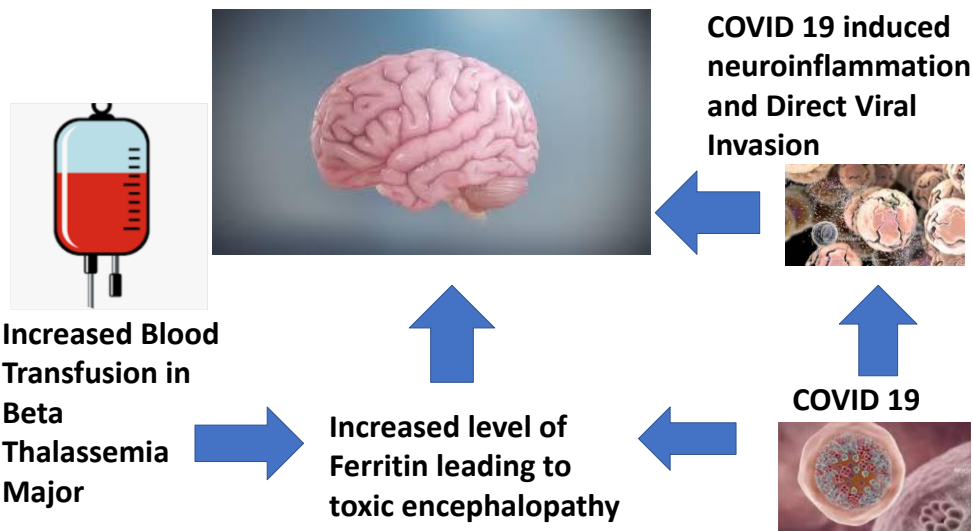
**Comment [PS31]:** Spelling



**Figure 2:** Showing SARS CoV 2 Binding to the ACE 2 Receptor present on the neurons

The virus can also cause neuroinflammation in view of profound inflammation during cytokine storm and in case of persistent inflammation in long COVID syndrome leading to increased ferritin levels (Perricone et al., 2020). Our patient had raised inflammatory markers along with raised ferritin levels and he was compliant with iron chelation therapy. Therefore in the above scenario the synergistic effect of neuroinflammation due to SARS CoV2 along with hyperferritinemia due to persistent inflammation as a result of LONG COVID syndrome were the likely cause for our patient to develop toxic encephalopathy (Figure 3). We postulate that iron dysmetabolism along with inflammation caused as a sequelae of Long COVID syndrome ultimately lead to development of toxic encephalopathy in a pre-disposed beta thalassemia major patient.

**Comment [PS32]:** Theoretical application could strengthen



**Figure 3:** Showing pathophysiology of Toxic Encephalopathy in our patient

### Conclusion

Hence we conclude that hyperferritinemia which is otherwise an marker of inflammation in COVID19 may have serious implications in patients with beta thalassemia who contract COVID19. Therefore the treating clinicians should be aware of such life threatening complications such as toxic encephalopathy which can even be expected to present in a case of chelation compliant beta thalassemia patient.

**Comment [PS33]:** Please explain the synergistic effect mentioned in the abstract in the conclusion

### References:-

1. Jain A, Talwar D, Kumar S. Spectrum of Respiratory Involvement in COVID 19 Era; An Overview. *Indian J of Forensic Med & Toxicol*, 14(4), 6593-6599.
2. Talwar D, Kumar S, Acharya S, Khan S, Verma P. Acute suicidal psychotic illness in mentally healthy patient: Is it COVID19?. *Medical Science*, 2021, 25(112), 1277-1280
3. Giri A, Dronamraju S, Acharya S, et al. Covid-19 infection in a case of transfusion dependent beta thalassemia major - a case report and review of literature. *J Evolution Med Dent Sci* 2021;10(18):1365-1368
4. Gómez-Pastora J, Weigand M, Kim J, et al. Hyperferritinemia in critically ill COVID-19 patients - Is ferritin the product of inflammation or a pathogenic mediator?. *Clin Chim Acta*. 2020;509:249-251. doi:10.1016/j.cca.2020.06.033
5. Perricone, C., Bartoloni, E., Bursi, R. et al. COVID-19 as part of the hyperferritinemic syndromes: the role of iron depletion therapy. *Immunol Res* 2020, **68**, 213–224.

**Comment [PS34]:** Please follow the same referencing format

UNDER PEE