

## Case study

### **PHYSIOTHERAPY REHABILITATION IN POST OPERATIVE TIBIA- FIBULA FRACTURE WITH EXTERNAL FIXATORS.**

#### **Abstract**

**Introduction-** A tibia - fibula fracture occurs when a fall or trauma to the lower extremities puts more tension on the bones than they can tolerate. Diaphyseal tibial fractures are the most common long bone fracture. Lower extremity Tibia and fibula fractures are examples of fractures. Tibial shaft fractures are most typically associated with a history of severe trauma. The tibia is the most commonly fractured bone in the lower extremity. The bone's shaft is in the middle Fibula fractures are usually, but not always, accompanied by tibial shaft fractures.

**Case presentation-**At the previous 15 days, a 49-year-old male patient accounted in a hospital with a road traffic accident.

**Conclusion-**Physiotherapy has a significant effect on pain, strength, and range of motion. The result of this case report specifies that it may be effective for pain relief, improvement in strength, and functional ability.

**Discussion-**The physiotherapy was given to this patient for muscle energy technique resulting in a high degree of range of motion in the lower extremity, reduce pain, and improves flexibility and strength

#### **Keywords: -**

Physical therapy, Rehabilitation, Tibia-fibula fracture, External fixator.

## Introduction

The patellofemoral joint, tibiofemoral joint, and tibiofibular joint are the three joints of the knee the two bones that articulates with each other are referred to as joints. Whenever we think of the knee, we think of the tibiofemoral joint.<sup>1</sup>The treatment goal of the tibial fracture is to achieve the correct limb length, alignment and restoration of normal knee mechanics.<sup>2</sup> At the knee joint, there are slight number of movements. Ligaments are present over which are the connective tissue bundles that connect one bone to another. The knee joint is stabilised by the four major ligaments.<sup>3</sup> The inside and outside of the knee have collateral ligaments. The cruciate ligaments are which in the centre of the knee to provide support, are the two largest ligaments.<sup>4</sup>

Tibia is the second large and long bone of the lower extremity. Tibial plateau The severity of a fracture can range from a stable non-displaced fracture with minor soft tissue injury to highly communicated unstable fractures with significant soft cell damage soft tissue injury that threatens the viability of the limbs .<sup>5</sup> Proximal tibia consists of the tibial plateau which includes the intercondylar eminence and the medial and lateral epicondyles.<sup>6</sup>The medial condyle is larger than the lateral condyle and is of two tibial condyles. The smaller lateral condyle is the most and commonly fractured.<sup>5</sup> Tibial shaft fracture is the break in the middle part of the tibia bone. Open fractures generally occur from high velocity trauma. Fibular fractures in adults are often caused by trauma. Mechanism of injury for tibia fibula fracture are split into two groups in which low energy injuries includes such as ground level falls and athlete injuries and high energy injuries includes such as motor vehicle injuries. With a tibial fracture, the patient may indicate a record of direct or indirect trauma, as well as pain, oedema, and disability to walk.

With the external fixators, it is a primary and effective treatment for tibia shaft fracture with complications .<sup>7</sup> With the advantages of the external fixation technology, it is the ultimate

treatment for tibia fibula fracture and are also applied for treatment of close fracture which achieve good therapeutic effects .<sup>8</sup> all the patient who achieved fracture healing and has no complications were seen including fixation failure, infection over implants and limitation of joint movements .<sup>9,10</sup>

This case report describes a tibial and fibula fracture following road traffic accident in a 49-year-old male patient who was under went surgical treatment and subsequently treated under physiotherapy rehabilitation department at academic hospital in **Sawagi Meghe** with proper rehabilitation protocol.

### **Case presentation**

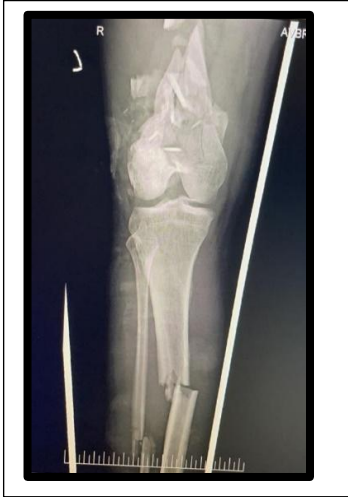A 49-year male patient who is teacher by the occupation with right hand dominance with the complaints of pain, swelling and inability to perform active movements.

The patient presented with the history of road traffic accident from his bike 15 days back, following which then he had fracture of tibia and fibula. Patient was taken by the relatives to **GMC yavatmal** where initial bandaging was done and some medications were given for pain. Then he was referred to the **AVBRH hospital** with the same complaints. After that, in AVBRH hospital, the patients CT-SCAN and MRI was done and here he was diagnosed with right sided mid shaft tibia and fibula fracture.

For the above-mentioned complaints, patient was operated on 26/09/2021 with the external fixation surgery of right knee in lower extremity.

### **Clinical finding**

A proper informed consent was taken from the patient prior. Physical examination was done, he was examined in supine position. On physical examination, vital signs including temperature was normal, 76 beats per minute pulse, 21 breaths per minute respiratory rate and blood pressure was 120/80mmHg. On inspection, patient's right leg was affected in the road traffic accident. On observation, patient keeps his right leg adducted, hip and knee extended and foot in planter flexion slightly. Presence of scar was over posterior aspect of the knee joint. Due to injury, deep tendon reflexes were found to be intact.



graphs are show

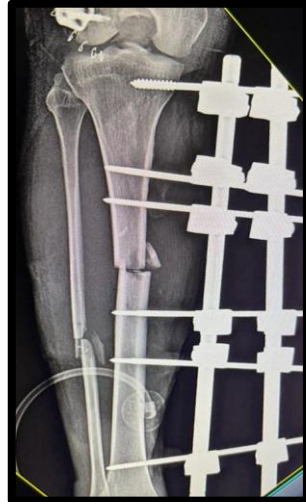


Figure 1

Figure 2

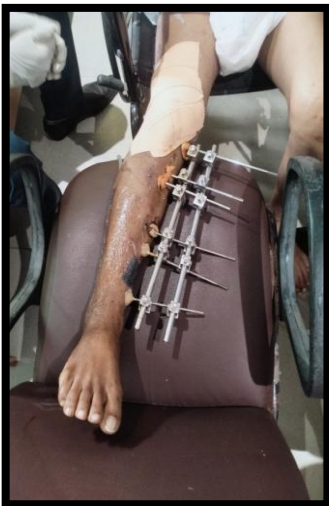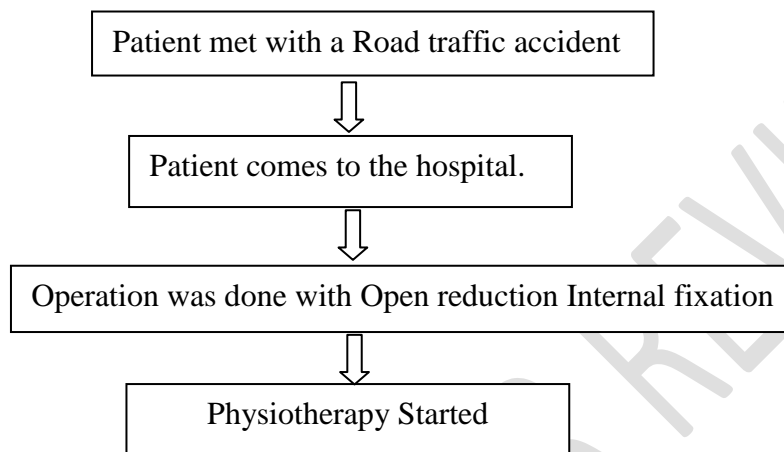


Figure 3

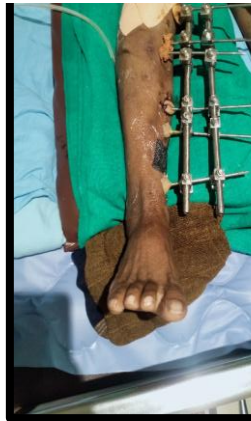

Figure 4

**Timeline: -**



**Therapeutic interventions**

The patient attended physiotherapy sessions six days a week for a period of 12 weeks. Patient education, Pursed lip Breathing, Incentive Spirometry, range of motion exercises, and progressive resistance exercises were all part of session.

**Goals:**

1. Reduce pain.
2. Enhance flexibility.
3. Improve range of motion.

4. Improve Breathing.
5. Improves strength.

## **Management**

### **Week 1: -**

Manual: - Soft tissue mobilisation and gentle range of motion are used to treat the underlying tissues.

Exercise: - Quadriceps recruitment can be improved by gait preparation, pain and edema management, and muscle relaxation. Ankle pump, quad and adduction sets, leg raises in various planes (except hip extension), and moderate isometric resisted knee extension are some of the exercises you can perform (between 0-60 degrees).

Repetition - 10, Sets – 1.

### **Week 2-4: -**

Manual: - Soft tissue mobilisation, patellar glides, and range of motion exercises are all recommended.

Exercise: - 1) As you are willing, increase your weight-bearing capacity and functional mobility. 2) Stretching with passive flexion and extension. 3) Prone hip extension exercises are done with the knees fully extended. 4) Multiple ranges of submaximal quad, knee extension, and adduction isometrics. 5) Squats/knee bends in the short range (0-60 degrees), calf exercises, and standing hip exercises.

Repetition – 10, Sets – 2.

### **Week 4-6: -**

Manual: - Soft tissue, joint mobilizations, and patellar glides should continue.

Repetition – 10, Sets – 3.

### Initial examination findings

Table 1. ROM assessment on 1<sup>st</sup> day of physiotherapy treatment.

| Joint                 | Right             |                   | Left   |         |
|-----------------------|-------------------|-------------------|--------|---------|
|                       | Active            | Passive           | Active | Passive |
| Hip flexion           | Unable to perform | 0-30              | 0-110  | 0-117   |
| Extension             | Unable to perform | 0-10              | 0-15   | 0-18    |
| Abduction             | 0-10              | 0-30              | 0-40   | 0-48    |
| Adduction             | 10-0              | 0-15              | 0-26   | 0-30    |
| Knee flexion          | Unable to perform | 0-25              | 0-135  | 0-135   |
| Extension             | Unable to perform | 25-0              | 135-0  | 135-0   |
| Flexion (BSS)         | Unable to perform | Unable to perform | 130    | 135     |
| Extension (BSS)       | Unable to perform | Unable to perform | 130-0  | 135-0   |
| Ankle planter flexion | 0-40              | 0-50              | 0-50   | 0-50    |
| Dorsiflexion          | 0-5               | 0-10              | 0-10   | 0-10    |

### Follow up and outcomes

Post rehabilitation patient showed remarkable improvement.

Table 2. Range of motion pre and post rehabilitation.

| Joint                 | Pre-rehab         |                   | Post-rehab |         |
|-----------------------|-------------------|-------------------|------------|---------|
|                       | Active            | Passive           | Active     | Passive |
| Hip flexion           | Unable to perform | 0-30              | 0-80       | 0-90    |
| Extension             | Unable to perform | 0-10              | 0-15       | 0-18    |
| Abduction             | 0-10              | 0-30              | 0-40       | 0-45    |
| Adduction             | 10-0              | 0-15              | 0-25       | 0-26    |
| Knee flexion          | Unable to perform | 0-25              | 0-45       | 0-60    |
| Extension             | Unable to perform | 25-0              | 45-0       | 60-0    |
| Flexion               | Unable to perform | Unable to perform | 90         | 100     |
| Extension             | Unable to perform | Unable to perform | 90-0       | 100-0   |
| Ankle planter flexion | 0-40              | 0-50              | 0-50       | 0-50    |
| dorsiflexion          | 0-5               | 0-10              | 0-10       | 0-10    |

## Discussion

Tibial fractures are harder to manage because they are accompanied with soft tissue injuries, communication issues, and complexity, which is often the consequence of high-energy trauma. It further complicates the administration of such complicated fractures.<sup>11</sup> Early passive mobilization has shown to be more effective in the greater improvement in the knee flexion range of motion during rehabilitation and lowered risk of the deep venous thrombosis.<sup>12</sup> The different approaches such as the progressive range of motion exercises, soft tissue mobilization, isometric exercises, open and close chain muscle strengthening exercises,

stretching, gait training these are the exercises which are found to be more effective in the recovery of the tibia and the fibula fractures.<sup>13</sup> The study conducted by Gabriel is found that physiotherapy intervention has the positive impact to gain more confidence, it improves gait in the post-operative physiotherapy.<sup>14</sup> Various proprioception and stabilization exercises in the later phase were initiated to improve the proprioception and the weight transfer. Involvement of the proprioception exercises in the rehabilitation of the patients under knee injuries and knee surgeries is the vital aspect in the rehabilitation.<sup>15</sup> This case report's purpose was to focus on the significance of the prompt surgical treatment and the essential physiotherapy rehabilitation to attain the functional goals with the respect to the patient and its prognosis.

## **Conclusion**

According to the findings, a conclusive surgical approach and early physiotherapy rehabilitation contribute to an improvement in the patient's functional objectives, which is a critical understanding for an effective recovery. Physiotherapy has a significant effect in pain reduction, strength and range of motion. It improves the functional ability.

**Home Program-** Active Range of motion Exercises, Static Quadriceps, Ankle toe Movements, Bilateral Upper Limb Strengthening with 1kg weight, Pursed lip breathing, incentive spirometry was educated to patient and patients Care taker.

## **Patient consent**

Permission was taken from the patient for including the data in case report.

## **References-**

1. A case report on Physiotherapy rehabilitation accelerating the recovery of older patient with anterior cruciate ligament reconstruction.  
[http://www.discoveryjournals.org/medicalscience/current\\_issue/v24/n103/A109.htm](http://www.discoveryjournals.org/medicalscience/current_issue/v24/n103/A109.htm).

2. Thabet, A., Khalifa, R., Alnajjar, R. & Abdelgawad, A. Excessive Tibial Overgrowth Associated Ankle Valgus Deformity After Pediatric Open Mid-Shaft Tibial Fracture: A Case Report. *West. J. Orthop.* **10**, (2021).
3. Revision PCL Reconstruction Review/Update - PubMed.  
<https://pubmed.ncbi.nlm.nih.gov/29679208/>.
4. A case study on the impact of physiotherapy on unilateral foot drop after lumbar fusion and discectomy.  
[http://www.discoveryjournals.org/medicalscience/current\\_issue/v24/n103/A105.htm](http://www.discoveryjournals.org/medicalscience/current_issue/v24/n103/A105.htm).
5. Early physical rehabilitation post-surgery in a complex type 5 Schatzker Tibial plateau fracture improves functional outcomes: A case report.  
[http://www.discoveryjournals.org/medicalscience/current\\_issue/v24/n104/A119.htm](http://www.discoveryjournals.org/medicalscience/current_issue/v24/n104/A119.htm).
6. Kfuri, M. & Schatzker, J. Revisiting the Schatzker classification of tibial plateau fractures. *Injury* **49**, 2252–2263 (2018).
7. Pediatric Tibial Shaft Fractures.  
<https://www.ncbi.nlm.nih.gov/pmc/articles/PMC6142797/>.
8. External fixation for primary and definitive management of open long bone fractures: the Syrian war experience - PubMed. <https://pubmed.ncbi.nlm.nih.gov/30905046/>.
9. Management of Pediatric Tibial Shaft Fractures - PubMed.  
<https://pubmed.ncbi.nlm.nih.gov/30998564/>.
10. Palmu, S. A. *et al.* Tibial fractures in children. A retrospective 27-year follow-up study. *Acta Orthop.* **85**, 513–517 (2014).
11. Necessity of dual plating in bicondylar tibial plateau fracture dislocations: A prospective case series Bhalotia AP, Ingle MV, Koichade MR - J Orthop Traumatol Rehabil.  
<https://www.jotr.in/article.asp?issn=0975-7341;year=2018;volume=10;issue=1;spage=29;epage=33;aulast=Bhalotia>.
12. (11) (PDF) Immediate Knee Joint Range of Motion after Stable Fixation of Tibial Plateau Fractures.  
[https://www.researchgate.net/publication/282203798\\_Immediate\\_Knee\\_Joint\\_Range\\_of\\_Motion\\_after\\_Stable\\_Fixation\\_of\\_Tibial\\_Plateau\\_Fractures](https://www.researchgate.net/publication/282203798_Immediate_Knee_Joint_Range_of_Motion_after_Stable_Fixation_of_Tibial_Plateau_Fractures).

13. Linehan, R. F. Outpatient physical therapy for a patient following open reduction internal fixation due to bicondylar tibial plateau fracture. (2018).
14. Bonifacio, G. M. DOCTOR OF PHYSICAL THERAPY. 42.
15. Tibial Plateau Fracture Following Low Energy Fall in the Rocky Mountains.  
<https://www.ncbi.nlm.nih.gov/pmc/articles/PMC6710023/>.

UNDER PEER REVIEW