

# A case report of *ChAdOx1 nCoV- 19 corona virus recombinant vaccine* related granuloma annulare

Short title: A CASE REPORT OF COVID-19 VACCINE RELATED GRANULOMA ANNULARE

## ABSTRACT:

### Background :

Granuloma annulare (GA) is a benign, self-limiting inflammatory skin condition of unknown origin that may occur following multiple etiological triggers. GA incited secondary to vaccinations have been less reported in medical literature. The COVID-19 pandemic has introduced extensive global immunisation against the SARS-COV-2 virus, which also bring along a gamut of vaccine-related complications. We elucidate a case report of spontaneous eventuality of granuloma annulare following *ChAdOx1 nCoV-19 Corona Virus Recombinant Vaccine*.

### Case report:

A healthy 28 year male presented with a one week history of asymptomatic single, flesh-pink patch with raised margin over his left ventral forearm. On close examination, the margin of the lesion had multiple annularly arranged papules. Biopsy of lesion was done and histopathology revealed numerous palisading granulomas in the dermis consistent with findings of localised granuloma annulare. Patient was managed with high potent topical corticosteroids and lesion showed spontaneous resolution in one month despite improper use of the topical corticosteroid.

In abstract section the year old of human case report must same as in the case report

### Conclusion:

Identifying *ChAdOx1 nCoV- 19 Vaccine*-related adverse events following its first dose is paramount, as evidence on the proportion of local or systemic adverse skin reaction on subsequent dosing is a paucity. Larger systematic review corroborating common and serious adverse skinreaction and safety profile following immunisation with *ChAdOx1 nCoV-19 Vaccine* prevails to be the need of the hour.

---

### Introduction:

Granuloma annulare (GA) is a benign, idiopathic, self-limiting inflammatory skin condition commonly reported following trauma, insect bites, viral infections and malignancy. Few cases describe the spontaneous occurrence of granuloma annulare following vaccinations. With the ongoing extensive global immunisation programme against SARS-CoV-2 virus, hundreds of millions of vaccines doses have been administered. However, anecdotal reports on the cutaneous adverse reactions following COVID-19 immunisation form lacunae in their early diagnosis and active medical management. Here, we describe a case of GA-like eruption following *ChAdOx1 nCoV- 19 Corona Virus Recombinant Vaccine* in a young indian male who has no medical history nor allergies.

Case report:

A 26 year old male, otherwise healthy software professional, presented with a 1 week history of a single lesion over his left forearm. His skin lesion were neither itchy or painful. He has no personal or family history of skin concerns. His recent medical history includes first dose of COVID-19 immunisation 10 days ago. Prior to immunisation, he had no symptoms suggestive of COVID-19 disease. Physical examination revealed a solitary well-demarcated, annular, erythematous plaque with raised margins over the ventral aspect of his left forearm. On closer inspection, the lesions margin had multiple, flesh-pink pinhead papule's, with a regressing pattern towards the centre. The patient shared a photographed image of the same lesion taken at day 1 of its appearance, showing a smaller, flesh-pink patch with raised and irregular margin with central hyperpigmentation. A 4mm punch biopsy from the lesion revealed discrete areas of well-circumscribed central necrobiotic collagen surrounded by a palisade of histiocytes, multinucleate giant cells and peri-vascular lymphocytes in the mid-dermis consistent with necrobiotic palisading granulomas. The patient diagnosed with localised GA following COVID-19 immunisation with *ChAdOx1 nCoV-19 Corona Virus recombinant vaccine*. Patient was reassured about the benign nature of the lesion and was initiated with topical mometasone furoate cream with follow-up after 10 days; Patient came for review after one month, with history of discontinuation of treatment within 10 days and partial improvement of lesions which eventually resolved spontaneously at 1 month from its first appearance.

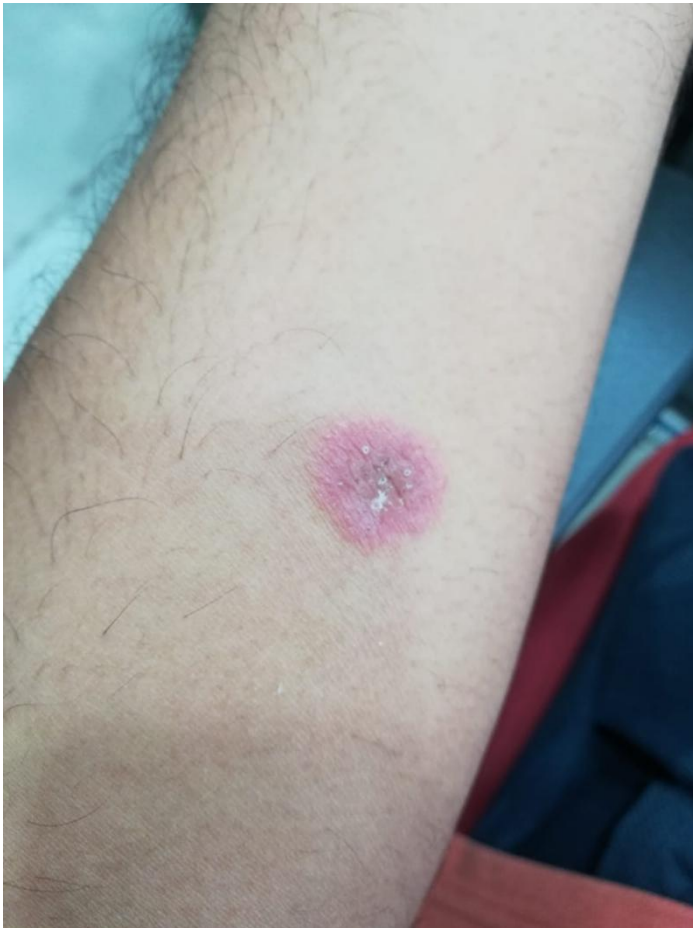

image (i) lesion seen on day 1 of appearance ;

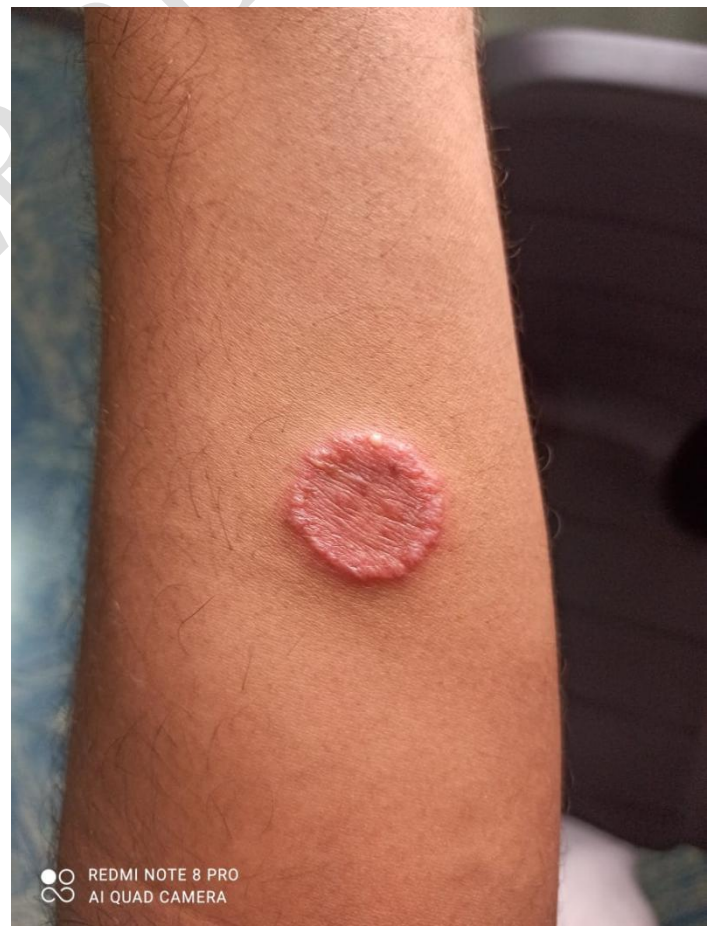

image (ii) lesion as seen after 1 week

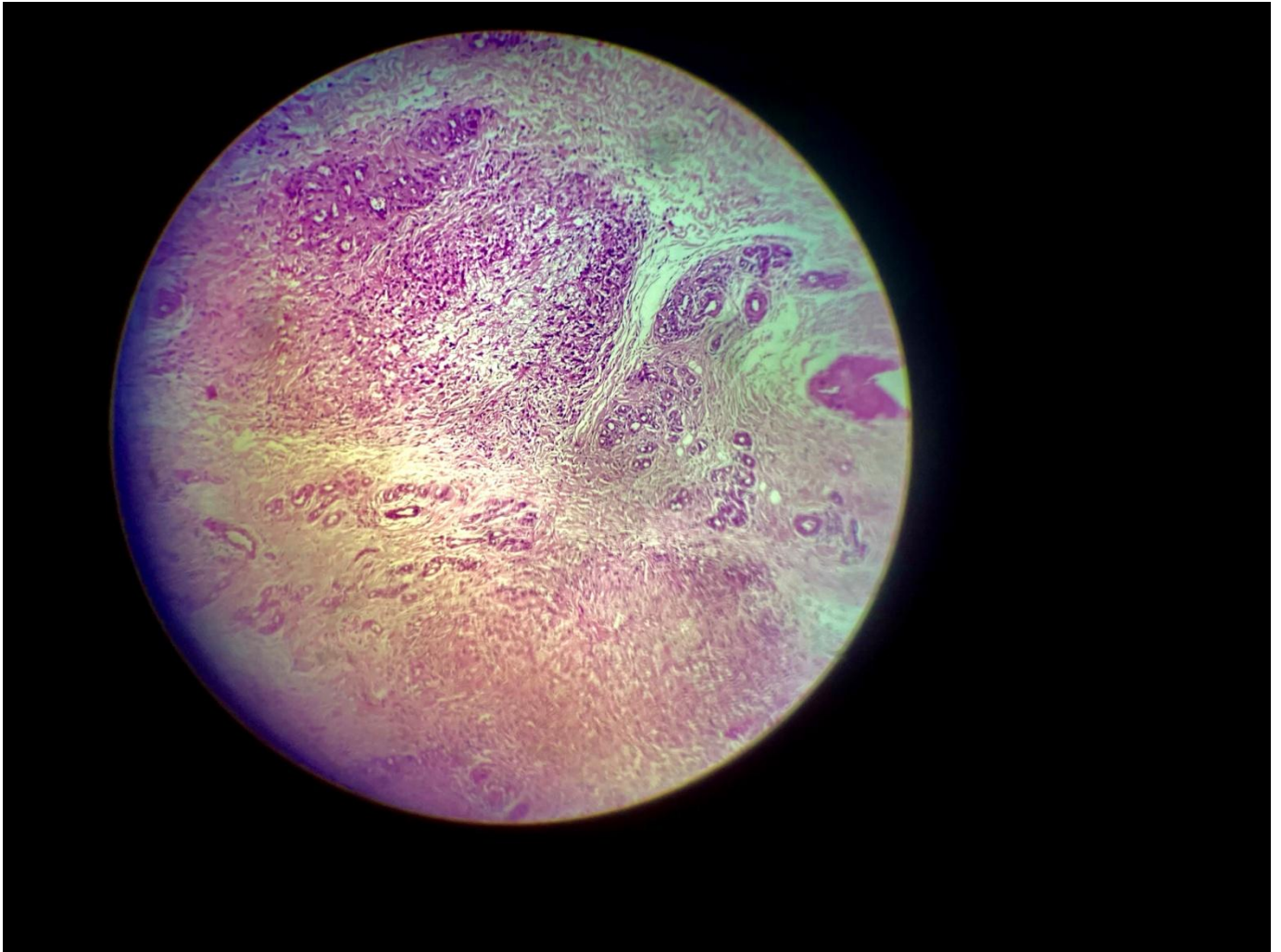


Image iii: Histopathology of the lesion shows distinctive palisading granulomas in the mid-dermis consistent with granuloma annulare .

#### Discussion:

Granuloma annulare is an idiopathic granulomatous dermatosis that commonly presents as asymptomatic, self-limiting papular eruption. With a higher incidence in children and young adults, GA is seen approximately twice as commonly in females than males. The lesions are usually found over the arms, legs, hands and feet but may rarely present over the palms, penis, ears and periocular area. The morphology of the lesions are in accordance to the clinical subtypes, namely, generalised, localised, linear, perforating and subcutaneous .

Generalised GA seen in upto 15% cases, are described by the presence of 10 or more lesions or widespread plaques. Cases reported with hundreds of discrete or confluent papules are not uncommon. Lesions of localised GA are common over the dorsum of the hands or feet arranged in an distinctive annular configuration showing large, slightly erythematous patches with a palpable margins on which scattered papules may subsequently arise. Perforating GA seen in 5% cases of GA, show tender, umbilicated lesions in a localised distribution, rarely may be generalised. Rarest

clinical variant of GA, namely subcutaneous GA presents with subcutaneous nodules, seen especially in children having close clinical resemblance with rheumatoid nodules, although there is no history of arthritis and normal serology for rheumatoid factor, ANCA, ANA and anti-CCP antibody

**Need more references for comparison**

Pathogenesis of GA is based on alternating views of **immunoglobulin-mediated** vasculitis and **delayed-type** hypersensitivity response to an unknown antigen. The cell-mediated immune response appears to be marked with prominent activated helper T cells. The exact mechanism by which GA is triggered in our patient is unknown. Immunological activation following vaccination may explain the presence of activated T-cells in the lymphocytic infiltrate in the palisading granulomas. There is a lesser possibility of traumatic inoculation hypothesis, as the site of granuloma formation is distant and hence less convincing.

**Should be double check the writing**

Histopathology of GA is characteristic of necrobiosis and granuloma formation along with abundant mucin deposition involving the dermis and subcutis. The term 'necrobiosis' is used to describe the death of tissue and its simultaneous but inadequate replacement by viable tissue. Three distinctive histological patterns are observed in GA, namely infiltrative (interstitial) pattern, palisading granuloma pattern and an epithelioid nodule (sarcoidal granuloma) pattern are known. GA shows characteristic palisading granuloma, a pattern exemplified by stacked epithelioid histiocytes aligned around a central focus of mucin. In some instances, histiocytes that are seen as a foci within the dermis, can be distributed interstitially as strands, cords, or columns in other foci, i.e., between bundles of collagen. Synthesis of types I and III collagen also occur as a reparative response. Necrobiosis lipidica is a common differential diagnosis of GA shows pan-dermal inflammation, linear arrays of histiocytes surrounding necrobiotic collagen and abundant plasma cells. Presence of mucin and the absence of asteroid bodies or other giant cell inclusions also less favours sarcoidosis.

**Foot notification for references that were used must be showed in all of the section**

Conclusion:

A number of vaccines have been reported to trigger GA. Bacillus Calmette-Guérin (BCG) vaccine has been most frequently reported, followed by the hepatitis B vaccine, influenza vaccine, tetanus and diphtheria-tetanus toxoid vaccine and pneumococcal vaccine. GA after SARS-CoV-2 vaccination has not been previously described. Most cases GA following vaccination with any of the above have commonly occurred in young patients, probably because the frequency of vaccination was higher at a younger age as a part of routine immunisation. However, owing to the gravity of the COVID-19 pandemic situation, there is extensive immunisation among adults in all age groups. This expands opportunity of identifying various complications that occurs post-COVID-19 immunisation. Wide spectrum of vaccines formulations are in the conduit against COVID-19 disease are based upon inactivated or live attenuated viruses, protein sub-unit, virus-like particles (VLP), viral vector (replicating and non-replicating), DNA, RNA, nanoparticles, etc. with each exhibiting unique merits and demerits.

**In the section should be focused in the case report what the novelty the case report founding**

According to WHO: "vaccine must provide a highly favourable benefit-risk contour; with high efficacy, only mild or transient adverse effects and no serious ailments". The *ChAdOx1 nCoV-19* Vaccine used by our patient is recombinant vaccine based on viral vector technology scheduled as two doses injected intramuscularly at 0.5ml and the Indian government has recommended that the time interval between the 1st and 2nd dose should be between 12-16 weeks. The most common

adverse reactions to COVID-19 vaccinations are usually milder, transient and are much widely acceptable over time. Vaccine hesitancy and literacy pose major challenge despite the its increase acceptance among the masses. The general people should be aware of the minor side effects which are manageable with some symptomatic treatment which would certainly help to counter this pandemic disease through ongoing immunisation program successfully.

#### **COMPETING INTERESTS DISCLAIMER:**

Authors have declared that no competing interests exist. The products used for this research are commonly and predominantly use products in our area of research and country. There is absolutely no conflict of interest between the authors and producers of the products because we do not intend to use these products as an avenue for any litigation but for the advancement of knowledge. Also, the research was not funded by the producing company rather it was funded by personal efforts of the authors.

#### References:

1. Cheng Y, Tsai W, Chuang F, Chern E, Lee C, Sung C et al. A retrospective analysis of 44 patients with granuloma annulare during an 11-year period from a tertiary medical center in south Taiwan. *Dermatologica Sinica*. 2016;34(3):121-125.
2. García-Gil M, Álvarez-Salafranca M, MartonesGarciaa A, Ara-Martín M. Generalized granuloma annulare after pneumococcal vaccination. *Anais Brasileiros de Dermatologia*. 2021;96(1):59-63.
3. Akinosoglou K, Tzivaki I, Marangos M. Covid-19 vaccine and autoimmunity: Awakening the sleeping dragon. *Clinical Immunology*. 2021;226:108721.
4. Niebel D, Novak N, Wilhelmi J, Ziob J, Wilsmann-Theis D, Bieber T et al. Cutaneous Adverse Reactions to COVID-19 Vaccines: Insights from an Immuno-Dermatological Perspective. *Vaccines*. 2021;9(9):944.
5. [https://www.seruminstitute.com/product\\_covishield.php](https://www.seruminstitute.com/product_covishield.php)
6. Kaur S, Gupta V. COVID-19 Vaccine: A comprehensive status report. *Virus Research*. 2020;288:198114.

Need more references