

# **Epidemiological study of fingertip injuries in a tertiary care center in Kancheepuram district**

## **ABSTRACT**

### **Background and Aim:**

Although fingertip injuries are common, there is limited literature on its epidemiology. This study examines the clinical characteristics of fingertip injuries in adults treated at a tertiary medical hospital. The aim of the study is to investigate and examine the epidemiological variables impacting patients' fingertip injuries in a tertiary care hospital in Kancheepuram.

### **Methods:**

An epidemiological study of patients with fingertip injuries managed at a tertiary hospital in Kancheepuram over a period of twelve months (March 2020-March 2021). The patients' profile as well as the clinical presentation, management options and the outcome of care of the patients were documented and analyzed using descriptive statistics.

### **Results:**

Fifty one fingertips patients were managed. The median age was 23.50 years, with 88% of male. 36 [70%] injuries involved accidents in their workplace. A total of 34 [66%] injuries occurred in the fingers of the right hand. The management offered included PSS (Primary Skin Suturing), V-Y flap, RHAF, Nail bed repair and K wire fixation. About 91.5 % of the patients reported a satisfactory outcome.

### **Conclusion:**

In the workplace, right-handed males between the ages of 18 and 25 are more prone to have fingertip injuries. While proper diagnosis and adequate response are critical for a positive result in fingertip injuries, a safer environment and workplace would assist to alleviate the burden.

**Keywords:** Fingertip injuries, epidemiology, workplace, management and right hand

## INTRODUCTION

Fingertip injuries are one of the most frequent hand injuries seen in emergency departments (EDs). While large-scale epidemiological studies are scarce, the ones that have been performed suggest that the majority of fingertip injuries occur at work place, including injuries caused by equipment such as cutting machines, thresher machines, sugarcane grinders, printing presses, and so on.<sup>1</sup> Because it is the most distant portion of the hand, the fingertip is the most commonly afflicted. Road traffic accident [RTA] [~~Road traffic accident~~] is where the majority of fingertip injuries occur beyond the work place.<sup>2</sup> Infection, soft tissue loss, fracture and amputation are among possible consequences of fingertip injuries.<sup>3</sup> By protecting the fingertip, generating counterforce to aid with picking up tiny items, and contributing to the tactile feeling of the fingertip, the nail plays a vital part in the regular operation of the hand. The integrity of the nail plate and nail margin are used to manage nail bed injury.<sup>4</sup> Fingertip deformities, nail dystrophy, and discomfort are all long-term consequences. This study was carried out to learn more about the epidemiology of a fingertip injury group.<sup>5</sup> ~~This epidemiological study will, with an~~ attempt to relate the study to the larger, ongoing dialogue in the discussion of the epidemiology of fingertip injuries, filling the gaps and extending prior studies. Finally this article reviews how factors such as sex, age, occupation and hand dominance affect the frequency, severity of the fingertip injuries in the individuals of Kancheepuram district attending the tertiary care center

## METHODOLOGY

This retrospective epidemiological study involved 51 individuals with fingertip injuries who visited the Plastic Surgery Department at Saveetha Medical College & Hospital between March 2020 and March 2021, over a period of 1 year by various methods individualized based on patient's age and injury pattern. Individuals without fingertip injuries were excluded from the research, whereas those with one or more fingertip injuries were included. After getting informed written consent, a thorough history and clinical examination were performed at the time of booking. Every standard investigation of such traumatic injuries was carried out. .Age, sex,

dominant hand, hand and fingers affected, employment, and proposed treatment/ method are all factors addressed in the study.

### Statistical Analysis

MS Excel was used to enter the data, and SPSS version 22 was used to analyse the data. Graphical representation of data: MS Excel and MS word were used to obtain various types of graphs and tables.

### RESULTS:

The study involved 51 individuals who had fingertip injuries between March 2020 – March 2021 of which 4 were in the age group between 1-17 years, 24 within the age group of 18-25, 11 within the age group of 26-45 and 12 individuals above the age of 45. [Table: 1]

Age (in years)	Number (n = 51)
0-10	2
11-20	11
21-30	18
31-40	9
41-50	8
51-60	1
Above 60	2

**Table: 1 Age distribution of the study sample**

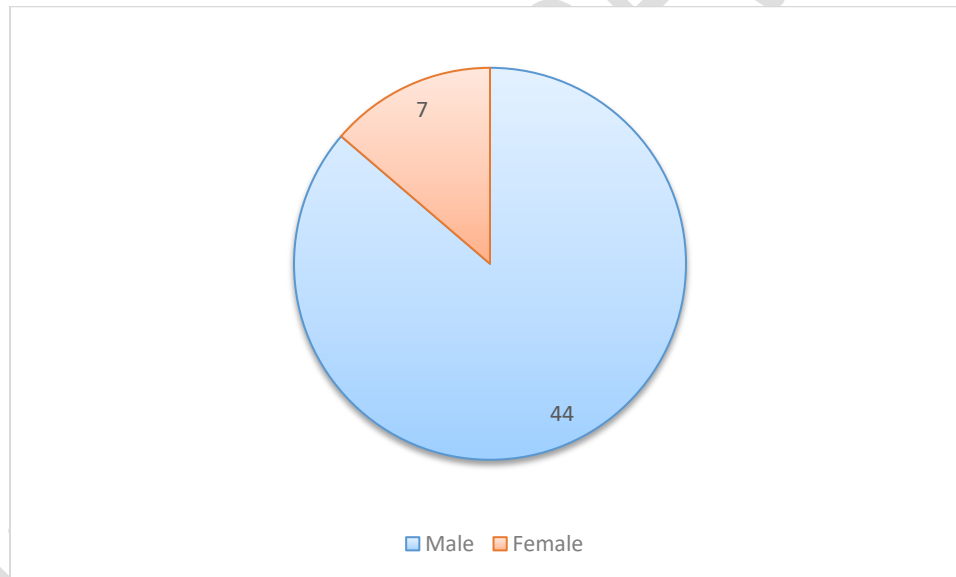
Of all the fingertip injuries 36 occurred in right hand dominant individuals and 15 in left hand dominant individuals. [Table: 2]

**Table: 2 Side of fingertip injury**

Dominant hand + Affected hand	Number of participants n = 51
Right + right	32
Right + left	6
Left + right	2
Left + left	11

Majority of the individuals in this study i.e. 88% were males and only 12% of the affected individuals were females. [Figure: 1]

**Figure: 1 Sex wise distribution**



71% of the fingertip injuries occurred at the workplace while only 29% occurred at home.

]]]

**Table: 3 Place of injury**

<b>Environment where injury occurred</b>	<b>Number of participants n = 51</b>
<b>Work/Work related</b>	<b>36</b>
<b>Home</b>	<b>15</b>

Out of all the participants majority of the individuals either underwent or were suggested to undergo PSS. [Table: 4]

**Table: 4 Suggested treatments**

<b>Treatment done/suggested</b>	<b>Number of participants n = 51</b>
<b>PSS</b>	<b>20</b>
<b>V-Y flap</b>	<b>11</b>
<b>RHAF</b>	<b>8</b>
<b>Nail bed repair</b>	<b>3</b>
<b>K-wire fixation</b>	<b>9</b>

## **DISCUSSION**

Despite many refinements in machines and advanced protective gears, fingertip injuries remain a common type of hand injury with a lot of morbidity and loss of manpower. Although the appearance is trivial, they can result in a considerable functional disability if not managed timely and properly. Inappropriate management can lead to significant loss of skilled hand function. The occupational, as well as social activities, are severely affected in patients with fingertip injuries because of their considerable morbidity.<sup>6</sup> Although fingertip injuries are common in adult populations with a large number of individuals working with heavy machinery or dangerous equipment, only a few studies have examined the demographic details and the treatment of such cases.<sup>7</sup> In our study, 71% of the injuries occurred at the work place while only 29% occurred at home. Most of the affected individuals are in the age group between 18-25. 88% of the individuals involved were male, this finding continues to support the mechanism of a majority of these injuries being work related. Similar results were found by Saraf S et al. and Karthi SV et al. in their respective studies on fingertip injuries.<sup>8,9</sup> However, Hongaiyah D et al. reported female

predominance (75%) in their study on fingertip injuries due to mixer-grinders.<sup>10</sup> In their study, the majority of the patients were housewives, who had sustained the injuries while working in the kitchen. We found right-hand dominance in (85.7%) patients and left-hand dominance in (14.3%) patients. The right hand was injured in (74.60%) patients while the left hand was injured in (25.40%). Most of the men (78.90%) had an injury in the dominant hand. In our study, the reason for fewer injuries in dominant hands in women is that they hold the knife with the dominant hand to cut the eatables and accidentally sustain injuries in their non-dominant hands. These results are consistent with those found by Beaton AA et al.,<sup>11</sup> who found patients with right dominance comprising of 83.3% and left-hand dominant constituted 16.7% of the study subjects.<sup>11</sup> In 75% of subjects right hand was injured and in 25% it was the left hand which was injured. Beaton AA et al. had results similar to ours, where right-hand was dominant (97.2%) and sustained injuries more commonly than left-hand. Since there are a variety of treatment options for finger-tip injuries, each one with its merits and demerits and varying complexities. Though treatment options are multiple, and the goals are common and including preservation of useful sensation, maximizing functional length, preventing joint contractures, providing satisfactory appearance and avoiding donor disfigurement and functional loss.<sup>12</sup> The factors which guide the operating surgeon to select an option for a particular patient include patient age, sex, hand dominance, profession, hobbies, location, depth, angle of the defect, nail bed involvement, the status of the remaining soft tissue, co-morbid conditions and the anatomy of the fingertip defect. Routinely the operative procedures start by providing appropriate and adequate analgesia, thorough cleaning with copious saline and debridement of devitalised tissue. The management offered in our study includes primary skin suturing (PSS), V-Y advancement flap, reverse homodigital artery flap (RHAF), Nail bed repair and K wire fixation. In that majority of patients suggested with PSS and V-Y Flap. For these injuries the repair technique is determined by the plane of amputation and the condition of the surrounding tissues. The V-Y plasty technique is used to reconstruct amputations with dorsal or transverse plane.<sup>13</sup> George A et al. in their study comparing innervated cross-finger flap with non-innervated cross-finger flap concluded that sensation and two-point discrimination was better in innervated cross-finger flaps.<sup>14</sup> Since thumb constitutes 40% of the human hand function, the injuries of thumb need special consideration. Preservation of thumb length is essential to retain the optimal hand function. For appropriate defects less than 1.5cm<sup>2</sup>, the volar advancement (Moberg flap) is

preferred as it advances durable sensate skin to the thumb tip.<sup>15</sup> First dorsal metacarpal artery (FDMA) flap or the Littler flap are often required for ~~glabrous-glabrous~~ and sensate resurfacing with preservation of thumb length.<sup>16</sup> Moberg flap is not attempted in fingers as the dorsal vascular anatomy is dependent on the proper digital vessels in fingers. Nail bed lacerations are very delicate injuries and need a meticulous repair and should be repaired, preferably under loupe magnification to prevent scarring and consequent nail plate abnormalities.<sup>17,18</sup>

## CONCLUSION

In our epidemiological study regarding fingertip injuries, there is sparse information available via other forms of research. Our study occurring in Kancheepuram district, an area with large industrial presence, whose employees are prone to have fingertip injuries is very suitable for our topic of research. And from the collected data it is observed that, right-handed males between the age of 18-25 are most likely to suffer from finger tip injuries.

**Ethical approval:** Obtained

## REFERENCES

1. Gudin M, Pangman WJ. The repair of surface defects of fingers by trans-digital flaps. *Plastic and Reconstructive Surgery*. 1950 Apr 1;5(4):368.
2. Lee NH, Pae WS, Roh SG, Oh KJ, Bae CS, Yang KM. Innervated cross-finger pulp flap for reconstruction of the fingertip. *Arch Plast Surg*. 2012;39(6):637-642.
3. Moberg E. Aspects of sensation in reconstructive surgery of the upper extremity. *JBJS*. 1964 Jun 1;46(4):817-25.
4. Small JO, Brennen MD. The first dorsal metacarpal artery neurovascular island flap. *J Hand Surg Br*. 1988;13:136-45.
5. Zook EG, Guy RJ, Russell RC. A study of nail bed injuries: causes, treatment, and prognosis. *J Hand Surg Am*. 1984;9(2):247-252.

6. Nagi GS, Singh J. Fingertip injuries-surgical management and its outcome. *Int J Surg Sci.* 2019; 3(4): 394-39
7. Madden MR, Nolan E, Finkelstein JL, et al. Comparison of an occlusive and a semi-occlusive dressing and the effect of the wound exudate upon keratinocyte proliferation. *J Trauma.* 1989;29(7):924-931.
8. Saraf S, Tiwari V. Fingertip injuries. *Indian J Orthop.* 2007;41(2):163-168.
9. Karthi SV, Suresh GB, Shanmuga SP. Surgical management of fingertip injuries. *Int J Res Orthop*2017;3:19-22.
10. Hongaiah D, Abhilash, Kumar D, Vijay KS. Mixer grinder fingertip injuries and treatment outcome in a rural based tertiary center: a retrospective study. *Int Surg J* 2019;6:2458- 63
11. Beaton AA, Williams L, Moseley LG. Handedness and hand injuries. *J Hand Surg Br.* 1994;19(2):158-161.
12. de Alwis W. Fingertip injuries. *Emerg Med Australas.* 2006;18(3):229-237.
13. Yeo CJ, Sebastin SJ, Chong AK. Fingertip injuries. *Singapore Med J.* 2010;51(1):78-87.
14. George A, Alexander R, Manju C. Management of Nail Bed Injuries Associated with Fingertip Injuries. *Indian J Orthop.* 2017;51(6):709-713.
15. Norman G. Likert scales, levels of measurement and the "laws" of statistics. *Adv Health Sci Educ Theory Pract.* 2010;15(5):625-632.
16. Russell RC, Casas LA. Management of fingertip injuries. *Clin Plast Surg.* 1989;16(3):405-425.
17. Henry M, Stutz C. Homodigital antegrade-flow neurovascular pedicle flaps for sensate reconstruction of fingertip amputation injuries. *J Hand Surg Am.* 2006;31(7):1220-1225.
18. E, Ioakimidis E, Kasdan ML, Kutz JE, Kleinert HE. Reconstruction of the amputated finger tip with a triangular volar flap. A new surgical procedure. *J Bone Joint Surg Am.* 1970;52(5):921-926.