

MORPHOMETRIC CT BASED ANALYSIS OF CERVICAL PEDICLE AND FACET JOINTS IN SOUTH INDIAN POPULATION

Abstract:

Title: Morphometric CT based analysis of cervical pedicle and facet joints in South Indian population.

Aim: To evaluate individual morphometric variations of the cervical spine pedicles and facet joints by computed tomography among patients attending a tertiary care centre.

Methodology: A cross-sectional retrospective study was carried among 25 subjects who underwent CT study of cervical spine in Saveetha Medical College and Hospitals, Thandalam. Various measurements of the cervical pedicles and facet joints were obtained and analysed into their mean, standard deviation and range using appropriate statistical software.

Results: Among the 25 subjects, 56% were males and 44% were females with mean age of 59.9 and 55.2 respectively. Pedicle length (PL) and Pedicle height (PH) was comparatively smaller in women than in men. Pedicle isthmus (PI) and Lateral pedicle distance (LPD) of C7 is the greatest in both genders. Pedicle axial length (PAL) is equal in both genders with left side being more than the right. Maximum Superior Pedicle distance (SPD) is found to be at C5 level in both genders. Sagittal angulation showed lesser values in females and the Transverse angulation is the lowest at C7 level in both genders. Facet tropism showed a decreasing pattern from C3 to C7 in both genders.

Conclusion: This study helps the surgeon to understand variations in the morphometrics of the study population and will be useful in the determination of a safe treatment modality.

Keywords:

Cervical pedicles, Joint facets, Computed tomography.

Introduction:

Cervical spine, the foundation of the vertebral column consisting of different parts and structures encompassing several vital neurovascular components is well known for its

complexity. Curvature of the cervical spine is maintained from when the baby starts to hold its head on its own. The lordotic cervical spine has an angle of curvature varying from 20 to 40 degrees normally.^[1] Morphologically, the seven cervical vertebrae are divided into typical which includes C3 to C6 vertebrae and atypical which includes C1, C2, and C7. The typical vertebrae have a small body, pedicles connecting lateral mass containing the joint facets, vertebral foramen and bifid spinous process. C1 and C2 or the atlas and the axis is fused together and the intervertebral space is absent between them. C1 has no body and C2 has an odontoid process called the Den. C7 or the vertebrae prominens has a long spinous process which may not always be bifid. The most important differentiating feature of the cervical vertebrae from the others, is the presence of the foramen transversarium or transverse foramen in which runs the major artery of the neck, the vertebral artery and it also contains the vertebral vein and sympathetic nerves. In C7, the transverse foramen may be small or may not be present in some individuals^[2].

Comment [JK1]: Adding an article THE

Comment [JK2]: Consider adding a space.

With all of its complexity and individual variations, the cervical spine tends to succumb to an array of diseases like degenerations, stenosis and trauma. Management for these often needs a surgical intervention. Earlier, surgeries like arthrodesis or spinal fusion were done but now newer procedures like lateral mass fixation and the latest cervical pedicle screw fixation surgeries are done.^[3] Studies have revealed that yields of cervical pedicle screw fixation are much better than lateral mass fixation.^[4] Hence, due to its greater stabilizing potential, cervical pedicle screw may become the gold standard management of cervical spine diseases.^[5] But with its higher productivity, it also carries with it, a grave threat to the nearby neurovascular structures which could get damaged during the screw fixation into the cervical pedicle below the facet joints. To prevent these crucial injuries, pre-operative understanding of the patient's cervical spine morphometrics using computed tomography and image guided screw fixation is needed.^[6]

Comment [JK3]: Due to it's

Comment [JK4]: For management

In this study, we retrospectively analyse the morphometry of lower cervical pedicle and joint facets which are most often affected by degenerative diseases, using computed tomography (CT) in patients attending a tertiary care centre, to understand and increase our knowledge on the variations present among our study population which will help us to prevent any major complications while performing these complex surgical procedures.

Comment [JK5]: analyze

Methodology:

A retrospective cross-sectional descriptive study and analysis was carried out in the CT reports of patients attending Saveetha Medical College and hospital, Chennai, Tamilnadu in South India for various complaints.

A total of 25 CT reports were analysed. Sample size of the study was calculated from the formula $4pq/d^2$ based on the previous study of Rao et al.^[7]

The study was approved by the Institutional Research Board and the Institutional Ethics committee.

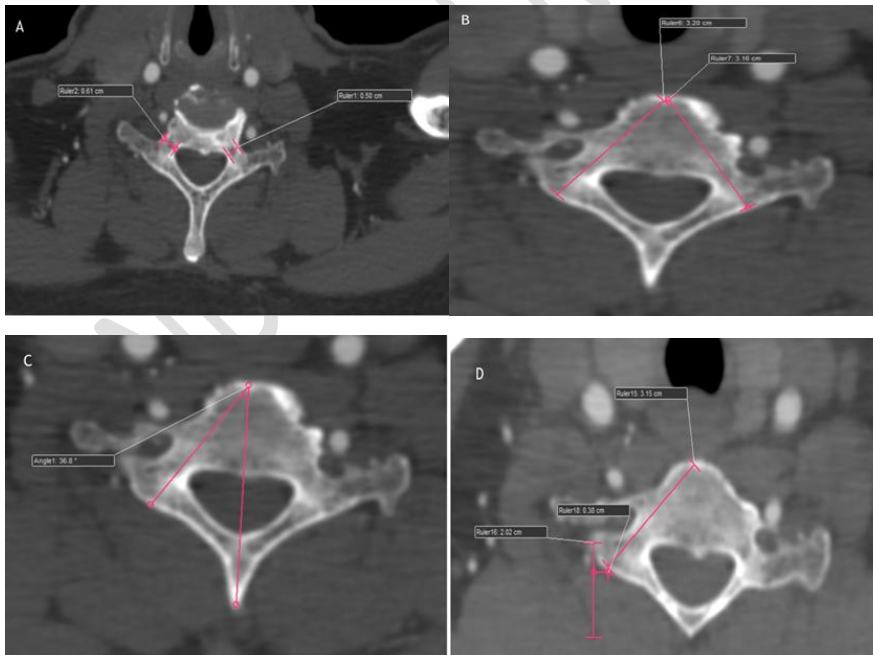
CT spine was examined in axial and sagittal plane for the following parameters which are of surgical importance,

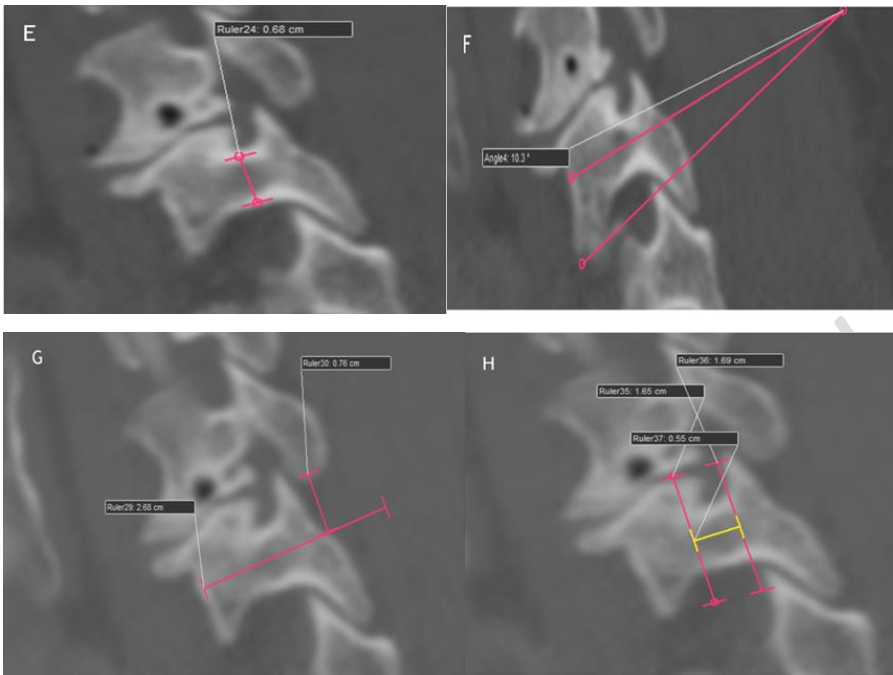
- Pedicle height (PH)
- Sagittal angulation of the pedicle (SA)

- Pedicle isthmus (PI)
- Pedicle Length (PL)
- Lateral pedicle distance (LPD)
- Superior pedicle distance (SPD)
- Pedicle axial length (PAL)
- Transverse angulation of the pedicles (TA)
- Facet trophism of the joint facets(FT)

The values were analysed and their mean, standard deviation and their range was calculated using MS Excel and Statistical Package for the Social Sciences (SPSS) software.

Fig 1(C7).A – Pedicle isthmus, B – Pedicle axis length, C – Transverse angulation
D – Lateral pedicle distance, **E** – Pedicle height, **F** – Sagittal angulation
G – Superior pedicle distance, **H** – Pedicle length





Result and Analysis:

Out of 25 patients involved in the study, 56% were males and 44% were females with a mean age of 59.9 and 55.2 respectively. Most of the study population belonged to lower socioeconomic class according to Modified Kuppuswamy Classification, and most of them were daily wage workers (43.3%) and farmers (32.1%).

The mean of pedicle length (PL) shows a steady rise from C3 to C7 in both males and females, with a reduced PL in females than in males. The pedicle height (PH) is also comparatively smaller in females than in males. The mean value of pedicle isthmus (PI) of both side in both genders are fluctuating but still the values of women are smaller than those of men and the right PI is comparatively larger than the left in both genders. The mean of C7 PI is the biggest in both genders and in both the sides. The mean of pedicle axial length (PAL) is almost equal in both male and female with the left side PAL being slightly more than the right. The mean lateral pedicle distance (LPD) values of males are more than that of the females and the LPD of C7 is the largest in both the sexes. Like the LPD, the mean value of the superior pedicle distance (SPD) of males are greater than that of the females and maximum SPD in both genders is seen at the level C5 vertebrae.

The sagittal angulation (SA) of the pedicles decreases from C3 to C5 and again increases from C6 to C7 vertebrae. The same trend is noted in both males and females with the values being lesser in females than in males. The mean of the transvers angulation (TA) of the pedicles varied from C3 to C7 in both sides and in both males and females, with lowest TA at the C7 vertebrae.

The mean of the facet tropism (FT) of the joint facets were to decreasing from C3 to C7 steadily in both sides and in both the genders and like most of the parameters the FT of females were lesser than that of the males.

Table 1. Comparison of Parameters among males and females.

Parameters	Vertebra	Males				Females				
		Mean	SD	Max	Min	Mean	SD	Max	Min	
PL (in mm)	C3	5.7	1.3	7.6	3.7	4.5	1.3	6.7	3.2	
	C4	5.7	1.2	7.6	3.8	4.7	1.0	6.5	3.4	
	C5	5.9	1.2	8.5	4.2	4.9	0.7	6.5	4.1	
	C6	6.1	1.4	8.5	4.2	5	1.5	7.5	3.2	
	C7	8.3	3.6	15.7	4.9	7.3	4.2	14.7	4	
PH (in mm)	C3	5.1	1.3	7.9	3.1	3.8	1.1	6.1	2.5	
	C4	6.8	1.2	8.7	4.5	5.7	1.3	8.2	4.1	
	C5	5.5	1.0	7.2	4.2	4.7	0.8	6.3	3.7	
	C6	6.2	1.1	7.8	4.3	5.4	1.2	7.8	3.8	
	C7	6.5	1.1	9	4.5	5.8	0.9	7.9	4.5	
PI (in mm)	C3	R	4.1	1.7	7.1	1.8	3.1	1.5	6.2	1.7
		L	4.2	1.8	6.9	2	3.2	1.6	6.4	1.7
	C4	R	5.5	1.1	7.6	3.5	4.5	0.9	6.6	3.5
		L	5.1	1.1	6.6	3.1	4.1	0.8	6.1	3.1
	C5	R	5.3	1.0	7.9	3.9	4.5	0.7	5.5	3.4
		L	4.7	0.9	6.9	3.4	3.9	0.9	5.4	2.9
	C6	R	5.2	1.5	8.3	2.7	4.3	1.0	5.4	2.2
		L	5.1	1.2	7.1	3.2	4.3	0.9	5.5	2.7
	C7	R	6	1.1	7.5	4.1	5	1.4	7.1	3.1
		L	5.8	1	7.9	4.4	5	1.1	6.3	2.9
PAL (in mm)	C3	R	29.2	2.6	33	23	28.4	1.6	32.1	26.7
		L	30.9	1.3	33.5	28.8	29.5	1.0	31.5	28.3
	C4	R	29.9	2.3	34.3	26.6	28.8	1.9	32.3	26.1
		L	30.4	1.5	33.1	28	29.4	1.4	31.1	26.9
	C5	R	30.6	1.7	33.1	27.7	29.7	1.9	32.9	27.1
		L	32.6	6.3	44	24.1	32.5	5.0	39	24.6
	C6	R	31.3	2.2	35.7	28.1	30.3	2.3	34.2	27.5
		L	32.5	2.1	36.7	29.7	31.3	1.8	34.7	29.1
	C7	R	31.6	2.3	37	28.9	30.6	2.8	38	28.5
		L	32.3	2.1	36.6	29.6	31.2	2.4	37.6	28.6
LPD (in mm)	C3	R	4.1	1.6	7.2	1.7	3	0.7	4.1	1.9
		L	3.8	1.3	5.7	1.8	2.6	0.9	4.2	1.7
	C4	R	3.4	1.5	6.9	1	2.7	0.6	3.5	1.5
		L	4.1	1.4	7.1	2.2	3.2	0.8	4.5	1.8
	C5	R	4.2	2.1	8.5	1.7	3.5	1.5	5.9	1.7
		L	3.7	1.4	6.7	1.8	3	0.9	4.1	1.6

	C6	R	4.2	1.5	7.8	1.7	3.2	1.0	5.2	2.2
		L	4.7	1.2	6.9	2.9	3.9	1.0	5.3	2.5
	C7	R	7.3	4.3	14.7	3.3	6.3	4.5	13.7	2.5
		L	8.9	6.6	19.9	3.1	7.7	6.9	18.9	2.6
SPD (in mm)	C3		6.8	1.4	9.1	4.5	6.2	2.0	10	4.1
	C4		6.1	1.9	9.3	3.2	5.1	1.4	6.9	2.7
	C5		7.4	1.1	9.1	5.4	6.8	1.2	8.5	5.4
	C6		6.9	2.1	9.5	3.3	5.7	2.2	8.8	2.3
	C7		7.2	1.2	9	4.9	6.2	1.0	8.6	5.1
SA (degrees)	C3		11.5	2.8	15.5	6.3	9.7	1.7	13.1	7.3
	C4		10.7	2.2	14.4	7.5	8.9	2.5	13.3	5.4
	C5		9.4	2.4	14.3	5	8.0	2.5	13.1	5.8
	C6		10.1	2.6	13.9	5.7	8.5	1.8	12.5	6.3
	C7		11.7	2.6	15.6	7.6	10.1	2.4	14.5	7.3
TA (degrees)	C3	R	43.6	6.2	52.7	34.5	40.5	7.9	51.3	28.9
		L	42.2	4.9	49.4	36.9	39.1	6.2	46.7	29.4
	C4	R	43.8	5.7	54.1	35.5	40.9	7.7	51.5	31.1
		L	44.7	3.8	51.6	36.8	42.6	4.9	50.3	36.3
	C5	R	41.6	4.6	58.4	35.7	39.6	6.6	51.3	31.2
		L	40.9	5.9	53.9	34.8	37.9	8.0	52.3	27.8
	C6	R	40.1	3.2	44.8	32.7	38.3	5.3	47.5	32.4
		L	41.4	4.3	46.5	33.4	39.3	4.5	47.3	32.7
	C7	R	39.8	4.5	44.8	30.9	37	3.3	42.2	32.6
		L	40.4	6.4	48.6	29.5	38.6	4.7	44.4	31.4
FT (degree)	C3	R	96.6	5.6	103.4	87	94.3	3.2	99.1	89.1
		L	97.3	5.6	104.1	86.2	95.6	3.2	100.4	90.5
	C4	R	95.4	4.9	101.2	85.9	92.7	3.4	97.5	86.3
		L	96.6	5.1	102.5	86.2	93.6	3.1	98.3	88.2
	C5	R	93.3	5.3	100.1	83.6	90.2	3.3	95.2	84.4
		L	95.9	4.6	101.3	87.5	92.5	3.1	96.7	87.3
	C6	R	93.2	4.8	99.3	86.2	90	3.4	94.5	84.1
		L	95.2	3.7	100.2	86.6	91.1	3.0	95.5	86.1
	C7	R	90.6	5.7	97.2	80.1	88.9	3.8	93.4	82.4
		L	93.5	4.8	99.1	83.1	91	4	99.1	85.3

Discussion:

Cervical vertebrae being the start of the entire column of vertebrae, has unique anatomical variations from C1 to C7 and even from person to person. Being the most mobile among the vertebrae, cervical vertebrae especially the lower cervical vertebrae have the highest risk of developing degenerative diseases, which are debilitating and needs intervention. Most of these diseases require complex and intricate surgical interventions.

Due to its anatomical and individual variations, interventional surgery to the lower cervical vertebrae poses a greater risk of damage to the neighbouring neurovascular structures, unless one has good enough pre-operative orientation of the patients' vertebrae. Our study helps us to understand anatomical variations among our study population. This will help us understand the need for pre-operative morphometric analysis of the vertebrae to prevent hazardous mishaps.

In our study, the mean value of PL in 5.7 – 8.3mm in males and 4.5 to 7.3 in females, with increasing PL from C3 to C7. In the study conducted by Mahiphot J et al, revealed that PL was highest in C3 and decreasing towards C7^[8].

The mean PH ranged between 5.1 – 6.8mm in males and 3.8 – 5.7mm in females as compared to the overall mean value of 6.1 – 7.3mm in Herrero et al study among the Latin Population^[9] and 6.7 – 7.6mm in Liu et al study.^[10] The smallest PH in C3 as against C5 and C6 recorded in the study of Westermann et al and the largest PH in C4 and C7 similar to that of Westermann et al study.^[11] Similar to Rao et al study^[7] and Westermann et al study^[11] PH of women were smaller than that of males.

The mean of PAL ranged between 28.4 – 32.6mm overall, slightly lesser than the study of Herero et al (29.4 – 33.4 mm)^[10] and almost similar to that of Ruofu et al study (28.2 – 31.7mm).^[12] The PAL of women were lower than that of the males as similar to Herrero et al study.^[9]

The sagittal angulation of the pedicles (SA) ranged between 9.4° to 11.7° as opposed to the range of 15.2° to 23.7° in Herrero et al study. The smallest SA is in the C5 vertebrae in both genders unlike Herrero et al study which had C3 as the smallest and similar to Herrero et al study the largest SA is at C7 vertebrae in both sexes.^[9] The SA in our study population showed uniform declination from C3 to C5 and steady rise again from C6 to C7 in both the genders.

The mean transverse angulation (TA) in our study ranges between 37° – 44.7°, almost similar to the Chanplakorn et al study^[13] in which the TA ranged between 38.9° – 44.1°. Similar to the studies of Chanplakorn et al, Herrero et al and Rao et al, the smallest TA was found to be in C7 vertebrae and the largest was in C4.^[7, 9, 13]

Hence these parameters are extremely crucial to be analysed pre-operatively to prevent any kind of neurovascular damage and enhance the prognosis of the treatment provided.

Conclusion:

Cervical spine diseases requiring therapeutic interventions need complete understanding of an individual's cervical spine morphometrics pre-operatively to increase the prognosis and reduce any catastrophic injuries to the neighbouring neurovascular structures.

References:

1. Borden AB, Rechtman AM, Gershon-Cohen J. The normal cervical lordosis. *Radiology*. 1960 May;74(5):806-9.

2. Abdul RS, Lazarus L, Rennie C, Satyapal KS. The Foramen Transversarium of Typical and Atypical Cervical Vertebrae: Morphology and Morphometry. *International Journal of Morphology*. 2018 Dec 1;36(4).
3. Banerjee PS, Roychoudhury A, Karmakar SK. Morphometric analysis of the cervical spine of Indian population by using computerized tomography. *Journal of Medical & Allied Sciences*. 2012 Aug 31;2(2):66.
4. Jones EL, Heller JG, Silcox H, Hutton WC. Cervical pedicle screws versus lateral mass screws. Anatomic feasibility and biomechanical comparison. *Spine* 1997;22:977-82.
5. Patwardhan AR, Nemade PS, Bhosale SK, Srivastava SK. Computed tomography-based morphometric analysis of cervical pedicles in Indian population: a pilot study to assess feasibility of transpedicular screw fixation. *Journal of postgraduate medicine*. 2012 Apr 1;58(2):119.
6. Munusamy T, Thien A, Anthony MG, Bakthavachalam R, Dinesh SK. Computed tomographic morphometric analysis of cervical pedicles in a multi-ethnic Asian population and relevance to subaxial cervical pedicle screw fixation. *European Spine Journal*. 2015 Jan;24(1):120-6.
7. Rao, Raj D. MD1; Marawar, Satyajit V. MD1; Stemper, Brian D. PhD1; Yoganandan, Narayan PhD1; Shender, Barry S. PhD2 Computerized Tomographic Morphometric Analysis of Subaxial Cervical Spine Pedicles in Young Asymptomatic Volunteers, *The Journal of Bone & Joint Surgery: September 01, 2008 - Volume 90 - Issue 9 - p 1914-1921*doi: 10.2106/JBJS.G.0116.
8. Mahiphot J, Iamsaard S, Sawatpanich T, Sae-Jung S, Khamanarong K. A morphometric study on subaxial cervical pedicles of Thai people. *Spine*. 2019 May 15;44(10):E579-84.
9. Herrero CF, do Nascimento AL, Maranhão DA, Ferreira-Filho NM, Nogueira CP, Nogueira-Barbosa MH, Defino HL. Cervical pedicle morphometry in a Latin American population: A Brazilian study. *Medicine*. 2016 Jun;95(25).
10. Liu J, Napolitano JT, Ebraheim NA. Systematic review of cervical pedicle dimensions and projections. *Spine* 2010; 35(24):E1373-E1380
11. Westermann L, Spemes C, Eysel P, Simons M, Scheyerer MJ, Siewe J, Baschera D. Computer tomography-based morphometric analysis of the cervical spine pedicles C3–C7. *Acta neurochirurgica*. 2018 Apr;160(4):863-71.
12. Ruofu Z, Huilin Y, Xiaoyun H, Xishun H, Tiansi T, Liang C, Xigong L. CT evaluation of cervical pedicle in a Chinese population for surgical application of transpedicular screw placement. *Surgical and Radiologic Anatomy*. 2008 Jul;30(5):389-96.
13. Chanplakorn P, Kraiwattanapong C, Aroonjarattham K, Leelapattana P, Keorochana G, Jaovisidha S, Wajanavisit W. Morphometric evaluation of subaxial cervical spine using multi-detector computerized tomography (MD-CT) scan: the consideration for cervical pedicle screws fixation. *BMC musculoskeletal disorders*. 2014 Dec;15(1):1-0.