

## Incidence of Granulomatous Mastitis at Saveetha Medical College and Hospital for the past two years

### Abstract:

**Aim:** To find the incidence of Granulomatous mastitis at Saveetha Medical College and Hospital.

**Method and material :** Retrospective study Incidence of Granulomatous Mastitis at Saveetha Medical College and Hospital for the past two years . The specimens were received from histopathology section of pathology department. Detailed gross examination of specimen was done followed by fixation and staining was done using hematoxylin and eosin stains.

**Result :**In the period of two years from 2019 to 2020 , nine cases have been reported . Out of which five cases belonged to the reproductive age group, three cases in the post menopausal age group and one case belonged to peri menopausal age group. All the patients presented with a lump on the breast and abscess. The treatment consists of corticosteroid therapy and minimal surgical intervention.

**Conclusion:** Granulomatous mastitis is a inflammatory condition that mimics carcinoma of breast. Hence diagnosis is mainly made through exclusion and examination of histopathology slides. Core needle biopsy is the gold standard technique used in the diagnosis of the condition. It's a self limiting disease, and requires surveillance,corticosteroid therapy and surgical intervention.

### Introduction:

Granulomatous mastitis is a rare chronic inflammatory condition of the breast , with no known etiology(1). It can also occur as a secondary complication of tuberculosis,sarcoidosis.It can be divided into two categories, one being idiopathic ( granular lobar mastitis ), and the other occurring as a secondary complication (2). It usually occurs on average between two to six years after pregnancy, age ranges between 17 - 42 years. Granulomatous mastitis can be easily confused with cancer but it is a benign condition . It is also necessary to differentiate between idiopathic and other forms of Granulomatous mastitis as the treatment varies for both conditions. Diagnosis is usually made by exclusion as the etiology is unknown. The condition has various clinical presentations (3).

### Clinical features:

**Comment [D1]:** The format of the abstract is not in line with authors guide by the journal, please restructure your abstract.

**Comment [D2]:** This introduction is not enough for this study.

Granulomatous mastitis is composed of chronic inflammatory infiltrates and shows clusters of histiocytes and multi nucleated giant cells ( granulomata ) . These lesions rarely shows necrosis unlike tuberculosis of breast (4). The patient experiences breast pain with a lump , abscess formation with fistula tract formation , nipple retraction , peau d orange appearance , rarely lymphadenopathy . Usually mimics breast cancer ( inflammatory breast cancer ) (5). It's usually unilateral , but can also be bilateral. As symptoms can recur, it's always difficult to differentiate it from carcinoma of breast.

### **Diagnosis:**

Since etiology of Granulomatous mastitis is unclear , diagnosis is usually made by exclusion. Breast core biopsy or surgical excision with histopathological examination should be done. The gold standard technique for diagnosing involves core needle biopsy. It has higher sensitivity when compared to fine needle aspiration.

Granulomatous mastitis is characterized by the formation of non necrotising Granulomatous with infiltration of multi nucleated giant cells, histiocytes, plasma cells and lymphocytes. When inflammation extends into the nearby lobules it indicates higher severity(6).

Sarcoidosis is differentiated from Granulomatous mastitis when there is presence of fever, arthritis , erythema nodosum. In cases of tuberculosis the patient might have a lung involvement or a weakened immune system.

### **Histopathology:**

The samples are stained using hematoxylin and eosin . Histopathological investigations may reveal the following features - lobulocentric granulomatous inflammation, Granulomas often contain neutrophils. Multinucleated giant cells, lymphocytes, plasma cells and histiocytes can be seen within and around the lobules. In case of extensive inflammation , it might obliterate the lobulocentric distribution(7).

### **Radiology:**

Nonspecific imaging findings. Mammography: focal asymmetric density.

Ultrasound: irregular hypoechoic mass with tubular projections.

MRI: nonmass-like enhancement; ring enhancing lesions.

The gross features include grey firm mass with varying size of 5-6cm , with ill defined margins and subtle nodularity. It is a challenge for both pathologist and the clinician to differentiate Granulomatous mastitis from other inflammatory conditions of the breast such as tuberculosis, sarcoidosis. The diagnosis mainly relies on biopsy which should be higher in quality and quantity and this is attained by core biopsy when compared to fine needle aspiration.

### **Treatment:**

There is no specific treatment protocol for Granulomatous mastitis. Each treatment is tailored according to the needs of the patient .Most patients fully recover after a period of 2 -24

months(8). Antibiotics are of no use in these conditions. Corticosteroid therapy is recommended for a period of 6 months. It should be given only after infections have been excluded. Other immunosuppressant drugs such as azathioprine and methotrexate is given in cases of persistent and recurrent conditions. Steroids can cause elevated levels of prolactin hormone , thus they are given in combination with prolactin lowering drugs such as bromocriptine. The combination has been used in countries like Germany with good results (9).

Prolactin reducing drugs has also reduced the recurrence rate.

Methotrexate is also used in combination with steroids with good results. Colchicine, azathioprine, and NSAIDs are also used in the treatment of Granulomatous mastitis.

### **Method :**

This is a retrospective study reviewing the pathology database of the year 2019 to 2020.

About ten patients were diagnosed with Granulomatous mastitis. The diagnosis was done through core biopsy, FNAC, from the specimen collected from the abscess drainage, usg.

The obtained specimens were then stained with hematoxylin-eosin stains. Each specimen thus obtained where carefully reviewed by the pathologist.

The cases thus obtained were evenly spread out through a span of two years.

Out of the 432 specimens sent for examination about 240 specimens were identified including 10 Granulomatous mastitis.

This study is based on the ten cases - their investigations and treatment and comparing them with other studies.

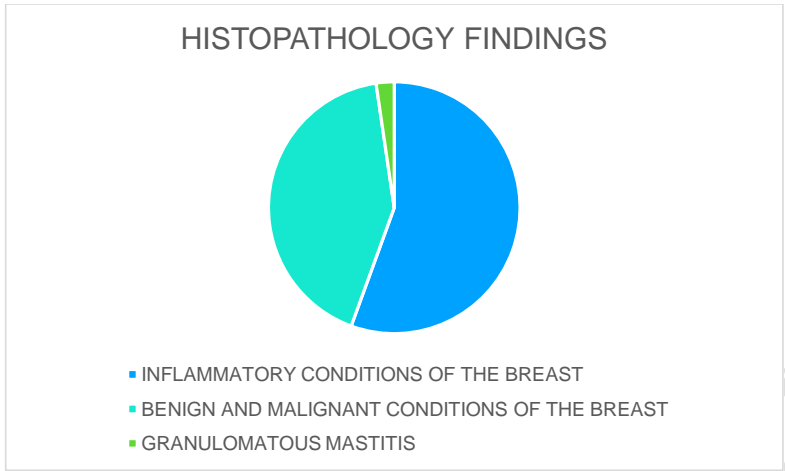
**Comment [D3]:** Very poor formatting of the method., need some statistical explanation and some related work

### **Result:**

About 432 specimens have been sent to the pathology department of Saveetha Medical College and Hospital for histopathological evaluation. Out of these specimens, 10 cases of granulomatous mastitis have been identified.

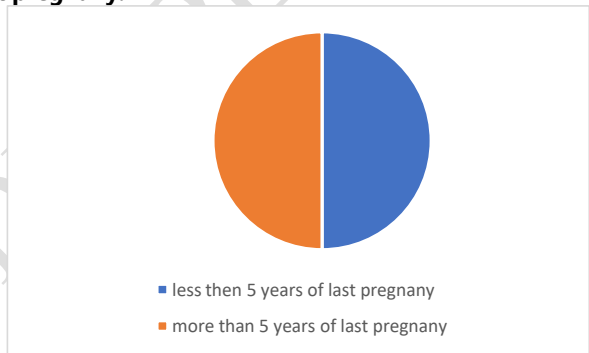
The following diagram shows the histopathological findings in the form of pie chart.

**Figure 1: Pie chart showing the histopathological findings**



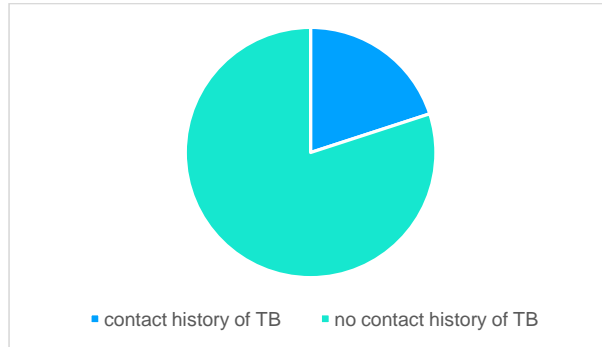
Patients background and initial symptoms are mentioned in Table 1 .  
 Of the ten patients five patients belong to the reproductive age group , two in the premenopausal phase and the remaining five cases in the post menopausal age group. Five cases have occurred in women in less than 5 years following their last pregnancy. The following figure shows this in the form of a pie chart.

**Figure 2 :Pie chart showing the incidence of granulomatous mastitis in less than and more than 5 years of last pregnancy.**



Five patients have breast fed in the last 5 years, but are not lactating in the present time .Two out of the ten patients had a contact history of tuberculosis, while the remaining eight had no such contact history. The following figure shows incidence of granulomatous mastitis in patients with contact history of Tuberculosis.

**Figure 3 : Pie chart showing the incidence of granulomatous mastitis in patients with contact history of TB.**



All of these patients had unilateral breast lesions. They had no history of contraceptive use, smoking or any medical findings of sarcoidosis, Bechets disease. All of these patients had a common presentation of breast swelling or lump with discharge, abscess and mastitis.

**Table : 1 Patients background and initial symptoms**

Case no.	Age.	Parity.	Less than 5y from last pregnancy	Contact history Tuberculosis	Symptoms
1.	41	2	No	Yes	Swelling with discharge right breast.
2.	26.	2.	Yes.	No.	Right breast lump
3.	60.	3.	No.	No.	Left breast swelling with Discharge
4.	32.	2.	Yes.	No.	Right breast lump
5.	42.	2.	No.	Yes	Right breast lump

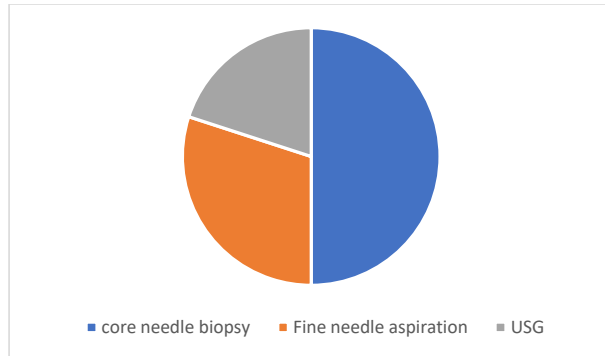
6.	50.	4.	No.	No.	Right breast mastitis
7.	27.	1.	Yes.	No.	Abscess
8.	30.	1.	Yes.	No.	Mastitis
9.	65.	3.	No.	No.	Breast swelling with Discharge
10.	26.	1.	Yes.	No.	Mastitis

The investigations and treatment procedures are given in table 2. All the patients had most common presentation of breast swelling ,discharge and abscess.

In case no.1 the patient had swelling with discharge and also similar history in the past. On further investigation usg showed thick walled collection in the right breast . Excisional biopsy is done under general anesthesia.

Case no.2 the patient had lump on the right breast . Fine needle aspiration was done and excisional biopsy was done under general anesthesia. Case no.3 had a left breast swelling with discharge, usg showed irregular hypo-echoic mass. Since it was a 60 year old female mastectomy was performed . Mastectomy was also performed on case number nine, who had breast swelling with discharge. Of the ten cases , core biopsy was done in five cases and they all had excisional biopsy done as a treatment procedure.

**Figure 4: Pie chart showing the investigations done in cases of granulomatous mastitis.**



The investigation of choice would be core needle , as the specimen acquired would be higher in terms of quality and quantity. Histopathological investigation is very important ,since it is difficult to differentiate granulomatous mastitis from other forms of inflammatory conditions of the breast.

Treatment is always tailored according to the symptoms of the patients. Medical treatment mainly involves around relieving the pain. Corticosteroids are the commonly prescribed drugs. Prolactin reducing drugs has also reduced the recurrence rate.

Methotrexate is also used in combination with steroids with good results. Colchicine, azathioprine, and NSAIDs are also used in the treatment of Granulomatous mastitis.

**Table 2 : Investigations and treatment**

Case no.	Investigations.	Treatment procedure
1.	USG - thick walled collection in right breast.	Excision biopsy done under general anesthesia.
2.	FNAC	Excision biopsy done under General anesthesia.
3.	USG - irregular hypo-echoic mass	Mastectomy
4.	Core needle biopsy general anesthesia	Excision done under
5.	Core needle biopsy	Excision done under general anesthesia.

6.	Core needle biopsy	Mastectomy
7.	FNAC.	Biopsy done under general general anesthesia.
8.	Core needle biopsy	Excision done under general anesthesia.
9.	USG - thick walled swelling left breast	Mastectomy
10.	Core needle biopsy. Anesthesia.	Excision done under general

Prolactin reducing drugs has also reduced the recurrence rate.

Methotrexate is also used in combination with steroids with good results. Colchicine, azathioprine, and NSAIDs are also used in the treatment of Granulomatous mastitis.

### Discussion:

Granulomatous mastitis is a rare chronic inflammatory condition of the breast. It was first described in the year 1972. As of now no known etiologies have been found and the pathology is unknown for idiopathic granulomatous mastitis. It can also occur as a secondary complication of tuberculosis, sarcoidosis.

Investigations mainly involve histopathology .The samples are stained using hematoxylin-eosin stains . Histopathological investigations may reveal the following features - lobulocentric granulomatous inflammation, Granulomas often contain neutrophils. Multinucleated giant cells, lymphocytes, plasma cells and histiocytes can be seen within and around the lobules. In case of extensive inflammation , it might obliterate the lobulocentric distribution. The samples are obtained through core biopsy. Diagnosis mainly depend on the biopsy thus it should be of higher quality and quantity. This is achieved through core needle biopsy ( gold standard technique). It is very difficult for both the clinicians and pathologist to differentiate this condition from other inflammatory conditions of the breast.

This study was conducted at Saveetha Medical college and Hospital for the past two years . The following results were obtained.

In the past two years from 2019 to 2020 ten cases of Granulomatous mastitis has been observed and the records were obtained from the histopathology department.

Out of the nine cases reported , seven were from the year 2019 and the remaining three cases were from the year 2020.

From the ten cases identified , five cases belonged to the reproductive age group,two cases in the perimenopausal age group , remaining three cases were in the post menopausal age group. Two patients had contact history of tuberculosis. The condition has occurred in five patients within five years of their last pregnancy. None of these patients had any history of comorbid illness , except one patient who is a known case of diabetes mellitus under medication. The investigation methods used in our hospital are core needle biopsy [ gold standard technique] ,fine needle aspiration and usg .

There is no specific treatment protocol for Granulomatous mastitis. Each treatment is tailored according to the needs of the patient .Most patients fully recover after a period of 2 -24 months(8). Antibiotics are of no use in these conditions. Corticosteroid therapy is recommended for a period of 6 months. It should be given only after infections have been excluded. Other immunosuppressant drugs such as azathioprine and methotrexate is given in cases of persistent and recurrent conditions. Steroids can cause elevated levels of prolactin hormone , thus they are given in combination with prolactin lowering drugs such as bromocriptine. The combination has been used in countries like Germany with good results (9).

Prolactin reducing drugs has also reduced the recurrence rate.

Methotrexate is also used in combination with steroids with good results. Colchicine, azathioprine, and NSAIDs are also used in the treatment of Granulomatous mastitis.

Excisional biopsy under general anesthesia was done in eight patients and remaining two patients underwent mastectomy.

I compared my case study with another case study titled Management of Granulomatous Mastitis: A Series of 13 Patients Who Were Evaluated for Treatment Without Corticosteroids Masao Yukawa et al(10). Their research was spread over period of 13 years from 2001 to 2013. About 13 cases were reported . All of them were less than 5 years from their last pregnancy and all 13 of them have history of usage of antidepressant drugs. The patients presented with breast lumps , mastitis. Previous studies have shown that the occurrence of GM without a history of recent pregnancy is uncommon. However, antidepressants can cause hyperprolactinemia which in turn may cause breast swelling and/or galactorrhea, The treatments were tailored accordingly to treat their presenting symptoms . Most of the patients were prescribed corticosteroids. Since Granulomatous mastitis is a self limiting disease , treatment mainly consists of close surveillance with minimal surgical intervention.

Al-Khaffaf *et al*(11) reported that 18 cases of GM spontaneously resolved in a period of 11 to 105 weeks, regardless of the treatment procedures used.

It's a self limiting disease but treatment consists of corticosteroid therapy , drainage of abscess and minimal surgical intervention

## **Conclusion:**

Granulomatous mastitis is a rare benign inflammatory condition of the breast, with unknown etiology and pathology . It can also occur as a secondary complication of tuberculosis and sarcoidosis. Clinical features include breast lump ,pain , mastitis, abscess , nipple retraction, peau d orange appearance rarely lymphadenopathy. It mimics carcinoma of the breast.

Histopathology is of much importance as it helps to differentiate it from other inflammatory conditions of the breast. It's a self limiting disease but treatment consists of corticosteroid therapy , drainage of abscess and minimal surgical intervention.

### Reference:

- (1)- [ncbi.nlm.nih.gov](http://ncbi.nlm.nih.gov) Management of Granulomatous mastitis : series of 13 patients who were evaluated for treatment without corticosteroid. Masavo Yukawa et al.
- (2)-Idiopathic granulomatous mastitis: a mimicking disease in a pregnant woman: a case report Juan A Garcia-Rodriguez and Andrew Pattullo.
- (3)-Idiopathic granulomatous mastitis: a heterogeneous disease with variable clinical presentation  
Muna M Baslaim , Hind A Khayat, Shefaa A Al-Amoudi
- (4)- Hughes, Mansel , Webster benign disorders and diseases of breast third edition.
- (5)-Idiopathic granulomatous mastitis systemic movie review of 3060 patients. David Martinez et al.
- (6)-Granulomatous mastitis it is an autoimmune disease ; diagnostic and therapeutic dilemmas Ozel L et al.
- (7)- Granulomatous mastitis :clinicopathological review of 26 cases. Gary M K Tse et al. Pubmed.ncbi.nlm.nih.gov.
- (8)- The role of conservative treatment in Idiopathic Granulomatous Mastitis. E C H Lai et al.
- (9)- Puerperal and non- puerperal mastitis – A Krause , Gerber B ; Rhode E.
- (10)-[ncbi.nlm.nih.gov](http://ncbi.nlm.nih.gov) Management of Granulomatous mastitis : series of 13 patients who were evaluated for treatment without corticosteroid. Masavo Yukawa et al.
- (11)- Al-Khaffaf B, Knox F, Bundred NJ. Idiopathic granulomatous mastitis: a 25-year experience. *J Am Coll Surg.* 2008;206(2):269–273.

**Comment [D4]:** Poor arrangement of references and non is found in the body of the work.