

COMPARISON OF THE MODIFIED ALVARADO SCORE AND ULTRASONOGRAPHY FOR DIAGNOSING ACUTE APPENDICITIS

ABSTRACT:

BACKGROUND: Acute appendicitis can be diagnosed much accurately by using Modified Alvarado score and Ultrasound together in the clinical setting.

OBJECTIVES: Comparison of the diagnostic accuracy of Modified Alvarado score and Ultrasonographic findings in acute appendicitis.

MATERIALS AND METHODS: A total of 200 patients of age group ranging from 4-65 years, both male and female, who visited the tertiary health care center with clinical features suggestive of acute appendicitis were randomly selected randomly who visited the tertiary health care center. Data from the patients regarding their Modified Alvarado score, ultrasonographic findings and histopathological reports were collected for the study. Statistical analysis was performed for the results of both Modified Alvarado score and Ultrasonographic findings in contrast to the pathology reports.

RESULTS: The study included 200 patients, with maximum incidence of acute appendicitis seen in mm males (70.5%) and among 21-30 age groups (40.5%). The sensitivity, specificity of Modified Alvarado Score was 89.47% and 73.33%, with Positive Predictive Value, Negative Predictive Value and diagnostic accuracy being 40%, 73.33% and 45 % respectively. Ultrasonography revealed 89.58% sensitivity, 15.62 % specificity, Positive predictive value and NPV were 75.88% and 50%, and diagnostic accuracy was 72%. The negative appendectomies rates accounted to 15%.

CONCLUSION: It is advised that both Modified Alvarado score and Ultrasound can be used to together to diagnose acute appendicitis. This can be useful in decreasing the negative appendectomies and hence reduce the morbidity and mortality

Comment [A1]: Why the random selection since both MAS system and USG were used for all the patients?

KEYWORDS: Acute appendicitis, Histopathological findings, Modified Alvarado Score, Ultrasonography.

INTRODUCTION:

Acute appendicitis is the most common and demanding surgical emergency with a lifetime prevalence of 1 in 7 cases^[1,2]. Fitz presented a classic paper 100 years ago, on the clinical features of the acute appendicitis that recommended the earliest removal of the inflamed appendix^[3]. The high mortality and morbidity in appendicitis owes to the complications such as abscess, perforation and peritonitis, hence early diagnosis is of paramount importance^[2]. Even with a high level of clinical suspicion, the negative appendectomy rates accounts for 15 - 30%^[4, 5]. In the view of decreasing the negative appendectomies as well as the appendiceal rupture rates, a number of diagnostic modalities have been proposed. The recommended ones with acceptable diagnostic accuracy are clinical scoring system, ultrasonography, computed tomography, magnetic resonance imaging and laparoscopy^[6, 7, 8]. The Alvarado score is the most commonly used clinical scoring system, its modification which doesn't include the parameter of shift of neutrophils is not considered due to the non-availability in most emergency hospitals^[9, 10, 11]. Amongst the available imaging modalities, graded compression ultrasonography is a cheap, fast, noninvasive and operator oriented method with diagnostic accuracy of 71-90% in acute appendicitis^[12, 13, 14]. The usage of Modified Alvarado score and ultrasonography combined can help in decreasing the negative appendectomy rates^[15].

Comment [A2]: The reference should be after the full stop

METHODS:

This cross sectional retrospective study includes a total of 200 patients with a provisional diagnosis of acute appendicitis. The patients included were admitted and operated in the surgical department of Saveetha Medical College and Hospital, from February 2021 to July 2021. The patients diagnosed of appendicular abscess, appendicular lump, peritonitis and patients who were pregnant ~~were was~~ excluded from the study. Written consent from the patients and assent from the parents/ guardians of the patients below 18 years of age were obtained.

CRITERIA FOR ACUTE APPENDICITIS BY MODIFIED ALVARADO SCORE

The Modified Alvarado Scoring System (MAS) criteria were applied to each patient of the study population. MAS SYSTEM components were migratory right iliac fossa pain, nausea/vomiting, anorexia, right iliac fossa tenderness, fever 37.3°C, rebound tenderness in RIF and leucocytosis >10000/cubic mm.^[9] Modified Alvarado Score ≥ 7 is likelihood of acute appendicitis.

COMPONENTS OF MODIFIED ALVARADO SCORE		SCORE
SYMPTOMS	Migratory right iliac fossa pain	1
	Nausea/ Vomiting	1
	Anorexia	1
SIGNS	Right iliac fossa(RIF) tenderness	2
	Fever 37.3°C	1
	Rebound tenderness in RIF	1
LABORATORY TEST	Leucocytosis (>10,000/mm ³)	2
TOTAL		9

Table 1: Components of Modified Alvarado Scoring System

Comment [A3]: Move it above the table

Comment [A4]: Table label should be at the top of the table, not at bottom like this.

CRITERIA FOR ACUTE APPENDICITIS BY ULTRASONOGRAPHY (USG)

Ultrasound was done in a standardized protocol involving graded compression, longitudinal and transverse images of the right lower quadrant. The findings suggestive of abnormal appendix was seen as a tubular, blind ending, aperistaltic bowel loop which is non-compressible with a diameter of 7mm or more in the anteroposterior direction. Presence of fecolith or prominence of periappendicular fat is considered as an indirect sign.

CRITERIA FOR ACUTE APPENDICITIS BY HISTOPATHOLOGICAL REPORTS (HPE)

Appendicular wall with mucosa ulcerated and transmural acute inflammatory cells infiltration (polymorphous leukocytes) up to serosa with congested blood vessels is suggestive of acute appendicitis. The histopathological reports were used for the final diagnosis of the acute appendicitis.

Statistical analysis of the above data was performed using sensitivity, specificity, positive predictive value (PPV), negative predictive value (NPV) and diagnostic accuracy. The analytical data of Modified Alvarado score and ultrasound were compared to find out the most efficient diagnostic modality for acute appendicitis.

RESULTS:

A total of 200 patients were randomly selected ~~random~~ for the retrospective study. Number of males was 141(70.5%) which was greater than females 59(29.5%) in the study. The most common age group was 21-30 years (81, 40.5%) who had provisional diagnosis of acute appendicitis.

Table 2: Sex distribution in the study population

SEX	INCIDENCE	PERCENTAGE (%)
MALE	141	70.5
FEMALE	59	29.5
TOTAL	200	100

~~Table 2: Sex distribution in the study population~~

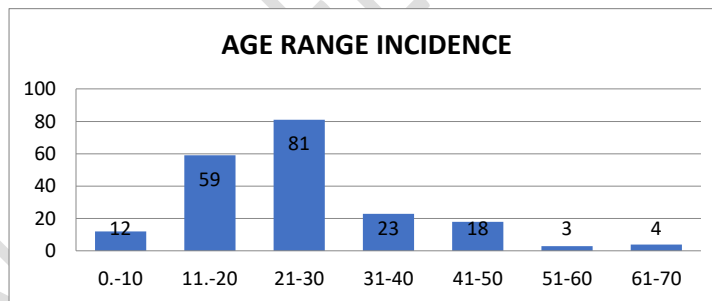


Figure 1: Age distribution in the study population

In the present study, out of the 76 patients with MAS positive (>7 MAS), 8 patients had normal appendix on the HPE reports. The remaining 124 who had a negative Alvarado score (MAS ≤7), 102 had inflamed appendix on the HPE report.

HISTOPATHOLOGICAL FINDING	MODIFIED ALVARADO SCORE NEGATIVE	MODIFIED ALVARADO SCORE POSITIVE

	<=7	>7
NO APPENDICITIS	22	8
APPENDICITIS	102	68
TOTAL	124	76

Table 3: Modified Alvarado Score with Histopathological findings

Comment [A5]: Move it above the table

In analyzing MAS data, the clinical scoring system had a sensitivity of 89.47%, specificity 73.33%, PPV 40%, NPV 73.33%, false positive error rate of 82.26%, false negative error rate of 10.53% and diagnostic accuracy of 45%.

MODIFIED ALVARADO SCORE	PERCENTAGE (%)
SENSITIVITY	89.47
SPECIFICITY	73.33
PPV	40
NPV	73.33
% OF FALSE POSITIVE	82.26
% OF FALSE NEGATIVE	10.53
DIAGNOSTIC ACCURACY	45

Table 4: Analysis of Modified Alvarado Score in diagnosis of Acute Appendicitis

Comment [A6]: The sensitivity, PPV, NPV, % of false positive and negative as well as Diagnostic accuracy are not correct. Kindly check textbook of epidemiology to ascertain the proper way to calculate these parameters

From the table below, we can interrupt that 129 patients diagnosed by USG confirmed to have appendicitis by histopathological reports. 15 patients diagnosed positive by USG found to have normal appendix by HPE reports. 41 patients with negative USG had appendicitis in the HPE reports .The remaining 15 patients had no appendicitis was diagnosed correctly by USG.

HISTOPATHOLOGICAL REPORTS	ULTRASOUND POSITIVE	ULTRASOUND NEGATIVE	TOTAL
APPENDICITIS	129	41	170
NO APPENDICITIS	15	15	30
TOTAL	144	96	200

Comment [A7]: How will 41+ 15 be equal to 96?

Table 5: Ultrasound findings with histopathological reports

Comment [A8]: Move it above the table

The sensitivity 89.58%, specificity 15.62%, PPV 75.88%, NPV 50%, false positive error rate of 42.71%, false negative error rate of 10.42% and diagnostic accuracy of 72% for ultrasound to diagnose acute appendicitis.

ULTRASONOGRAPHIC FINDINGS	PERCENTAGE (%)
SENSITIVITY	89.58
SPECIFICITY	15.62
PPV	75.88
NPV	50
% OF FALSE POSITIVE	42.71
% OF FALSE NEGATIVE	10.42
DIAGNOSTIC ACCURACY	72

Comment [A9]: The same applies here as in table 4.

Comment [A10]: For easier calculation and to avoid this kind of error, you may put the testing method(i.e MAS system or USG on the row axis while the Histology is on column axis.

Table 6: Analysis of Ultrasonographic findings in diagnosis of Acute Appendicitis

Comparing the statistical data of Ultrasound and Modified Alvarado score versus the histopathological reports in this study, we can conclude that sensitivity and diagnostic accuracy is higher in USG than MAS.

STATISTICAL ANALYSIS	MODIFIED ALVARADO SCORE (%)	USG (%)
SENSITIVITY	89.47	89.58
SPECIFICITY	73.33	15.62
DIAGNOSTIC ACCURACY	45	72

Comment [A11]: The errors in your calculation has affected every other things including your discussion

Table 7: Correlation of Sensitivity, Specificity and Diagnostic accuracy of Modified Alvarado Score and Ultrasound findings.

Comment [A12]: Move up

COMPARISON OF STATISTICAL DATA OF ULTRASONOGRAPHY AND MODIFIED ALVARADO SCORE

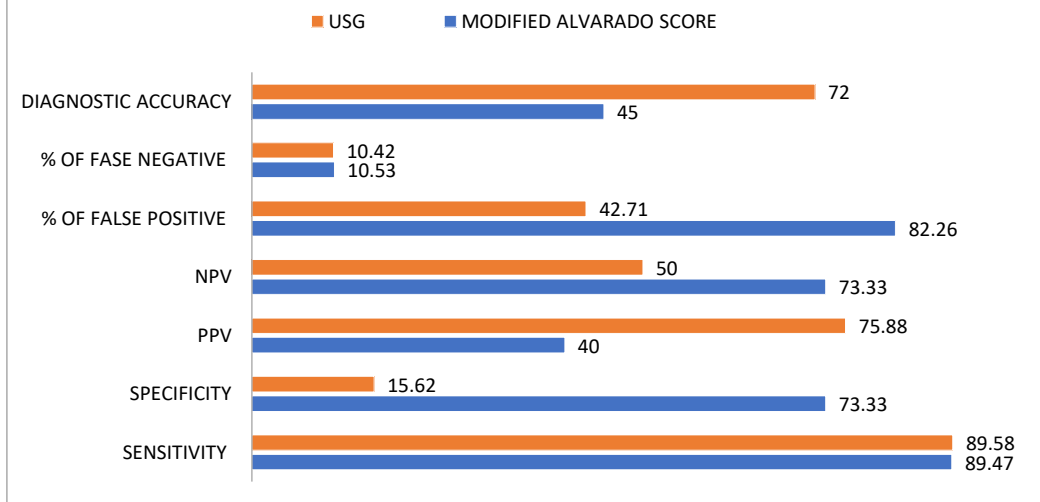


Figure 2: Comparison of Statistical Data of Ultrasonography and Modified Alvarado Score

HISTOPATHOLOGICAL RESULTS:

Acute appendicitis was confirmed in 170 patients and the remaining 30 has undergone negative appendectomies according to the HPE reports. This resulted in the negative appendectomy rate of 15%.

HISTOPATHOLOGICAL REPORT	MALE	FEMALE	TOTAL
NO APPENDICITIS	27	3	30
APPENDICITIS	114	56	170
TOTAL	141	59	200

Table 8: Sex distribution and Histopathological reports

Comment [A13]: Move it above the table

DISCUSSION:

Acute appendicitis has a high amount of clinical suspicion and results in great uncertainty for the clinician in planning the treatment for the patients. The diagnosis being primarily based on clinical findings, but they can be less severe or difficult to elicit in patients, especially in children and elderly.^[16] According to some studies, difficulties in decision making in diagnosis has led to 15-30% of negative appendectomy.^[5, 17] This in turn results in a significant financial burden in the health care system.

In our study, the incidence of acute appendicitis is more common in males (141, 70.5%) than in females (59, 29.5%). The male: female ratio 2.4:1 which is much higher than the results documented by Talukder DB et al.,^[18] (1.38: 1). The differences may due to the racial, regional and dietary variations.

The study group included people that fall under the age group ranging from 4-65 years of age. The highest incidence of appendicitis was seen among 21-30 years (81, 40.5%) followed by 11-20 years (29.5%). Approximately 70% of the cases recorded belong to the 2nd and 3rd decade. Studies by Talukder DB et al.,^[18] and Kailash et al.,^[18, 19] showed 67% incidence among the 2nd and 3rd decade individuals.

Clinical scoring systems has played a huge role in the diagnosis of acute appendicitis but most of them are complex and inefficacious in an emergency setting. Modified Alvarado Score has been reported to be a quick and economical diagnostic tool in diagnosis of acute appendicitis in patients of emergency setting^[20]. In our study, sensitivity and specificity of MAS is 89.47%, 73.33% respectively. Anada Rao et al.,^[21] documented similar sensitivity and specificity data of 88% and 75% respectively. Diagnostic accuracy of MAS in our study was 45% which was similar to the study done by Kansakar N et al.,^[22] (43.75%).

On comparing our USG data with other studies, the sensitivity and diagnostic accuracy are 89.58% and 72% respectively. This data is similar to the sensitivity and diagnostic accuracy findings of Singh SK et al.,^[23] (84.61% and 70.91% respectively). The specificity of USG 15.72% was found to be lower than most of the studies, such as Singh SK et al.,^[23] (50%) and Shinji Himeno et al.,^[24] (80%).

The negative appendectomy rate overall in our study was found to be 15% which is in accordance to the acceptable negative appendectomy rate(NAR) which is between 15-25%.^[25] Though USG has higher diagnostic accuracy than MAS, the need of clinical scoring is needed to complement the diagnosis of acute appendicitis.

CONCLUSION:

The Ultrasonography has higher sensitivity and diagnostic accuracy for predicting acute appendicitis, according to our study. Since it is operator dependant, it is advised that Modified Alvarado Score must be used in addition to USG in diagnosing acute appendicitis. This can be useful in reducing the negative appendectomy and hence reduce the morbidity and mortality.

REFERENCE:

1. Stephens PL, Mazzucco JJ. Comparison of ultrasound and the Alvarado score for the diagnosis of acute appendicitis. Connecticut medicine. 1999 Mar 1;63(3):137-40.
2. Binnebösel M, Otto J, Stumpf M, Mahnken AH, Gassler N, Schumpelick V, Truong S. Acute appendicitis. Modern diagnostics–surgical ultrasound. Chirurg. 2009;80(7):579–587.
3. Fitz RH. Perforating inflammation of the vermiform appendix with special reference to it's early diagnosis and treatment. Am J Med Sci. 1886;92:321-46.
4. Chan I, Bicknell SG, Graham M. Utility and diagnostic accuracy of sonography in detecting appendicitis in a community hospital. Am J Roentgenol. 2005;184:1809-12.
5. Flum DR, McClure TD, Morris A, Koepsell T. Misdiagnosis of appendicitis and the use of diagnostic imaging. J Am Coll Surg. 2005;201:933.
6. Olsen JB, Myren CJ, Haahr PE. Randomized study of the value of laparoscopy before appendicectomy. Br J Surg. 1993;80:922-3.

7. Teicher I, Landa B, Cohen M, Cabnick LS, Wise L. Scoring system to aid in the diagnosis of appendicitis. *Ann Surg.* 1983;198:753-9.
8. Kalan M, Rich AJ, Talbot D, Cunliffe WJ. Evaluation of the modified Alvarado score in the diagnosis of acute appendicitis: a prospective study. *Ann R Coll Surg Engl.* 1994;76:418-9.
9. Alvarado A. A practical score for early diagnosis of acute appendicitis. *Ann Emerg Med.* 1986;15:557-64.
10. Horzic M, Salamon A, Kopljar M. Analysis of scores in diagnosis of acute appendicitis in women. *Coll Antropol.* 2005;11:4.
11. Flum DR, Koepsell T. The clinical and economic correlates of misdiagnosed appendicitis: nationwide analysis. *Arch Surg.* 2002;137:799-804.
12. Balthazar EJ. Appendicitis: prospective evaluation with high-resolution CT. *Radiol.* 1991;180:21-4.
13. Rao PM, Boland GWL. Imaging of acute right lower abdominal quadrant pain. *Clin Radiol.* 1998;53:639-49.
14. Horzic M, Salamon A, Kopljar M. Analysis of scores in diagnosis of acute appendicitis in women. *Coll Antropol.* 2005;29:133-8.
15. Nautiyal H, Ahmad S, Keshwani NK, Awasthi DN. Combined use of modified Alvarado score and USG in decreasing negative appendicectomy rate. *Indian J Surg.* 2010;72:42-8.
16. Rodriguez DP, Vargas S, Callahan MJ, Zurakowski D, Taylor GA. Appendicitis in young children: imaging experience and clinical outcomes. *Am J Roentgenol.* 2006;186:1158-64.
17. Macklin CP, Radcliffe GS, Merei JM, Stringer MD. A prospective evaluation of the modified Alvarado score for acute appendicitis in children. *Ann R Coll Surg Engl.* 1997;79:203-205.
18. Talukder DB et al. Modified Alvarado Scoring system in the diagnosis of acute appendicitis JAFMC, Bangladesh, Vol. 5, No. 1 (June) 2009.
19. Kailash Singh et al, Application of Alvarado Scoring System in Diagnosis of Acute Appendicitis Vol. 10, No. 2, April-June 2008.

20. Narendra JB, Vinayak T. Comparative study of modified alvarado score and ultrasonography in the diagnosis of acute appendicitis. IOSR Journal of Dental and Medical Sciences. 2016;15(8):14-7.
21. Anand Rao Internet Journal of Surgery, 2007.
22. Kansakar N, Agarwal PN, Singh R, Mishra A, Kumar J, Hadke NS, Sheth S. Evaluation of combined use of modified Alvarado score and Ultrasound in predicting acute appendicitis: a prospective study. Int Surg J 2018;5:3594-7.
23. Singh SK, Kunal C. Comparative study of diagnostic accuracy of modified Alvarado score and ultrasonography in acute appendicitis. IOSR-JDMS. 2014;13(1):36-40.
24. Shinji HIMENO et al. Ultrasonography for the Diagnosis of Acute Appendicitis Tokai J Exp Clin Med., Vol. 28, No. 1, pp. 39-44, 2003.
25. Raja AS, Wright C, Sodickson AD, Zane RD, Schiff GD, Hanson R, Baeyens PF, Khorasani R. Negative appendectomy rate in the era of CT: an 18-year perspective. Radiology. 2010 Aug;256(2):460-5.

UNDER PEER REVIEW

