

INCIDENCE, FREQUENCY AND MORPHOLOGY OF MENISCAL INJURY IN ACL TEAR

ABSTRACT

Background: ACL tear is the most commonly reported injury. It is almost always associated with intra articular injuries.

Objective: To assess the incidence, nature and pattern of meniscal tear in ACL injury and to find out the association with age and side of injury.

Methodology: A retrospective study was conducted among the patients who were admitted and treated for ACL tear in Saveetha Medical And College And Hospital over a 2-year period from August 2019-August 2021. There were about 52 patients admitted and treated for the same. The case record of each of the patients were reviewed to find the incidence of meniscal lesion in ACL tear using appropriate statistical tests.

Results: About 52 patients with ACL tear were reviewed in this study. ACL tear was most commonly reported in younger age group of 20-29 (46.15%). Out of which, 19(36.54%) patients had meniscal tears. About 9(47.37%) patients had lateral meniscus tear, 6(31.58%) had medial meniscus tear and 4(21.05%) had bilateral meniscal tear. It was seen that bucket handle injury (n=12) was the most common meniscus tear overall. Radial tear was most specifically common in bilateral meniscus injury(N=4) . We also found that age and she of the tear are independent factors to the meniscal tear(p value - not significant).

Conclusion: Meniscal tears are the most common intra articular lesions associated with

Comment [VS1]: How can there be about 52 patients? It has to be a definite number. Maybe author is not sure??

Comment [VS2]: What is this word?

Comment [VS3]: You have mentioned nothing other than minesc tear. What are the others??

ACL tear. It was most commonly reported in the age group of 20-29. We found that the incidence of lateral meniscal tear was significantly higher in the patients rather than medial meniscal tear. Bucket handle injury was the most commonly reported tear in meniscal injury.

Key words: Anterior crucial ligament tear, lateral meniscus injury, bucket handle tear

INTRODUCTION: The main role of meniscus is to evenly distribute impact forces through the knee and to maintain joint stability. A meniscus tear is usually caused by twisting or turning quickly. These tears can occur commonly while playing sports or lifting heavy weights and is common in young, active adults. Degenerative tears commonly occur in patients with osteoarthritis.

Meniscus tear can occur along-side with other ligamentous injury and it is commonly associated with ACL tear because of its anatomic and functional relationships to these structures. Isolated ACL tears are not common¹.

Comment [VS4]: Abbreviation needs expansion at least once

For maintaining long term joint function, especially in active patients, meniscal tissue and function should be preserved. Early repair of posterior horn of lateral meniscus has significant improvement in loading profile in lateral compartment and may help in prevention of damage of cartilage and osteoarthritis associated with partial meniscectomy^{1,2}

Comment [VS5]: This quote is out of place here. Not in context of the introduction

The purpose of this study is to document the frequency, morphology and commonest meniscal injuries accompanying anterior cruciate ligament tear

Methodology:

A retrospective study was conducted among the patients over a period of August 2019 – August 2021. The data was collected from the database of the Orthopaedics department of Saveetha Medical College And Hospital.

Inclusion criteria:

- Patient above 18 years of age
- Patients with multi-ligamentous injury
- Bilateral limb involvement

Exclusion criteria:

- Previous surgery involving partial meniscectomy
- Patients with previous surgery on the knee
- Patients with history of degenerative tear

The data and documents of the patients who met the inclusion and the exclusion criteria were studied. Not all patients operated were clinically positive for meniscus tear (valgus/varus stress test, Apley's grind test) but showed radiological evidence of meniscus tear. Surgical procedures were done under spinal anesthesia and diagnostic arthroscopy was done in each case to confirm the diagnosis intra-operatively. The site and type of meniscus repair was recorded.

During the study period, about 52 patients met the inclusion/ exclusion criteria which included 45 male patients and 7 female patients.

Statistical analysis

Statistics of descriptive data was calculated by standard formulas (arithmetic mean,

standard deviation, range, and frequency). All continuous variables are presented in terms of mean \pm standard deviation of the mean. Comparison between paired data and independent groups was performed using the Student's t-test. $P < 0.05$ was regarded as statistically significant. Statistical analysis was performed using the SPSS ver 10.0 software package.

Meniscal Tear Classification

In all patients, diagnostic arthroscopy was done to confirm the meniscal lesions. Tears were documented as lateral and medial meniscal tear which was further subdivided into anterior horn, posterior horn and body involvement. Types of meniscal tears were further classified as longitudinal tear, radial tear, horizontal tear, bucket handle tear and flap tear.

Results: Out of 52 patients reviewed in this study, it was found that about 19(36.54%)patients had meniscal injury along with ACL tear whereas 33(63.46%) patients had isolated ACL tear alone. Table 1 shows the demographic details of the patients. It was found that about 2(3.85%) patients in the age group of 10-19 , 17(32.69%) of age group 30-39 , about 7 (13.46%) in the age group of 40-49 and 3 (5.77%) in the age group of 50-59. The highest incidence of ACL tear about 23 (44.23%)was reported in the age group of 20-29. This shows us that ACL tear more common in younger age group. The ACL tear was most commonly reported in the right knee in about 38(73.07%) patients. About 13(25%) patients had ACL tear in left knee and about 1(1.93%) had

bilateral knee involvement.

Table 2 shows the site of the meniscal tear. The most commonly reported injury was located in the lateral meniscus which was seen in 9(47.37%) patients. In about 6 (31.58%) patients it was located in the medial meniscus and in 4(21.05%) patients both lateral and medial meniscus were located.

Table 3 shows the morphology of meniscal tears associated with ACL injury. The most commonly reported tear was the bucket handle tear. It was seen in about 12 patients which included 7 lateral meniscal tear and 5 medial meniscal tear. Radial tear was commonly reported in bilateral meniscal tear(4) and about 1 patient in lateral meniscal tear and 1 patient in medial meniscal tear. Flap tear was reported only in one patient with lateral meniscal tear.

Table 4 shows the association of meniscal tear with age and side of the injury. By using standard calculations, we found that these factors were not significant(p value was not less than 0.05). This shows that incidence of meniscal tear is age and side independent.

The patients with medial meniscal tear(6) underwent partial medial meniscectomy and bilateral meniscal tear patients (4) had underwent bilateral partial meniscectomy along with ACL reconstruction.

Discussion:

ACL is a band of connective tissue that courses from femur to tibia. It helps to keep the knee stable. ⁵ About 50% of ACL tears are most commonly associated with meniscal

tears.⁴ ACL tear is a common tear with an annual incidence ranging between 68.6 per 100,000 person years in the population. ACL is an important stabilizer of the knee joint. It

most commonly occurs with twisting of knee whilst weight bearing. An ACL tear typically will present with rapid joint swelling and significant pain. For clinical examination, Lachman test and Anterior drawer test would be performed.⁵ Diagnostic arthroscopy was done to confirm the ACL tear and concomitant meniscal injuries.

In our study we found that lateral meniscal injury(47.37%) were most commonly associated with ACL tear. Whereas in the study published by Jewell Brent Duncan et al., it was found that 141 (83%) patients had lateral meniscal injury whereas 29 (17%) patients had medial meniscal injury. The highest percentage of incidence of lateral meniscal injury reported in this study may be contributed due to the increased study population. The study also concluded that the triad of injury of ACL-MCL-Lateral meniscus was nine times more common than the triad of ACL-MCL-Medial meniscus tear.⁶⁹

The study conducted by Tetsuo Hagino et al., revealed that in acute ACL injury group, lateral meniscal injury was seen in about 129 knees(69.4%), medial meniscal injury in 20 knees(10.8%) and bilateral meniscal tears were found in 37 knees(24.7%). It was found that lateral meniscal tear was most common in acute ACL tear. In chronic ACL group, bilateral meniscal tear in 104 knees(41.4%) was most commonly reported. Whereas the lateral and medial meniscal tears were reported in about 85(33.9%) and 62(24.7%) knees respectively.⁷⁸

According to the study of Binfield et al., it was seen that bucket handle tear was most commonly seen in Meissen tear patients. It's reported higher in medial meniscal tear injury rather than lateral meniscus.^{10 11} In the study conducted by TestuoHagino et al., it was seen that bucket handle tear was observed in about 25 knees whereas in our study it was observed in about 12 knees.^{7 12} The study conducted by D.B.Lerner et al., suggest radial tears are commonly associated with medial meniscal tear.^{13 14} Where as in the study conducted by Wolf Peterson et al., it was concluded that radial tear was most common in involving both medial and lateral meniscus which went hand in hand with our study.^{15 16}

The patients underwent the procedure of ACL reconstruction with medial or lateral meniscectomy according to their diagnosis. Partial meniscectomy was done in all medial meniscal patients. And in bilateral meniscal tear patients bilateral meniscectomy.

Conclusion:

Like a lot of knee injuries meniscal tears can be painful and it is one of the most commonly occurring cartilage injury of knee. Certain cases it can be asymptotic and acl tear symptoms can be more dominating. ACL tear are often associated with other intra articular lesions and more commonly associated with meniscal tear. In some cases MRI does not give a clear finding on meniscal tear so in patients with acl tear during reconstruction the surgeons should be aware of such associated meniscal tear and plan accordingly.

Table 1: Sociodemographic details of the patients

PARAMETERS	VARIABLES	FREQUENCY N=52	PERCENTAGE
Age	10-19	2	3.85
	20-29	23	44.23
	30-39	17	32.69
	40-49	7	13.46
	50-59	3	5.77
Side of ACL tear	Right	38	73.07
	Left	13	25
	Bilateral	1	1.93
Meniscal Tear	Yes	19	36.54
	No	33	63.46

Table 2: Site of meniscal tear

Site	Frequency	N=19	Percentage
Lateral meniscus	9		47.37
Medial meniscus	6		31.58
Bilateral meniscus	4		21.05

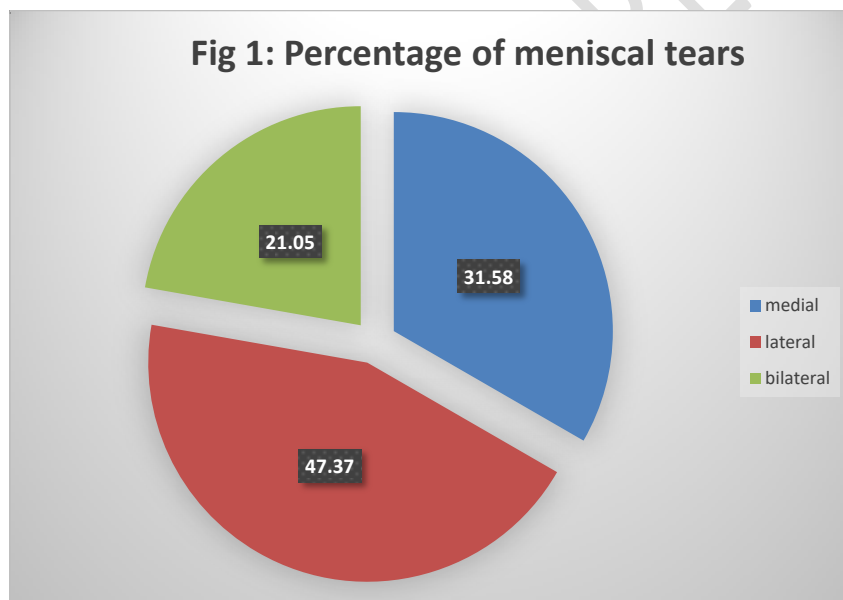


Table 3: Morphology of meniscal tears

Morphology	Lateral	Medial	Bilateral	Total
Bucket handle tear	7	5	-	12
Radial tear	1	1	4	6
Flap tear	1	-	-	1
Total	9	6	4	19

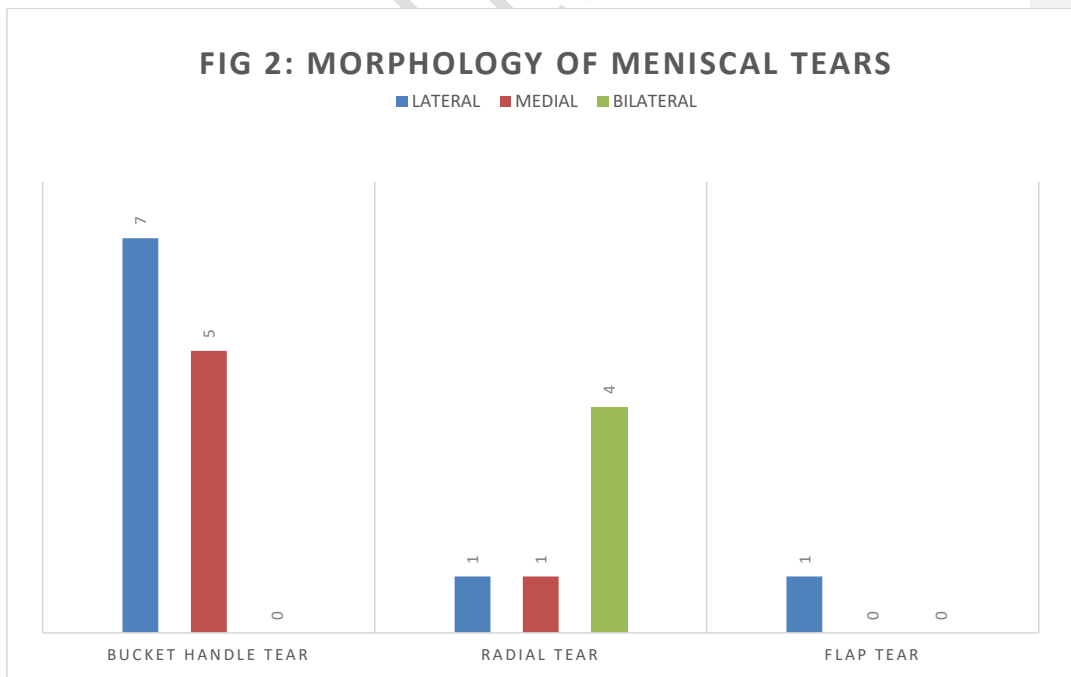


Table 4 : Association of Meniscal Tears

Parameters	Variables	Meniscal tear		Chi square	P value
		YES	NO		
Age	10-19	0	2	0.7007	0.951241
	20-29	10	13		
	30-39	5	12		
	40-49	3	4		
	50-59	1	2		
Side of tear	Right	15	20	1.8434	0.174555
	Left	4	13		

P value < 0.05 not significant

References:

1. Feucht MJ, Bigdon S, Bode G, Salzmann GM, Dovi-Akue D, Südkamp NP, Niemeier P. Associated tears of the lateral meniscus in anterior cruciate ligament injuries: risk factors for different tear patterns. *Journal of orthopaedic surgery and research*. 2015 Dec;10(1):1-8.

2. Mansori AE, Lording T, Schneider A, Dumas R, Servien E, Lustig S. Incidence and patterns of meniscal tears accompanying the anterior cruciate ligament injury: possible local and generalized risk factors. *International orthopaedics*. 2018 Sep;42(9):2113-21

3. Bisson LJ, Kluczynski MA, Hagstrom LS, Marzo JM. A prospective study of the association between bone contusion and intra-articular injuries associated with acute anterior cruciate ligament tear. *The American journal of sports medicine*. 2013 Aug;41(8):1801-7.

4. Matsumoto, H., Suda, Y., Otani, T., Niki, Y., Seedhom, B. B., Fujikawa, K. (2001). [Roles of the anterior cruciate ligament and the medial collateral ligament in preventing valgus instability](#). *J OrthopSci*, 6(1), 28-32.

5. Sanders TL, MaraditKremers H, Bryan AJ, Larson DR, Dahm DL, Levy BA, Stuart MJ, Krych AJ. Incidence of anterior cruciate ligament tears and reconstruction: a 21-year population-based study. *The American journal of sports medicine*. 2016 Jun;44(6):1502-7.

6. Duncan JB, Hunter R, Purnell M, Freeman J. Meniscal injuries associated with acute anterior cruciate ligament tears in alpine skiers. *The American journal of sports medicine*. 1995 Mar;23(2):170-2.

7. Hagino T, Ochiai S, Senga S, Yamashita T, Wako M, Ando T, Haro H. Meniscal tears associated with anterior cruciate ligament injury. Archives of orthopaedic and trauma surgery. 2015 Dec;135(12):1701

8. Bellabarba C, Bush-Joseph CA, Bach Jr BR. Patterns of meniscal injury in the anterior cruciate-deficient knee: a review of the literature. American journal of orthopedics (Belle Mead, NJ). 1997 Jan 1;26(1):18-23.

9. Arnold JA, Coker TP, Heaton LM, Park JP, Harris WD. Natural history of anterior cruciate tears. The American journal of sports medicine. 1979 Nov;7(6):305-13.

10. Binfield PM, Maffulli N, King JB. Patterns of meniscal tears associated with anterior cruciate ligament lesions in athletes. Injury. 1993 Sep 1;24(8):557-61.

11. Byrne L, King E, Mc Fadden C, Jackson M, Moran R, Daniels K. The effect of meniscal pathology and management with ACL reconstruction on patient-reported outcomes, strength, and jump performance ten months post-surgery. The Knee. 2021 Oct 1;32:72-9.

12. Anderson AF, Anderson CN. Correlation of meniscal and articular cartilage injuries in children and adolescents with timing of anterior cruciate ligament reconstruction. The American journal of sports medicine. 2015 Feb;43(2):275-81.

13. Lerer DB, Umans HR, Hu MX, Jones MH. The role of meniscal root pathology and radial meniscal tear in medial meniscal extrusion. *Skeletal radiology*. 2004 Oct;33(10):569-74.

14. Kenny C. Radial displacement of the medial meniscus and Fairbank's signs. *Clinical Orthopaedics and Related Research*. 1997 Jun 1;339:163-73.

15. Petersen W, Forkel P, Feucht MJ, Zantop T, Imhoff AB, Brucker PU. Posterior root tear of the medial and lateral meniscus. *Archives of orthopaedic and trauma surgery*. 2014 Feb 1;134(2):237-55.

16. Anderson L, Watts M, Shapter O, Logan M, Risebury M, Duffy D, Myers P. Repair of radial tears and posterior horn detachments of the lateral meniscus: minimum 2-year follow-up. *Arthroscopy: The Journal of Arthroscopic & Related Surgery*. 2010 Dec 1;26(12):1625-32.

UNDER PEER REVIEW