

A study on variation of origin of gastroduodenal artery

ABSTRACT

Aim

The aim of the study is to note the variation in the origin of Gastroduodenal artery (GDA).

In a study done on 30 cadavers at Seth G.S. Medical College and K.E.M. Hospital, Mumbai, India, during the period 2011–2012, it was found that there was a rare type of **branching pattern** of the gastroduodenal artery (GDA). The knowledge of variations is very important during the operative, diagnostic and endovascular procedures. Variations in the branching pattern of the cystic artery often occur and may be encountered during cholecystectomy or laparoscopic cholecystectomy and hepatobiliary surgeries. This study describes unusual origin of cystic artery from the gastro duodenal artery as found during routine dissection in a cadaver. The embryological development and clinical importance of such a variation have been emphasized.

Keywords: Gastro-duodenal artery, Cystic artery, Cholecystectomy, Hepatobiliary surgery

INTRODUCTION

The gastroduodenal artery emerges posterior and superior to the first part of the duodenum from the common hepatic artery. At the lower boundary of the first part of the duodenum, it gives rise to the right gastroepiploic and superior pancreaticoduodenal arteries.

It runs between the initial half of the duodenum and the pancreas' neck, just to the right of the peritoneal reflection from the duodenum's posterior side. It is normally to the left of the main bile duct, however it might be anterior on occasion. It separates into the right gastroepiploic and superior pancreaticoduodenal arteries at the lower border of the first half of the duodenum. The artery's lowest part gives rise to small branches that supply the pyloric end of the stomach and the pancreas, as well as retroduodenal branches that directly supply the first and proximal portions of the second parts of the duodenum. Although the gastroduodenal artery normally arises from the common hepatic artery, it can also **develop from a trifurcation of the right and left hepatic arteries**, the superior mesenteric artery or the left hepatic artery (rarely), or the coeliac axis or right hepatic artery (rarely).

The gastroduodenal artery frequently develops behind the upper border of the first part of the duodenum and supplies the superior aspect of the first part. **1**

Cystic artery usually arises from the right hepatic artery. During hepatobiliary surgeries and cholecystectomy, uncontrolled bleeding from the cystic artery and its branches is a serious problem that may occur due to inadvertent damage to the vessel due to unknown variation. Due to bleeding laparoscopic cholecystectomy may get converted to open cholecystectomy. It is said that anatomical variations in the hepatic arterial supply are due to variant embryological development of the ventral arteries of the foregut and failure of these vessels to regress.^{2, 3, 4}

A complete knowledge of these variations in branching pattern is clinically important in liver transplantation, cholecystectomy, hepato biliary surgeons and also for radiologists. Variations in the origin of cystic artery may predispose to iatrogenic injury during surgical procedures.

Materials and methods:

30 embalmed cadavers were meticulously dissected in the department of anatomy, Seth GSMC, Mumbai. Coeliac trunk was dissected and branches of coeliac trunk were traced. Common hepatic artery and its branches were followed and origin of gastroduodenal was traced and variations in origin were noted.

RESULTS

During dissection of 30 embalmed cadavers at Seth G.S. Medical College and K.E.M. Hospital, Mumbai, it was found that gastro duodenal artery was originating from common hepatic artery in 29 (96.66%) cases but in 1 (3.33%) case gastro duodenal artery arose from right hepatic artery. Common hepatic artery (CHA) originated from coeliac trunk which later divided into right and left hepatic artery. Gastroduodenal artery originated from right hepatic artery (RHA). RHA then went on to supply the liver and it also formed Moynihan's hump. While cystic artery originated from gastroduodenal artery outside the Calot's triangle and it then did ascend upwards to supply gall bladder. Right hepatic artery did not give any branch to gall bladder in the Calot's triangle. (Fig)

This is a very rare case where gastroduodenal and cystic arteries had variation in origin.

DISCUSSION

There are many classifications of variations of celiac and hepatic artery. Most commonly used is Michels et al who has classified the anomalies into ten types.⁵

Song et al. described series of celiac and hepatic artery variations in 5002 patients using CT scan and digital subtraction angiography.⁶

Anson found out that the cystic artery (CA) originates from right hepatic (63%), hepatic trunk (26%), left hepatic (5%), gastroduodenal (2%), superior pancreaticoduodenal (1%), right gastric (1%), coeliac trunk (1%) and superior mesenteric (1%) artery. A study done by Harris & Pellegrini, found that the right hepatic artery was the main contributor (75%) and few case it was

originated from the left hepatic artery ($6\pm 2\%$), hepatic artery proper ($2\pm 2\%$), common hepatic artery ($0\pm 6\%$), superior pancreatico-duodenal artery ($0\pm 2\%$) and the superior mesenteric artery.⁷

In a study by Sarkar & Roy (2000) the CA originated from the gastroduodenal artery in 1 case out of 96 cases.⁸

During development, the extrahepatic biliary system arises from an intestinal diverticulum, which carries a rich supply of vessels from the aorta, coeliac trunk and superior mesenteric artery. Later most of these vessels are absorbed, leaving in place the mature vascular system. As the pattern of absorption is highly variable, it is not unusual for the cystic artery and its branches to derive from any other artery in the vicinity.⁹⁻¹¹

The preferred method of gall bladder removal is laparoscopic cholecystectomy. The surgeon must have a detailed anatomical understanding of the probable changes in the anatomy of the cystic artery and its branches during laparoscopic cholecystectomy since dissection of a limited field is magnified on the video monitor. The cystic artery that arises outside the hepatobiliary triangle usually passes ventral to the common hepatic duct, and in some cases it may even be inferior to the cystic duct, making it the first structure encountered during laparoscopic dissection of the inferior border of the hepatobiliary triangle, with the risk of injury. It is self-evident that closure of a cystic artery too close to the common hepatic duct would jeopardise it.¹²⁻¹⁵

CONCLUSION

Knowledge of such variation has surgical importance and requires special attention in gallbladder surgeries as well as pancreatic surgeries and also helps the radiologist to perform an intraoperative cystic angiogram during hepatobiliary surgery.

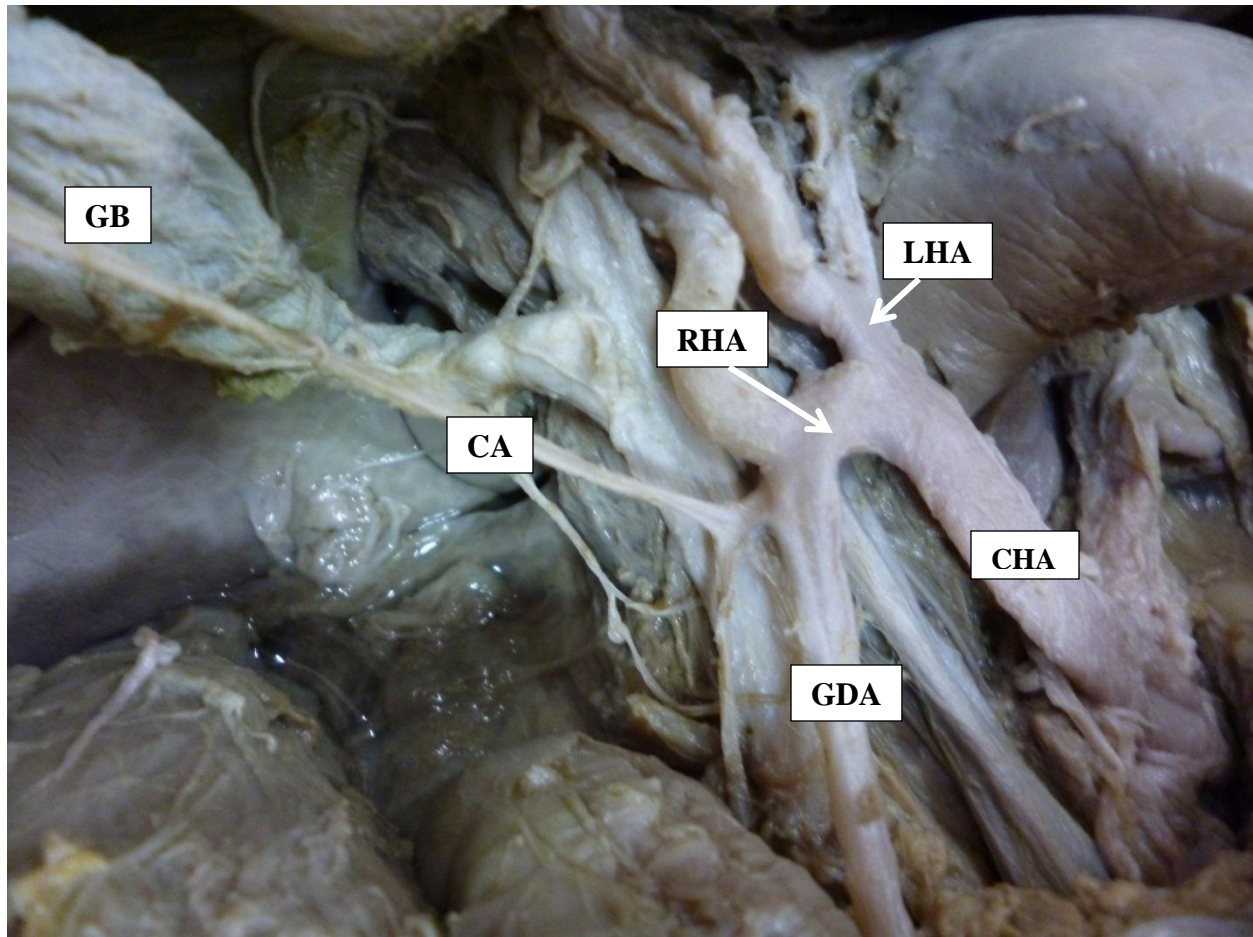


Figure 1: Origin of GDA from RHA and Origin of CA from GDA (GDA=Gastroduodenal artery, RHA=Right Hepatic Artery, CHA=Common Hepatic Artery, LHA=Left Hepatic Artery, CA= Cystic artery, GDA=Gastroduodenal artery, GB= Gall bladder)

REFERENCES

1. Standing S, ed. Gray's Anatomy: The Anatomical Basis of Clinical Practice. 40th Ed., Edinburgh, Elsevier Churchill Livingstone. 2008; 1169–1170.
2. Chen H, Yano R, Emura S, Shoumura S. Anatomic variation of the celiac trunk with special reference to hepatic artery patterns. *Ann Anat.* 2009; 191: 399–407.
3. Jr, B. F. P. ., & Federico R. Tewes. (2021). What attorneys should understand about Medicare set-aside allocations: How Medicare Set-Aside Allocation Is Going to Be Used to Accelerate Settlement Claims in Catastrophic Personal Injury Cases. *Clinical Medicine and Medical Research*, 2(1), 61-64. <https://doi.org/10.52845/CMMR/2021v1i1a1>

4. Hiatt JR, Gabbay J, Busuttil RW. Surgical anatomy of the hepatic arteries in 1000 cases. *Ann Surg.* 1994; 220: 50–52.
5. Kemeny MM, Hogan JM, Goldberg DA, et al. Continuous hepatic artery infusion with an implantable pump: problems with hepatic arterial anomalies. *Surgery.* 1986; 99:501-4.
6. Daniel, V., & Daniel, K. (2020). Perception of Nurses' Work in Psychiatric Clinic. *Clinical Medicine Insights, 1*(1), 27-33. <https://doi.org/10.52845/CMI/2020v1i1a5>
7. Michels NA. Newer anatomy of the liver and its variant blood supply and collateral circulation. *Am J Surg.* 1962; 112:337-47.
8. Song SY, Chung JW, Yin YH, Jae HJ, Kim HC, Jeon UB, et al. Celiac axis and common hepatic artery variations in 5002 patients: systematic analysis with spiral CT and DSA. *Radiology* 2010; 255:278–88.
9. Daniel, V. ., & Daniel, K. (2020). Diabetic neuropathy: new perspectives on early diagnosis and treatments. *Journal of Current Diabetes Reports, 1*(1), 12–14. <https://doi.org/10.52845/JCDR/2020v1i1a3>
10. Anson, B. H. The aortic arch and its branches. In *Cardiology*. New York, McGraw-Hill, 1963. V. 1. p.119.
11. Sarkar, A. K. & Roy, T. S. Anatomy of the cystic artery arising from the gastroduodenal artery and its choledochal branch-a case report. *J. Anat.*, 197(3):503-6, 2000.
12. Nowak, M. Variation of the cystic artery in man. ~~Variation of the cystic artery in man~~. *Folia Morphologica*, 36(2):89-98, 1977.
13. Daniel, V., & Daniel, K. (2020). Exercises training program: It's Effect on Muscle strength and Activity of daily living among elderly people. *Nursing and Midwifery, 1*(01), 19-23. <https://doi.org/10.52845/NM/2020v1i1a5>
14. Hugh, T. B.; Kelly, M. D. & Li, B. Laparoscopic anatomy of the cystic artery. *Am. J. Surg.*, 163(6):593-5, 1992.
15. Scott-Conner, C. H. & Hall, T. J. Variant arterial anatomy in laparoscopic cholecystectomy. *Am. J. Surg.*, 163(6):590-2, 1992.