

## MUCORMYCOSIS IN POST COVID-19 PATIENTS

### ABSTRACT

**INTRODUCTION:** Acute respiratory ~~distress syndrome illness~~ (ARDS) is a common complication of severe pneumonia virus, such as the flu and COVID-19, which requires critical treatment, including asthma support, corticosteroids, and other treatments to prevent acute respiratory ~~tract~~ inflammation. Although steroid treatment is limited to the treatment of viral pneumonia, it is usually a double-edged sword, putting patients at the same level as second-line ~~therapy for invasive~~ fungal infections (IFIs), leading to increased morbidity and mortality. Mucormycosis is a fungal emergency with a high ~~proclivity~~ ~~tendency~~ for ~~contiguous~~ ~~contaguous~~ spread and a poor prognosis if not detected and treated promptly. Mucormycosis is believed to be caused by uncontrolled diabetes mellitus (DM) and other immunosuppressive disorders, such as corticosteroid therapy.

**AIM:** Mucormycosis in Post ~~COVID~~ ~~Covid~~-19 Patients

**CONCLUSION:** COVID-19 is ~~linked~~ ~~correlated with to~~ a high rate of secondary infections, both bacterial and fungal, most likely as a result of immune dys-regulation. Furthermore, the widespread use of steroids, ~~monoclonal antibodies~~, and broad-spectrum antibiotics as part of the COVID-19 ~~armamentarium~~ ~~remedy~~ can result in the production or exacerbation of pre-existing fungal diseases. Physicians should be mindful of the likelihood of invasive secondary fungal infections in patients with COVID-19 infection, especially in those that have pre-existing risk factors, and should be able to detect and treat these infections early ~~in order to~~, reducing mortality and morbidity.

**KEYWORDS:** ~~mucormycosis~~ *Mucormycosis*, *Apophysomyces elegans*, Immunosuppression, DM, Second-line fungal ~~infections~~ ~~therapy~~ and Corticosteroid therapy

### INTRODUCTION

As our country fights ~~with~~ COVID-19, the issue of post COVID-19 sepsis has become such a significantly huge problem that India bears the dubious distinction of being both

**Comment [D1]:** Where is the abstract? It should added

**Formatted:** Font: (Default) +Headings, 12 pt, Not Bold, Font color: Auto, Pattern: Clear

**Comment [D2]:** This sentence is not clear, please rewrite it

**Comment [D3]:** Explain the aim, without rewriting the title again please

**Formatted:** Font: Bold

**Formatted:** Font: Italic

**Formatted:** Font: Bold

the mucormycosis as well as ~~the diabetes 'capital' of the world's capital of diabetes.~~<sup>[1]</sup> [1]

Considering the severity of mucormycosis, it is not wise to put it among other general fungal infections as the disease is spreading at an alarming rate in post ~~eovid~~-COVID patients in India. Indian mucormycosis has a few distinguishing characteristics. The most common ~~symptom~~-signs is rhino-orbito-cerebral presentation, which is linked to uncontrolled diabetes.—Mucormycosis sometimes is known as the diabetes-defining illness, and remains one of the most devastating complications in uncontrolled diabetics. As a rare but severe fungal infection, it usually affects those with weakened immune systems, such as cancer patients, those with severe diabetes, or those who have undergone multiple organ surgeries. Chronic diabetics with severe foot ulcers should exercise extreme caution, as harmful external particles laden with dirt can easily enter the body through the injured skin tissues. [2] As it is now showing in several COVID post-recovery cases, it reflects how COVID infection affects our immune system deeply.

Mucormycosis, previously termed as zygomycosis, is a rare fungal ailment, born out of mucormycete mould, that occurs extensively in soil, leaves, decayed wood and putrefied manure, *Apophysomyces elegans* and *Rhizopus homothallicus* are emerging species and uncommon agents such as *Mucor irregularis* and *Thamnostylum lucknowense* are also being discovered.[3]

Its infection starts in the nasal area, throat, and then soon spreads to the eyes, brain, and finally, the entire body. It also spread through cut wounds and skin. Once the ~~eovid~~-COVID patients inhale these fungal spores and ingest it into their systems, they can have a very lethal and life-threatening infection as this fungus is quite ~~Angioinvasive~~angioinvasive, meaning that it is a predilection or preference for the blood vessels. As it enters the blood vessels, it induces necrosis of the tissue and vessels, resulting in a lack of blood flow to the tissues. As a result, the patient can develop an aggressive infection, necessitating treatment with an antifungal and/or surgical debridement, which may result in tissue or organ death, potentially leading to higher mortality rates. [4]

It becomes life-threatening until it infects a patient's brain. Its high rate of dissemination aggravates the patient's condition, and if left unchecked or untreated at the appropriate time, it can lead to multiple organ failure. In the meantime, the patient's immunity is eroded, other infections are aggravated, and the patient becomes infection-

Formatted: Font: Italic

Formatted: Font: Italic

Formatted: Font: Italic

Formatted: Font: Italic

Formatted: Font: Italic

Formatted: Font: Italic

Formatted: Font: Italic

Formatted: Font: Italic

prone, lowering the patient's survival rate dramatically. The connection between COVID-19 and ~~Mucormycosis~~ ~~mucormycosis~~ is not unexpected to us since the most common cause of ~~Mucormycosis~~ ~~mucormycosis~~ is uncontrolled diabetes, which is also a high-risk factor for COVID-19. Furthermore, steroids, which inhibit immunity, are the only drug that has been shown to reduce COVID-19 mortality. Therefore it is the combination of COVID-19, usage of steroids leading to suppressed immunity which probably predispose a patient to ~~Mucormycosis~~ ~~mucormycosis~~. [5]

One major and observed cause of ~~Mucormycosis~~ ~~mucormycosis~~ in post COVID patients is due to the fulfillment of the adequate amount of O<sub>2</sub> requirements which is met by high FiO<sub>2</sub> and along with a high pressure. If sustained conditions given above persist, it causes destruction and degradation of the mucosal membrane or MALT (mucosal associated lymphoid tissue). This exposes the epithelium below which results in fine injuries which are not visible to naked eye. The fungal spores entering the respiratory track directly take entry into ~~our~~ blood stream and rapidly multiply. Thus, post COVID patients are more prone towards Mucormycosis.

Due to immunosuppression the host becomes susceptible to a large variety of bacterial, fungal or viral infections. In the beginning, characteristic symptoms of mucormycosis affect only the part of the body through which the fungus invades the system and the tissues that it eventually occupies. But, as the infection spreads to various tissues and organs, multiple types of indications are shown by the affected person such as [6]

- 1) The patient will have Fever followed by persistent cough.
- 2) The patient will have nasal discharge of blood and mucous.
- 3) The patient may suffer from Stuffy nose. [7]
- 4) The patient may suffer from Proptosis (abnormal protrusion of the eyeball).
- 5) The patient may experience Ptosis (weakness of eyelid muscle).
- 6) The patient may suffer from Periorbital swelling.
- 7) The patient may have impaired vision.
- 8) The patient may develop ~~Complete-complete~~ blindness.
- 9) The patient may suffer through ~~Hemieranial-hemicranial Pain~~ ~~pain~~. [8]
- 10) The patient may go through ~~Complete-complete~~ headache.

**Comment [D4]:** All numerical references in the text should be checked before writing full stop

**Formatted:** Subscript

**Formatted:** Subscript

- 11) The patient may develop ~~Swelling~~ swelling of gums.
- 12) The patient may have ~~Loosening~~ loosening of teeth.
- 13) The patient may suffer from toothache.
- 14) Altered mentation.
- 15) The patient may experience Drowsiness.
- 16) Intracranial parenchymal involvement. [9]

#### **CASE STUDY**

A 60-year old male patient who is diabetic, hypertensive since last 10 years was diagnosed and treated for COVID-19 ~~and~~ SARS-CoV2-COV2 and ~~discharged-left from the~~ hospital. After ~~discharge-that~~, the patient noted left eye redness with irritation with left nostril congestion. Symptoms were progressive and noted periorbital edema, blurred vision in left eye, left sided headache with bloody mucous discharge from left nostril. Patient consulted to ENT (~~Ear, Nose and Throat~~) specialty in ~~seven star hospital SEVEN STAR HOSPITAL~~ where he was advised ~~Computerized Tomography (CT) scan of the~~ Paranasal Sinuses (CT-PNS) and ophthalmologist opinion. Ophthalmologist seen the patient and noted his findings. It suggested of left eye lid edema, proptosis of left eye, restriction of eye ball movement with impaired vision. Left eye fixed and non-reactive pupil.

CT PNS suggested of moderate mucosal thickening with abnormal soft tissue involving left maxillary sinus, left ethmoid sinus suggested of Sinusitis. This patient was referred to tertiary care ~~centerecenter~~ where Nasal Endoscopic diagnosis and treatment was possible. ENT surgeon did Nasal Endoscopy suggested of Extensive Invasive fungal Sinusitis. Patient was advised to go under Endoscopic Radical Debridement with left orbital decompression. Prior surgery opinion of Retina specialist was taken, there was drastically decrement of vision with involvement of Lateral, Medial Rectus muscle with almost ~~completelycompletely~~ fixed eye. Neuro physician's opinion was taken and Magnetic resonance imaging (MRI) ~~MRI~~ of brain was performed to check involvement of brain/Infra Cranial Extension. MRI brain suggestive of no evidence of intracranial involvement/extension. As patient is 60 year old and known case of Diabetes Mellitus and Hypertension. Cardiologist's opinion and bed side 2D ECHO done. ECHO suggested LVEF 60percent, no RCOMA, ~~Gradeand Grade~~--1 Diastolic Dysfunction.

Formatted: Font: Bold

Formatted: Font: (Default) +Headings, 12 pt, Font color: Auto, Pattern: Clear

Formatted: Font: (Default) +Headings, 12 pt, Not Bold, Font color: Auto, Pattern: Clear

Formatted: Font: Not Bold

~~Nephrologist's~~Nephrologist's opinion was taken, advised adequate hydration and daily KFT. Mild to moderate risk to undergo surgery.

CBC – HB 11.2gm%, TLC 16400, Platelets 2.63Lac

KFT- Sr Creat 1.4mg/Dl, Urea 51mg/Dl, Sr Na 136mEq/L , Sr K 3.9mEq/L

Urine R& M- Albumin 1+, -Pus cells absent

PCT- -1.23

CRP- -58

D dimer- -1202

X-ray Chest- -PA Bilateral lower zone consolidation

Coagulation profile- -Within normal range

HIV- -Negative

HCV- -Negative

HBSAg- -Negative

■ IV antibiotic Piperacillin tazobactam 4.5mg IV TDS, IV Liposomal amphotericin started from 250mg OD (ACCORDING TO NEW GUIDELINES FOR MUCORMYCOSIS THE DOSE IS 250mg/DAY FOR 50KG PERSPON, 5mg/Kg/day). IV Pantosid 40, capsule Posaconazole 300mg OD, IV Tramadol for pain management, IV Paracetamol for additional pain management and other supportive medications that consists of vitamins and trace elements. The patient was supported with IV fluid at the rate of 80ml/hour. Patient was diabetic so his sugar was controlled according to his random blood sugar level. Fractional doses of HAI (human actrapid insulin)

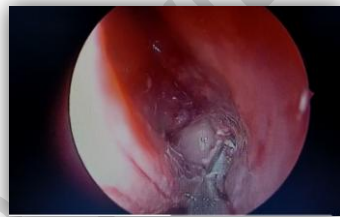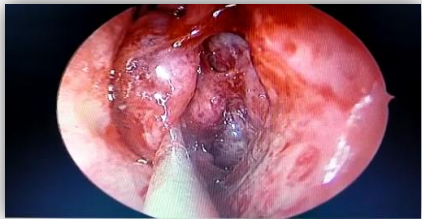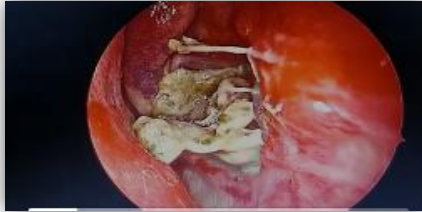■ given. Patient posted for surgery next day. Patient kept NBM for 12 hours prior surgery.

IV fluid was given on next morning with all due high risk consent under general anesthesia Endoscopic radical ~~debridement~~debridement with Left orbital decompression done with ethmoidectomy.

Formatted: Font: (Default) +Headings, 12 pt

Formatted: Indent: Left: -0.05", Bulleted + Level: 1 + Aligned at: 0.28" + Indent at: 0.53"

Formatted: Font: (Default) +Headings, 12 pt



Nasal cavity packed with antiseptic and haemostatic solution. During surgery, biopsy and pus was collected and sent for histopathology and microscopy examination suggestive of filamentous fungal hyphae suggestive of mucormycosis. This patient improved symptomatically after surgery. From post of day to edema, swelling, redness of eye decreased but vision was not improves. It was as previous as before the surgery. Again nasal endoscopy done and surgical syringing and flushing done known as nasal clearance. Endoscopy suggestive of no active fungal invasion, granulation of tissue seen. This patient was admitted for 14 days in [SEVEN-seven stars STAR](#)-hospital for IV antibiotic, antifungal doses under Physician's and Nephrologists' guidance. There was slight increase in his serum creatinine from 1.4mg/Dl to 1.8mg/Dl hence IV antifungal and antibiotic doses were titrated according to creatinine clearance. Adequate hydration maintained, RBS was tightly controlled with fractional doses of HAI (HUMAN ATRAPID INSULIN). On 15<sup>th</sup> day of hospitalization, patient discharged in haemodynamically stable condition. Patient was advised follow-up every week for nasal clearance

## DISCUSSION

- The novel Coronavirus has already swallowed up more a million lives worldwide. Absence of an effective vaccine or antiviral therapy in such tremendous situations, supportive care plays a vital role in the management of this disease. Glucocorticoids and remdesivir are the only drugs proven to be beneficial in this disease.[16] However, glucocorticoids may increase the risk of secondary infections. Moreover, the immune dysregulation caused by the virus and the use of concurrent immunomodulatory drugs such as tocilizumab could further increase the risk of infections in Corona in patients. The corona virus infection might affect and alter the immune system by affecting T lymphocytes, particularly CD4+ and CD8+ T cells, which usually are highly involved in the pathological process of ~~Covid~~ COVID infection.[10] This drastic decrease of lymphocytes, especially T-cells, as seen in the most serious ~~COVID Covid~~ cases, is linked to the worst outcomes and puts patients at a higher risk of contracting opportunistic infections like ~~Mucormycosis~~ mucormycosis. Mucormycosis is a fungal infection caused by the ~~mucormycetes~~ *Mucormycetes*, a group of fungal molds.[17] While bronchial alveolar macrophage dysfunction is the most common cause of fungal infection, T-cells have been identified as a component of the adaptive immune system. Mucorales-specific T-cells (CD4+ and CD8+) were shown to be active against Mucorales by developing cytokines such as IL-4, IL-10, IL-17, and IFN-, which were able to specifically destroy Mucorales hyphae in a study on a group of mucormycosis patients. It's possible that lymphopenia increases the chance of invasive mucormycosis, while increasing lymphocyte numbers improves the adaptive immune system and induces the development of Mucorales-specific T-cells, which could help regulate the invasive infection. [11]

Mucormycosis is more prevalent in immunocompromised patients. In particular, a new systematic study by Jeong et al. found that solid organ transplantation and neutropenia, which is generally seen in patients with haematological malignancies, were the only independent risk factors for pulmonary mucormycosis. (12) Furthermore, SARS-CoV-2 infection can alter the immune system, and this is the first case of opportunistic *Rhizopus* spp co-infection involving lungs with severe parenchymal injury. In a retrospective

Formatted: Font: Italic

Formatted: Font: Italic

report, Koehler et al. looked at a population of COVID-19 patients who had mild to extreme acute respiratory distress syndrome (ARDS) and experienced intrusive pulmonary aspergillosis as a result of the immune-paralysis caused by SARS-CoV-2 infection. Similarly, no corticosteroids or immunosuppressive drugs were used in this situation, but the patient had an extreme type of COVID-19 with multiple organ dysfunctions and a major and long-term lymphopenia with a change in the N/L ratio. [13] Following that, it's possible that SARS-CoV-2 infection could cause an immunosuppressive condition, putting the patient at risk of infections like mold. These infections are often linked to the worst outcomes, especially when the immune system response does not improve. [14] However, once the immune system has recovered, opportunistic infections can be managed, as shown by the present case, which showed an increase in clinical symptoms, especially respiratory dysfunction. [20] As lymphocytes increased and the N/L ratio reduced, and the pulmonary cavitory lesion opened into the pleural room, the patient's oxygenation improved dramatically. Surgical exploration to extract necrotic lesions should be considered to cure the mould infection and increase the patient's result, even if the molds could not be separated in the pleural effusion. [15] In addition to systemic antifungal therapy, the European Confederation of Medical Mycology Mucormycosis Guidelines highly recommends early surgical treatment to remove infectious tissue (either by local debridement or full resection). [16] Infections, such as the mold infection seen in this instance, should be examined as a possible causative agent when clinical effects do not change after wide-spectrum observational therapy or when a compromised immune response caused by SARS-CoV-2 is detected. [19] As a result, antifungal agents should be used in antimicrobial therapy, and pharmacological medication should be combined with surgical action to eliminate mold-associated necrotic lesions wherever possible where results indicate a mucormycosis. [20-24]

## CONCLUSION

COVID-19 is linked to a high rate of secondary infections, both bacterial and fungal, most likely as a result of immune dysregulation. Furthermore, the widespread use of steroids, monoclonal antibodies, and broad-spectrum antibiotics as part of the COVID-19

armamentarium can result in the production or exacerbation of pre-existing fungal diseases. Physicians should be mindful of the likelihood of invasive secondary fungal infections in patients with COVID-19 infection, especially in those that have preexisting risk factors, and should be able to detect and treat these infections early, reducing mortality and morbidity. The use of therapeutic agents should be closely supervised in order to produce the best possible therapeutic outcome at the lowest possible dosage and for the shortest possible time. The use of broad-spectrum antibiotics should be reconsidered, particularly in the absence of infection.

Acknowledgement: SEVENSTAR HOSPITAL, Director Dr. Shailesh Kothalkar MBBS MS ENT, Head and Neck Surgeon Dr. Nilesh Bhange and Dr. Piyush Shembekar

**Comment [D5]:** Please check the name of the hospital and follow the same spilling in whole text

#### **COMPETING INTERESTS DISCLAIMER:**

Authors have declared that no competing interests exist. The products used for this research are commonly and predominantly use products in our area of research and country. There is absolutely no conflict of interest between the authors and producers of the products because we do not intend to use these products as an avenue for any litigation but for the advancement of knowledge. Also, the research was not funded by the producing company rather it was funded by personal efforts of the authors.

#### **REFERENCES**

1. Prenissl J, Jaacks LM, Mohan V, et al. Variation in health system performance for managing diabetes among states in India: a cross-sectional study of individuals aged 15 to 49 years. *BMC Med* 2019; 17:92.
2. International Diabetes Federation. [Jul;2020 ]; <https://idf.org/our-network/regions-members/south-east-asia/members/94-india.html> 2020
3. [Chen N, Zhou M, Dong X, et al.](#) Epidemiological and clinical characteristics of 99 cases of 2019 novel coronavirus pneumonia in Wuhan, China: a descriptive study. [Chen N, Zhou M, Dong X, et al.](#) *Lancet*. 2020;395:507–513. [[PMC free article](#)] [[PubMed](#)] [[Google Scholar](#)]
4. Buran, T., Sanem Gökçe Merve Kılınç, & Elmas Kasap. (2020). Prevalence of Extraintestinal Manifestations of Ulcerative Colitis Patients in Turkey: Community-Based Monocentric

**Comment [D6]:** Reference style should be homogenous, is the journal name is italic or not? Please check all the references

**Formatted:** Font: Bold

Observational Study. *Clinical Medicine and Medical Research*, 1(2), 39-46. <https://doi.org/10.52845/CMMR/2020v1i2a8>

5. Farmakiotis D, Kontoyiannis DP. Mucormycoses. *Infect Dis Clin North Am*. 2016;30:143-163. <https://www.ncbi.nlm.nih.gov/pubmed/26897065>

6. ~~Rawson TM, Moore LSP, Zhu N, et al.~~ Bacterial and fungal co-infection in individuals with coronavirus: a rapid review to support COVID-19 antimicrobial prescribing. ~~Rawson TM, Moore LSP, Zhu N, et al.~~ *Clin Infect Dis*. 2020;[Epub ahead of print]:0. [PMC free article] [PubMed] [Google Scholar]

7. Clinical management protocol for COVID-19. [Jul;2020];<https://www.mohfw.gov.in/pdf/ClinicalManagementProtocolforCOVID19.pdf> 2020

8. Daniel, V. ~~and~~, & Daniel, K. (2020). Diabetic neuropathy: new perspectives on early diagnosis and treatments. *Journal of Current Diabetes Reports*, 2020, 1(1), 12–14. <https://doi.org/10.52845/JCDR/2020v1i1a3>

9. ~~Horby, P., Landray, M.J., Haynes, R., et al.~~ Dexamethasone in hospitalized patients with COVID-19 - preliminary report. The RECOVERY Collaborative Group. *New Engl Med*. 2021 25;384(8):693-704.2020;[Epub ahead of print] [PMC free article] [PubMed] [Google Scholar]

10. COVID-19 Treatment Guidelines Panel. Coronavirus disease 2019 (COVID-19) treatment guidelines. National Institutes of Health. [Jul;2020];<https://www.covid19treatmentguidelines.nih.gov/> 2020

11. Daniel, V., & Daniel, K. (2020). Perception of Nurses' Work in Psychiatric Clinic. *Clinical Medicine Insights*, 2020, 1(1), 27-33. <https://doi.org/10.52845/CMI/2020v1i1a5>

12. Liu J, Li S, Liu J, et al. Longitudinal characteristics of lymphocyte responses and cytokine profiles in the peripheral blood of SARS-CoV-2 infected patients. *EBioMedicine*. 2020;55:102763.

13. Daniel, V., & Daniel, K. (2020). Exercises training program: It's Effect on Muscle strength and Activity of daily living among elderly people. *Nursing and Midwifery*, 2020, 1(01), 19-23. <https://doi.org/10.52845/NM/2020v1i1a5>


Formatted: Font: Not Italic

Formatted: element-citation, Font: (Default) +Headings, 12 pt, Font color: Black, Pattern: Clear

14. Potenza L, Vallerini D, Barozzi P, et al. Mucorales-specific T cells emerge in the course of invasive mucormycosis and may be used as a surrogate diagnostic marker in high-risk patients. *Blood*. 2011;118:5416–9.
15. Lim S, Bae JH, Kwon HS, et al. COVID-19 and diabetes mellitus: from pathophysiology to clinical management. *Nat Rev Endocrinol* 2021; 17:11–30.
16. Chakrabarti A, Kaur H, Savio J, et al. Epidemiology and clinical outcomes of invasive mould infections in Indian intensive care units (FISF study). *J Crit Care* 2019; 51:64-70.
17. [Bartoletti M, Pascale R, Cricca M, et al.](#) Epidemiology of invasive pulmonary aspergillosis among COVID-19 intubated patients: a prospective study. [Bartoletti M, Pascale R, Cricca M, et al.](#) *Clin Infect Dis*. 2020;[Epub ahead of print]:0. [[PMC free article](#)] [[PubMed](#)] [[Google Scholar](#)]
18. [Song G, Liang G, Liu W.](#) Fungal co-infections associated with global COVID-19 pandemic: a clinical and diagnostic perspective from China. ~~Song G, Liang G, Liu W.~~ <https://www.ncbi.nlm.nih.gov/pmc/articles/PMC7394275/> *Mycopathologia*. 2020;185:599–606. [[PMC free article](#)] [[PubMed](#)] [[Google Scholar](#)]
19. [Hanley B, Naresh KN, Roufousse C, et al.](#) Histopathological findings and viral tropism in UK patients with severe fatal COVID-19: a post-mortem study. ~~Hanley B, Naresh KN, Roufousse C, et al.~~ *Lancet Microbe*. 2020;[Epub ahead of print] [[PMC free article](#)] [[PubMed](#)] [[Google Scholar](#)]
20. Arastehfar A, Carvalho A, van de Veerdonk FL, Jenks JD, Koehler P, Krause R, et al. COVID-19 associated pulmonary aspergillosis (CAPA)-from immunology to treatment. *J Fungi (Basel)*. 2020;6(2):91.
21. ~~Group WHOEAFC-TW,~~ Sterne JAC, Murthy S, Diaz JV, Slutsky AS, Villar J, et al. Association between administration of systemic corticosteroids and mortality among critically ill patients with COVID-19 a meta-analysis. *JAMA*. 2020;324(13):1330–13341.
22. Kimmig LM, Wu D, Gold M, Pettit NN, Pitrak D, Mueller J, et al. IL-6 inhibition in critically ill COVID-19 patients is associated with increased secondary infections. *Front Med (Lausanne)*. 2020;7:583897.
23. Placik DA, Taylor WL, Wnuk NM. Bronchopleural fistula development in the setting of novel therapies for acute respiratory distress syndrome in SARS-CoV-2 pneumonia. *Radiol Case Rep*. 2020;15(11):2378–81.

24. Bassetti M, Bouza E. Invasive mould infections in the ICU setting: complexities and solutions. *J Antimicrob Chemother.* 2017;72:i39-47.

REVIEW



UNDER PEER REVIEW

