

Dilated cardiomyopathy (DCM) a rare case report in infant. cause? primary carnitine deficiency (PCD).

Comment [MV1]: Suggestion: Dilated cardiomyopathy (DCM) in an infant due to primary carnitine deficiency (PCD). A rare case.

Abstracts

Introduction: Dilated cardiomyopathy (DCM) is known to have ventricular dilatation and dysfunction in myocardium. Primary carnitine deficiency (PCD) is a not common but a reversible autosomal recessive phenomenon with supplementation of carnitine. Case presentation- 11-month male child was brought with complain of fever, cough, cold since 7 days and increased work of breathing for 15 days. 2 D echo was done suggestive of dilated cardiomyopathy. His initial investigations; chest Xray revealed significant cardiomegaly electrocardiography, (ECG) showed prolonged QT interval fraction. Patient was treated with syrup carnitine empirically by cardiologist as we did not have facilities for fatty acid oxidation profile. Repeated 2D echocardiogram (2 D ECHO) was suggestive of recovery.

Comment [MV2]: The patient was treated with carnitine syrup empirically, as there was no way to determine a fatty acid oxidation profile.

Conclusions: Carnitine deficiency could be the cause of cardiomyopathy and so treatment of carnitine supplementation can be considered empirically to avoid life-threatening complication related to cardiomyopathy.

Key words: Restrictive cardiomyopathy, hypertrophic cardiomyopathy, fatty acid oxidation profile, cardiomegaly.

Introduction

Childhood myopathy of heart is an uncommon disease. It is classified into three variants, dilated, hypertrophic, and restrictive. Type of cardiopathy with ventricular dilatation (DCM) is a diverse group of heart muscle disorder presented by heart chamber dilatation and distorted heart muscle function leading to cardiac failure. The estimated incidence of dilated cardiomyopathy is 36.5 per 100,000 children¹.

Etiology of DCM can be divided into primary and secondary. Primary is congenital in origin and generally it is because of genetic mutation. Secondary causes is associated with viral infections, metabolic and genetic diseases. It can be secondary to malnutrition, ingestion of drugs and toxins^{2,3}. Tachycardia, increase in respiration during feeding, failure to thrive, breathlessness is some of common presentation seen in DCM. Rarely patient may present with pulmonary oedema or arrhythmias³. It is seen that DCM affects first year of life more commonly, males are affected more than female. An epidemiological study done in Finland by Arcola *et al.*, estimated case load of this cardiac disease in male child to be 0.34/1,00,000/year. At the end of 10 years study period the prevalence was estimated to be 26/1,00,000⁴.

Deficiency of carnitine which one is primary (PCD) is a very uncommon genetic disease. Affected gene is not dominant leading to its presentation rarely one in more than one lakh births. Etiology of this hereditary disorder is due to mutations in the SLC22A5 gene, this gene is belong to chromosome 5q23.3. It is not properly understood that why few patient doesn't manifest clinically as a heart disease. Deficiency of carnitine (CD) will lead to cardiac dysfunction like cardiomyopathy and arrhythmias. It is possible to reverse cardiac dysfunction by just adding carnitine supplementation⁵.

Comment [MV3]: Use space between words or between numerals and measurements.

We thus thought of presenting this rare case of dilated cardiomyopathy infant, who recovered due to carnitine supplementation.

Case ~~presentation~~ report

++ Eleven month male child was brought with complain of fever, cough, cold since 7 days and increased work of breathing for 15 days. As narrated by mother the child was apparently alright 15 days back then she noticed increase work of breathing and fever which was moderate grade, not associated with chills and rigors relived on taking medicine. Fever was associated with cough. There was history of poor/interrupted feeding. Patient was taken to local practitioner where child received inj. tazobactam in view of pneumonia. 2d echo was done suggestive of dilated cardiomyopathy with Left ejection ventricular fraction (15 – 70 mm) with mild MR with dilated left atrium and left ventricle. This patient was later referred to present hospital for further management. On examination, patient was having heart rate around 150/minute, tachypnea with respiratory rate (RR) was 50/minute and blood pressure measured to be 80/64 mmHg. Pulse oximeter shows slight hypoxemia (saturation of oxygen 92% on room air). Hence supplementary oxygen added to maintain saturation. The baby was having 6.8 kg weight, its length was 68.8 cm and normal head circumference (44.8 cm). On systemic examination of cardiovascular system heart sound were normal. Apex was at fifth intercostals space, midclavicular line. Peripheral pulses found to be normal. There was no evidence of radio femoral delay. Pulmonary auscultation reveals basal crepitation. No evidence of organomegaly on per abdominal examination. Central nervous system (CNS) examination was normal. Probable diagnosis was septicaemia. Hence baby was undergone culture examination of body fluids like blood, urine and cerebrospinal fluid but turn out to be sterile. Vitamin D and test for thyroid profile was done which was in normal range. His initial investigations; chest X-Ray revealed significant cardiomegaly (see Fig.1) electrocardiography (ECG) showed prolonged QT interval, and 2D echocardiogram (2D

ECHO) showed confluent pulmonary arteries, right pulmonary artery (RPA) - 5.4 mm, Left pulmonary artery (LPA) - 4.8 mm, suggestive of dilated left and right ventricle EF, ejection fraction (EF) 35% (Fig. 2). Treatment was given in the form of antibiotics (piperacillin, and vancomycin), intravenous fluid, oxygen. Later on antibiotics were omitted as cultures were found to be sterile. Initial treatment of tab enalapril, aspirin, digoxin drops and furosemide drops was started. After 3 days on this treatment there was no improvement in symptoms and 2D ECHO showed EF 35% so syrup carnitine was added empirically by cardiologist as we did not have facilities for fatty acid oxidation study and acylcarnitine profile. Repeated 2D echocardiogram suggest recovery of myocardium with EF of 45% then to 60% (day eight, day fifteen after admission). Patient was hospitalised (hospitalized) for 1 month and discharged on syrup carnitine. Patient was called after 15 days for follow up. On follow up, patient gained weight, asymptomatic, ECHO was done which show normal cardiac function with EF of 72%. Patient is advised to follow up every 1month hence onwards.

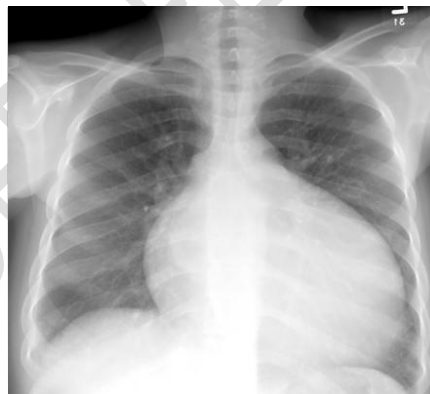


Figure 1- CXR (PA view) shows cardiomegaly

Comment [MV4]: The figures have been reduced.

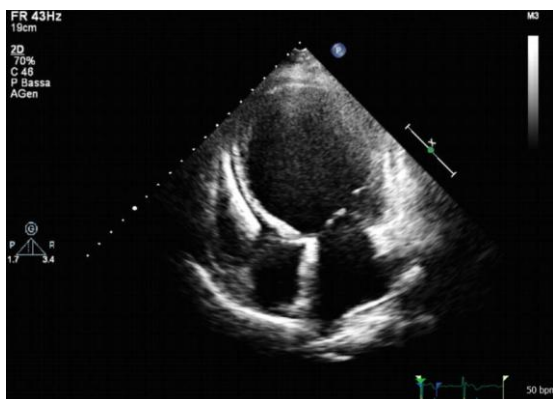


Figure 2. 2D ECHO shows dilated right and left ventricles

Discussion

Present patient initially received furosemide, digoxin, angiotensin converting enzyme inhibitors for management of DCM which is as per guidelines suggested by many studies [7,8,10-13](#). As above treatment did not improve symptoms of DCM, empirically carnitine was started as investigation for fatty acid oxidation study and acylcarnitine profile was not available. Present child responded well to carnitine supplementation. One study was conducted by Wang *et al.*, included series of six children with PCD. All these patient have significant left ventricular failure. He reported cure in all six patient after supplementation of carnitine for one month¹⁵. ~~N-L~~ Tang *et al.*, observe in a 2-year, organic cation/carnitine transporter (OCTN2) deficient female child who presented with high grade dilated left ventricular failure due myopathy, which improved after carnitine supplementation¹⁶. Another study done by ~~Xiyu-Fang~~ Yang, showed the inability of the heart to maintain adequate circulation was improved after carnitine supplementation¹⁷. Perin ~~F~~ *et al.*, in their study showed that a dilated cardiomyopathy cause due to carnitine deficiency was improved after oral supplementation with L-carnitine.¹⁸. These above studies and case reports shows that carnitine therapy has succeeded in reversing life-threatening cardiomyopathy.

Comment [MV5]: these

Conclusion:

Pediatrician should keep in mind that carnitine deficiency could be the cause of cardiomyopathy and so treatment of carnitine supplementation can be considered empirically, even if their centers have no facilities available for diagnosis of L- carnitine level to avoid life-threatening complication related to cardiomyopathy.

References

1. Richardson P, McKenna W, Bristow M, Maisch B, Mautner B, O'Connell J, *et al.* Report of the 1995 World Health Organization/International Society and Federation of Cardiology Task Force on the Definition and Classification of cardiomyopathies. *Circulation*. 1996; 93:841–2.
2. Lipshultz SE, Sleeper LA, Towbin JA, Lowe AM, Orav EJ, Cox GF, *et al.* The incidence of pediatric cardiomyopathy in two regions of the United States. *N Engl J Med*. 2003;348:1647–55.
3. Nugent AW, Daubeney PE, Chondros P, Carlin JB, Cheung M, Wilkinson LC, *et al.* The epidemiology of childhood cardiomyopathy in Australia. *N Engl J Med*. ????
4. El-Menyar AA, Bener A, Numan MT, Morcos S, Taha RY, Al-Suwaidi J. Epidemiology of idiopathic cardiomyopathy in Qatar during 1996-2003. *Med Princ Pract*. 2006;15:56–61.
5. L. Fu, M. Huang, and S. Chen, "Primary carnitine deficiency and cardiomyopathy," *Korean Circulation Journal*, vol. 43, no. 12, pp. 785–792, 2013.
6. ~~Ahmad S Azhar, Towbin, AL Jarallah, Riyaz et al.~~ Idiopathic dilated cardiomyopathy (IDCM) is a severe illness with high mortality in the pediatric population. *Journal of natural science, biology and medicine*, Year : 2013, Volume 4, Issue : 1, Page : 145–148 DOI: 10.4103/0976-9668.107279

Comment [MV6]: Suggestion:
The case report showed that we should consider carnitine deficiency as a cause of dilated cardiomyopathy and, therefore, indicate its empirical supplementation, provided that we are unable to diagnose this rare deficiency.

Comment [MV7]: Keep the Vancouver style as in this reference. Is corrected !

Comment [MV8]: Ok!

Comment [MV9]: 2013; 43(12): 785-792.

7. Burch M, Siddiqi SA, Celermajer DS, Scott C, Bull C, Deanfield JE. Dilated cardiomyopathy in children: Determinants of outcome. Br Heart J. 1994;72:246–50.
8. ~~Rajesh Domkunti, Yashwant R. Lamture, Avinash Rinait, Dilip Gode~~ . Breast carcinoma in axillary tail of spence: a rare case report, Int J Cur Res Rev (July 2020), 12 (14) (Special Issue) ;92-95.
9. ~~YR Lamture, B Salunke~~, carcinoma of breast- a study profile, journal of evolution of medical and dental sciences-JEMDS (2018)7 (45), 4857-4861
10. ~~Avinash Rinait, Lamture Y.R., P. Prateek, Dilip Gode~~. A prospective study of aetiology and clinical presentation of gastric adenocarcinoma, Indian Journal of Forensic Medicine & Toxicology, ~~October-December~~ 2020, 14(4),6241-6245.
11. ~~Dr D Rajesh, Dr Y R Lamture~~. A study on the correlation between endoscopic findings and symptoms of gastro-esophageal reflux disease (GERD). Journal of critical reviews 2019, 6(6), 860-864 <https://dx.doi.org/10.31838/jcr.06.06.145>
11. ~~Yashwant R. Lamture, Rajesh Domkunti, Avinash Rinait, Mangesh Padmawar~~. Enterocutaneous fistula in an operated case of total abdominal hysterectomy: a rare case report. Journal of critical reviews 2020, 7(8), 1085-88.
12. ~~Yashwant R. Lamture, Gode Dilip, Dr. Aditya Mundada~~, A rare case report of isolated tuberculous caecal perforation presented as acute appendicitis. Indian Journal of Forensic Medicine & Toxicology, ~~October-December~~ 2020, 14(4),6233-6236.
13. Lipshultz SE, Sleeper LA, Towbin JA, Lowe AM, Orav EJ, Cox GF, *et al.* The incidence of pediatric cardiomyopathy in two regions of the United States. N Engl J Med 2003;348:1647-55.
14. ~~S. S. Wang, J. Rao, Y. F. Li, Z. W. Zhang, and G. H. Zeng~~. “Primary carnitine deficiency cardiomyopathy,” International Journal of Cardiology, vol. 174, no. 1, pp. 171–173, 2014.

Comment [MV10]: Remove Hiperlink

15. ~~N L Tang I, V Ganapathy, X Wu, J Hui, P Seth, P M Yuen, R J Wanders, T F Fok, N M Hjelm,~~ . Mutations of OCTN2, an organic cation/carnitine transporter, lead to deficient cellular carnitine uptake in primary carnitine deficiency, *Hum.mol.genetics*. 1999 ~~Apr~~;8(4):655-60. doi: 10.1093/hmg/8.4.655.

16. ~~Xiu Fang Yang, Guo Sheng Liu And Bing Yi.~~ Primary carnitine deficiency in two sisters with intractable epilepsy and reversible metabolic cardiomyopathy: Two case reports .*Experimental And Therapeutic Medicine* 20: 118, 2020. DOI: 10.3892/etm.2020.9246

17. Perin F, Rodríguez- Vázquez Del Rey MD, Carreras- Blesa C, Arrabal- Fernández L, Jiménez- Jáimez J and Tercedor L: Dilated cardiomyopathy with short QT interval suggests primary carnitine deficiency. *Rev Esp Cardiol (Engl Ed)* 71: 1074- 1075, 2018.

UNDER PEER REVIEW