

UNUSUAL CASE OF HEAD INJURY PRESENTED WITH BRAIN GLIOMAS

Abstract

7 years female child came with parents who gave us history that 1 month back, child during playing had fall on face and lost consciousness which remained for 30 min followed by convulsion. On examination patient was conscious, responds to command, vitals were stable, aphasia was present, pupils were equal and reactive to light bilaterally and horizontal gaze was restricted. There was no facial weakness, Tone increase more in left upper and lower limb. Deep tendon reflexes (DTR) increase in left side. plantar reflex were extensors. MRI was done which shows intra axial space occupying lesion in brainstem with expansion of brainstem with hydrocephalus. Pt was inoperable and ventriculoperitoneal shunt was done for hydrocephalus. Post operatively patient was kept on assisted ventilation.

Comment [T1]: In discuss is 10 years old

Conclusion. Unusual presentation of brainstem gliomas as head injury.

Comment [T2]: adjust to the conclusion

Keywords- hydrocephalus, space occupying lesion, ventriculoperitoneal shunt

Introduction

Glioma arising from brain stem are of glial pathology and these are primary tumor's of brain¹.

In paediatric age group gliomas are of two categories. One is diffuse intrinsic pontine gliomas (DIPG) DIPG is having worst prognosis as it is a rapidly progressive growth and it arises from part of midbrain commonly in pons. DIPG is difficult to manage and has a less possibility of cure as it is a diffuse type of neoplasm and have tendency to infiltrate surrounding brain parenchyma affecting vital centers controlling respiration and heart. Other is a focal brain stem glioma. It is having

relatively better prognosis as it grows with slow speed and not affect pons .also it not spreading in diffusely².

Brain stem gliomas that are present in the region of the brain stem, which is the area of aqueduct of Sylvius and the fourth ventricle. Gliomas of the ventral pons are diffuse infiltrative, high grade extremely aggressive cancers can lead to death in less than a year. This also involve the adjacent brain structures beyond the pons. In tectal lesions, hydrocephalus occurs due to the ventricular compression.³

The usual clinical manifestation of these brain tumours (gliomas) is in the form of gradual progression of focal neurologic deficit , this neurologic deficit predominantly observed as muscle paresis. Followed by clinical manifestation suggestive increased intracranial pressure consisting of headaches, nausea and vomiting, and cognitive impairment. Convulsions is also not uncommon presentation mode⁴.

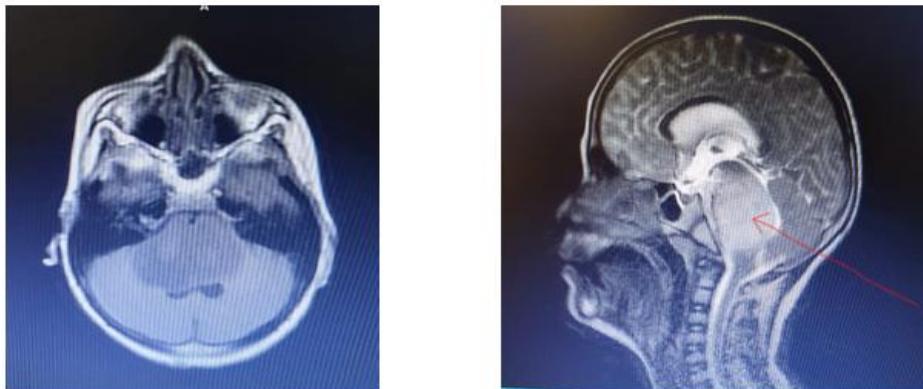
Treatment of brain stem gliomas depend upon different options like radiotherapy and chemo therapy and surgery. Also, treatment recommendation depend upon the signs and symptoms of the disease that the tumor is worsening.⁵ After extensive search in literature it was revealed that only 3 cases of glioma located in the brainstem has been reported ⁶. We therefore present unique case of it in childhood diagnosed with glioma of the brainstem.

Case presentation 10 years female child came with parents who gave us history that 1month back, child during playing had fall on face and lost consciousness which remained for 30 min followed by convulsion which was generalized tonic-clonic type remained for 5min, one episode , subsided on its own .They took the patient to private practitioner where symptomatic treatment for pain was given. She was advised to refer to higher center but due to financial problem parents kept patient at home. Parents noticed that after 48 hours of fall patient could not lift her left leg and she could

Comment [T3]: In abstract is 7 years old

not speak properly. Since last 15 days patient also developed dysphagia and so they decided to shift the patient to higher center.

On examination patient was conscious, responds to command, vitals were stable, aphasia was present, pupils were equal and reactive to light bilaterally and horizontal gaze was restricted. There was no facial weakness, Tone increase more in left upper and lower limb. Deep tendon reflexes (DTR) increase in left side. plantar reflex were extensors. MRI was done which shows intra axial space occupying lesion in brainstem with expansion of brainstem and causing mild mass effects over inferior cerebellar tonsils and fourth ventricles causing mild hydrocephalus. It shows hyperintense signal on T2W1 and Hypointense signal on T1W1. It shows mild patchy enhancement on post contrast study. Feature suggestive of brainstem glioma. According to neurosurgeon it was diffuse inoperable tumor type so resection of tumor was not possible and they option for VP shunting as CT scan shows dilated ventricles due to hydrocephalus.



Comment [T4]: Figure 1.....

Figure 1 coronal and sagittal section of MRI brain shows intra axial space occupying lesion in brainstem with expansion of brainstem and causing mild mass effects over inferior cerebellar tonsils and fourth ventricles causing mild hydrocephalus. It shows hyperintense signal on T2W1 and

Hypointense signal on T1W1. It shows mild patchy enhancement on post contrast study. Feature suggestive of brainstem glioma.

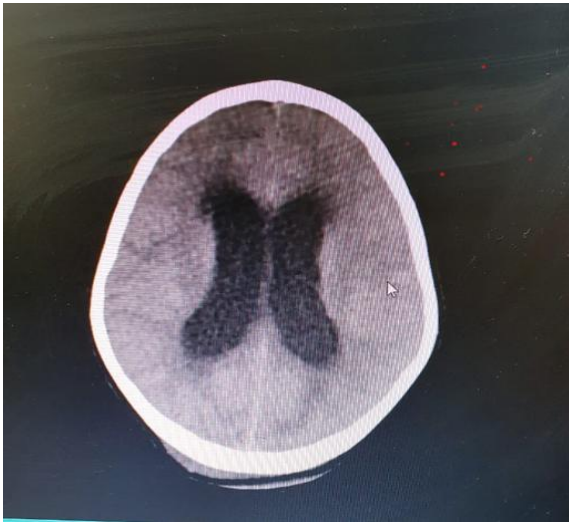


Figure 2. CT scan shows dilated ventricles due to hydrocephalus.

Postoperative patient was kept on ventilator and Arterial blood gas (ABG) analysis shows respiratory acidosis with no compensation. Patient is on ventilator with bad prognosis explained to parents.

Discussion-

Gliomas are rare in children. There are many studies^{6,7} showing common location of gliomas in supratentorial sites within central nervous system. In our patient site was on intra axial space occupying lesion in brainstem. recent evidences observed by researchers of Washington University School of Medicine located at St. Louis describes hypothesis behind certain behavior of brain neoplasm. it is a retinoblastoma protein (RB) that decreases the risk of neoplasm in brain. This RB is found less in amount in a male brain parenchyma hence it can explain incidence of brain tumour is more common in males⁸. contrary to this theory present case belongs to female

gender. ~~Kristin J. Weaver, MD et al⁹~~ reported two children suffering from angiocentric gliomas of brainstem which is similar to present case.

Comment [T5]: Accord to citation style

~~Covington et al⁴⁶ in 2009 reported~~ five years old female child with disturbed gait having history of repeated fall while walking. on investigations and careful clinical examination found to have hydrocephalous secondary to mid brain neoplasm. which needed ventriculoperitoneal shunt which was similar to our case. ~~Sophia F. Shakur, B.S. et al¹¹~~ in there case series of patient of angiocentric glioma found that convulsive disorder was as the most common presentation which is similar to present case study. ~~Subhasis Mishra et al¹²~~ studied in there case report on gliomas shows clinical feature as headache which was followed by an episode of seizure and hemiparesis which was similar to present case. as per evidence of many randomized controlled trials(RCT) adjuvant chemotherapy is having promising role in a management of high grade gliomas (HGGs) in children. These studies also suggest very minimal efficacy of surgery and radiotherapy in reducing early deaths^{13,14,15,16}. Our patient was not advised for surgery, chemotherapy or radiations. Unfortunately treatment was palliative and symptomatic essentially. Hence a extensive research on this neoplasm is required so that effective tools or chemotherapy may be invented to cure this grave cancer^{17,18,19}.

Comment [T6]: Just write on citation

Comment [T7]: Accord to citation style

Comment [T8]: Follow the author guidelines

Conclusion . Unusual presentation of brainstem gliomas which needs better understanding and treatment to improve quality of life and good prognosis.

Comment [T9]: Add the short explanation about the unusual presentation on this case.

Reference

Comment [T10]: Check the author guidelines for case report

1. Guilliams K, Wainwright MS. Pathophysiology and management of moderate and severe traumatic brain injury in children. *J Child Neurol.* 2016 Jan. 31(1):35-45.
2. Laghari AA, Baig MZ, Bari E, Darbar A, Mushtaq N, Hani Abdullah UE. Pediatric Brainstem Gliomas: An Institutional Experience. *Asian J Neurosurg.* 2019 Nov 25;14(4):1144-1150. doi: 10.4103/ajns.AJNS_101_19. eCollection 2019 Oct-Dec.
3. Reddy AT, Wellons JC. Pediatric high-grade gliomas. *The Cancer Journal.* 2003;9:107-12. 10.1097/00130404-200303000-00006 [PubMed] [Google Scholar]

4. Yashwant R. Lamture, Gode Dilip, Dr. Aditya Mundada, A rare case report of isolated tuberculous caecal perforation presented as acute appendicitis. *Indian Journal of Forensic Medicine & Toxicology*, October-December 2020, 14(4),6233-6236.
5. Leach JL, Roebker J, Schafer A, Baugh J, Chaney B, Fuller C, Fouladi M, Lane A, Doughman R, Drissi R, DeWire-Schottmiller M, Ziegler DS, Minturn JE, Hansford JR, Wang SS, Monje-Deisseroth M. MRI imaging features of diffuse intrinsic pontine glioma and relationship to overall survival: report from the International DIPG Registry. *Neuro Oncol*. 2020 Nov 26;22(11):1647-1657. doi: 10.1093/neuonc/noaa140.
6. Ni HC, Chen SY, Chen L, Lu DH, Fu YJ, Piao YS: Angiocentric glioma: a report of nine new cases, including four with atypical histological features. *Neuropathol Appl Neurobiol* 41:333–346, 2015
7. Artico M, Cervoni L, Celli P, Salvati M, Palma L. Supratentorial glioblastoma in children: a series of 27 surgically treated cases. *Childs Nerv Syst*. 1993;9:7–9. 10.1007/BF00301926 [PubMed] [Google Scholar]
8. Ober C, Loisel DA, and Gilad Y, Sex-specific genetic architecture of human disease. *Nat Rev Genet*, 2008. 9(12): p. 911–22.
9. Kristin J. Weaver, MD, PhD,¹ Lexi M. Crawford, BS,¹ Jeffrey A. Bennett, MD,² Marie L. Rivera-Zengotita, MD,³ and David W. Pincus, MD, PhD¹ .Brainstem angiocentric glioma: report of 2 cases .*Neurosurg Pediatr* 20:347–351, 2017
10. Covington DB, Rosenblum MK, Brathwaite CD, Sandberg DI: Angiocentric glioma-like tumor of the midbrain. *Pediatr Neurosurg* 45:429–433, 2009
11. Sophia F. Shakur, B.S.¹, Matthew J. McGirt, M.D.¹, Michael W. Johnson, M.D. Peter .Angiocentric glioma: a case series. *J. Neurosurg Pediatr*. 2009 March ; 3(3): 197–202. doi:10.3171/2008.11.PEDS0858.
12. Subhasis Mishra, Ashis Patnaik, Saroj Kumar Das Majumdar, Dillip Kumar Parida. Glioblastoma multiforme in a pediatric child Year : oncology journal of india, 2018 ; Volume : 2 : Issue : 2 | Page : 38-40

13. Pollack IF. The role of surgery in pediatric gliomas. *J Neuro-Oncol.* 1999;42:271–88.
10.1023/A:1006107227856 Quigley MR, Maroon JC. The relationship between survival and the extent of the resection in patients with supratentorial malignant gliomas. *Neurosurgery.* 1991;29:385–9. 10.1097/00006123-199109000-00008 [PubMed] [Google Scholar]
14. Hess KR. Extent of resection as a prognostic variable in the treatment of gliomas. *J Neuro-Oncol.* 1999;42:227–31. 10.1023/A:1006118018770 [PubMed] [Google Scholar]
15. Rajesh Domkunti, Yashwant R. Lamture, Avinash Rinait, Dilip Gode Breast carcinoma in axillary tail of spence: a rare case report, *Int J Cur Res Rev (July 2020), 12 (14) (Special Issue) ;92-95*
DOI: <http://dx.doi.org/10.31782/IJCRR.2020.9295>
16. YR Lamture, B Salunke, carcinoma of breast- a study profile, *journal of evolution of medical and dental sciences-JEMDS (2018)7 (45), 4857-4861*
DOI: 10.14260/jemds/2018/1082
17. Avinash Rinait, Lamture Y.R., P. Prateek, Dilip Gode, A prospective study of aetiology and clinical presentation of gastric adenocarcinoma, *Indian Journal of Forensic Medicine & Toxicology,* October-December 2020, 14(4),6241-6245.
18. Dr D Rajesh, Dr Y R Lamture. A study on the correlation between endoscopic findings and symptoms of gastro-esophageal reflux disease (GERD). *Journal of critical reviews* 2019, 6(6), 860-864 <https://dx.doi.org/10.31838/jcr.06.06.145>
19. Yashwant R. Lamture, Rajesh Domkunti, Avinash Rinait, Mangesh Padmawar. Enterocutaneous fistula in an operated case of total abdominal hysterectomy: a rare case report. *Journal of critical reviews* 2020, 7(8), 1085-88
DOI: <http://dx.doi.org/10.31838/jcr.07.08.227>

UNDER PEER REVIEW