

# ***Annona muricata* L. suppresses Stannous Chloride effects through changing hematological parameters in male New Zealand white rabbits.**

Comment [H1]: Zealand or Zealand?

## **ABSTRACT**

**Background:** *Annona muricata* L has a wide range of therapeutic characteristics and is frequently used in traditional medicine to treat a variety of ailments. Stannous Chloride ( $\text{SnCl}_2$ ) are widely used in daily life and distributed in many tissues and nutrients. Although over-ingestion of  $\text{SnCl}_2$ , can cause health problems, relatively little attention has been given to the toxic effects of this compound in livestock health and hematological parameters. This study was designed to study protective roles of *A. muricata* L. against  $\text{SnCl}_2$  effects through alleviating hematological disturbances in adult male New-Zealand white rabbits.

Comment [H2]: Any reason for the upper case?

**Materials and Methods:** Four rabbits per group were assigned to 1 of 4 treatment groups: 0 mg *A. muricata* and 0 mg  $\text{SnCl}_2/\text{kg}$  BW (control); 100 mg of *A. muricata* /kg BW; 20 mg  $\text{SnCl}_2/\text{kg}$  BW; 20 mg  $\text{SnCl}_2$  plus 100 mg of *A. muricata* /kg BW. Rabbits were orally administered the respective doses every other day for 10 weeks.

Comment [H3]: State what this group received. Any distilled water, placebo or ehicle?

**Results:** The obtained results showed that *A. muricata* alone caused increase in body weight, relative weight of liver, lung, heart and kidney. It also caused increase hemoglobin (Hb), packed cell volume (PCV) level and number of platelets (PLT) compared to control. However, treatment with *A. muricata* was caused significant decrease in white blood cell counts (WBCs) and non-significant decrease in red blood cell counts (RBCs), mean cell volume (MCV). Meanwhile, treatment with  $\text{SnCl}_2$  was lead to adverse effect on the body weight and relative organs weight practically spleen. It was caused significant increase in WBCs, MCV compared to control. The rest of hematological parameters (RBCs, PCV, PLT, Hb and MCHC) were significantly decreased, which indicated to cause anemia. Previous parameters were returned to normal values in group that treatment with *A. muricata* plus  $\text{SnCl}_2$ . In term of bone marrow smear, all smears are similar in terms of numbers and types of cells.

Comment [H4]: Expunge pls

Comment [H5]: Expunge pls

Comment [H6]: Expunge pls

Comment [H7]: treated

**Conclusion:** Results of the present study convincingly demonstrated that  $\text{SnCl}_2$  exposure resulted in varying degree of hematological parameters of rabbits. *A. muricata* has been promise as nutritional supplements to help prevent disorders involving  $\text{SnCl}_2$  induced these effects. Thus *A. muricata* may be helpful to combat  $\text{SnCl}_2$  associated sufferings in human as well as animal.

Comment [H8]: degrees

Comment [H9]:  $\text{SnCl}_2$ -induced effects

Comment [H10]: sub

**Keywords:** *A. muricata*,  $\text{SnCl}_2$ , hematological parameters, and New-Zealand white rabbits

## **1. INTRODUCTION**

Tin can combine with chemicals like chlorine, sulfur, or oxygen to form inorganic tin compounds (i.e., Stannous Chloride, Stannous Sulfide, Stannic Oxide). These compounds

are used in toothpaste, perfumes, soaps, food additives and dyes. It can also combine with carbon to form organo tin compounds (i.e., dibutyltin, tributyltin, triphenyltin), which are used to make plastics, food packages, plastic pipes, pesticides, paints, and pest repellents [1]. Tin (II) Chloride, also known as Stannous Chloride ( $\text{SnCl}_2$ ), is a white crystalline solid with the formula  $\text{SnCl}_2$ . It forms a stable dihydrate, but aqueous solutions tend to undergo hydrolysis, particularly if hot.  $\text{SnCl}_2$  is widely used as a reducing agent (in acid solution), and in electrolytic baths for tin-plating [2]. Humans are exposed to  $\text{SnCl}_2$  present in packaged food, soft drinks, biocides, dentifrices, etc. A number of studies have focused on the toxic effects of  $\text{SnCl}_2$  due to the fact that it has been extensively used for the production of food cans and beverage packaging [2, 3]. Exposures to environmental stressors including toxic chemicals that have the potential of modulating the immune system can often be linked to ecologically relevant endpoints, such as reduced resistance to disease [4]. It has immuno-suppressive effects *in vivo* and *in vitro* [5].  $\text{SnCl}_2$  induced a dose-dependent increase in the micronuclei frequency in peripheral erythrocytes of adult zebrafish [6]. Likewise, Janssen et al. [7] who investigated the effect of  $\text{SnCl}_2$  and they found that hemoglobin decreased significantly. While, Chmielnicka et al. [8] determined the effect of  $\text{SnCl}_2$  on heme biosynthesis in rabbits. The activities of  $\delta$ -aminolevulinic acid dehydratase ( $\delta$ -ALA) in the whole blood, free erythrocyte protoporphyrins, urine  $\delta$ -aminolevulinic acid ( $\delta$ -ALA-U) and coproporphyrin (CP-U) were decreased by about 80 % [8]. De Groot et al. [9] studied the role of  $\text{SnCl}_2$  mixed in the diet for 4 weeks and found that hemoglobin content of erythrocytes was reduced in rats. A dose related in hemoglobin concentration was noted in rats after oral treatment with inorganic tin ([7]. Medicinal plants are plants that generally contain constituents that have been found useful for the treatment and management of both animal and human diseases [10]. (Many folk remedies from plant origin are tested for its potential antioxidant in experimental animal model such as *Annona muricata*. L

**Comment [H11]:** Any reason for the open bracket? Opened bracket needs to be closed.

- A. *muricata* (Linn.) commonly called soursop, Graviola or guanabana is an evergreen tree native to the tropical regions belonging to the Annonacea family [11]. *A. muricata* plays a crucial role in various traditional and alternative. All parts of this tree are extensively used as traditional medicines. The bark, leaves, roots, fruit and fruit seeds have their own respective use [12-14]. The leaves of *A. muricata* have been reported to contain several groups of substances collectively called annonaceous acetogenins [15], annopentocin A, B and C, (2,4-cis) -annomuricin-D-one, murihexocin A and B, (2,4-trans) -annomuricin-D-one, 4-acetyl gigantetrocin and cis-gigantrionin [16], muricatocin A, B, and C [17], and annohexocin [16]. The high potency, selectivity, wide chemical and biological diversity, and effectiveness of these compounds against microbial resistance could well make them the next class of useful natural antitumor and pesticidal agents [18] and other pharmacological effects. The leaves of *A. muricata* have essential oils with parasitocidal, antidiarrheal, rheumatological, and antineuralgic properties [19]. Arthur and Woode [20] indicate that *A. muricata* have a high annonaceous acetogenins content which have high antioxidant activity. Recent study found that leaf extract of *A. muricata* has and modulatory effects on hematopoietic of male adults rabbits [21]. Despite extensive research into the antioxidant level and activity possessed by *A. muricata* and its effectiveness in treating disease, a comparative study of the antioxidant level and activity of *A. muricata* obtained from different locations has not been reported [22]. Nonetheless, previous studies have shown that there are different levels of antioxidant/phenolic content among plants of similar species [22, 24]. This study was designed to find out possible role of *A. muricata* suppress  $\text{SnCl}_2$  toxicity through alleviating hematological parameters disturbances in adult male rabbits.

**Comment [H12]:** Expunge pls

**Comment [H13]:** Should be italicized

**Comment [H14]:** Align with the paragraph above

## 2. MATERIAL AND METHODS

In this study stannous chloride ( $\text{SnCl}_2$ ) and ginseng were used. It was brought from chemistry department, faculty of science, and *A. muricata* leaf (powder) (maximum international company, Brasil) was purchased from local pharmacy. Each capsule contains 0.3125 g powder and the content of each capsule was dissolved in corn oil just before use. Mature male New Zealand White rabbits (age of 6 months and initial weight of  $(1.641 \pm 27.2 \text{ Kg})$  were used.

**Comment [H15]:** Which institution

**Experimental procedure:** Sixteen mature male rabbits were randomly divided into four equal groups:

- ❖ Group I: Rabbits were used as control and received an equivalent 1 ml of the vehicle (corn oil) alone by oral gavage twice per week for 10 successive weeks
- ❖ Group II: Rabbits were treated with *A. muricata* which was given daily by gavage at a dose of 100 mg/kg B.W, [25] dissolved in corn oil for 10 successive weeks.
- ❖ Group III: These rabbits will be treated orally with  $\text{SnCl}_2$  20mg/kg/day in corn oil by gavage [26] for 10 successive weeks.
- ❖ Group IV: Rabbits were given with  $\text{SnCl}_2$  daily at a dose of 20 mg/kg/day BW by gavage like group III and given *A. muricata* concurrently daily at a dose of 100 mg/kg B.W. by gavage like group II for 10 weeks.

**Body weight and organs weight:** Body weight of each animal was recorded weekly throughout the 10-weeks of the experimental period. The weight measurements were carried out in the morning before access to feed and water. At the end of treatment period, all animals of each group were slaughtered.

**Comment [H16]:** A scientific term will be better here. Sacrificed rather than slautered.

**Relative organs weight:** At the end of treatment period, all animals of each group were slaughtered. Weights of liver, kidney, lung, heart and spleen were also recorded.

**Comment [H17]:** Recall the earlier correction.

Organ weight was calculated relative to the total body weight, consequently upon next equation:

Relative (each organ) weight= Absolute organ weight/ total body weight \* 100.

**Comment [H18]:** This is not a multiplication sign.

**Hematological parameters:** Blood samples were collected from the ear vein of all animals every week throughout the 3-weeks experimental period. Blood samples were obtained in the morning before accesses to feed and water. Values derived from complete blood count (CBC). All CBC tests were performed by automatic blood cell analyzer (XP-300 Automated Hematology Analyzer, Sysmex American, Inc [27, 28]. CBCs were performed on EDTA as anti-coagulated samples. Differential cell counts were performed manually using Dif-Quik-stained blood smears. At the end of the experimental period, all rabbits were weighed then sacrificed under ether anesthesia to prepare bone marrow smear.

**Comment [H19]:** No need of the "s" "cos of the presence of the hyphen.

**Comment [H20]:** Opened bracket needs to be closed

**Preparation of bone marrow smears:** Bone marrow cells were collected from rabbit's femora after cutting away the epiphyses and condyles. Bone marrow smears were prepared as mothed described previously [27, 28].

**Statistical analysis:** Where applicable, statistical analysis was carried out in Minitab software (version17)/ GraphPad prism8; statistical significance was assessed using ANOVA analysis with Tukey multiple comparison test after detection normal distribution to the data and appropriate  $P < 0.05$  consider significant.

**Comment [H21]:** To be recast

### 3. RESULTS

The changes in body weight (BW) and the relative weights of liver, kidney, lung, heart and spleen of male rabbits were shown in Table 1. Overall means indicated that treatment with SnCl<sub>2</sub> caused significant decrease in BW and non-significant decrease relative weight of liver, kidney, and heart, and significant increase in relative weight of spleen compared to control animals. On the other hand the BW and relative weight of liver, kidney, lung and heart were non-significantly increased in rabbits treated with *A. muricata* alone as compared to control animals. The combination between *A. muricata* and SnCl<sub>2</sub> caused non-significant increase in the reduction of BW and improvement in relative organ weights due to treatment with SnCl<sub>2</sub>.

Table 2 shown results of hematological parameters. Results indicated that treatment with *A. muricata* caused non-significant decrease in RBC and significant decrease in MCV, MCH and significant increase in PCV, HB concentration, and MCHC concentration compared to control. On the other hand SnCl<sub>2</sub> was caused significant increase in MCV and MCH and significant decrease in Hb, RBCs, PCV and MCHC. Results also indicated that treatment with *A. muricata* caused significant decrease in WBCs and significant increase in PLT compared to control. While SnCl<sub>2</sub> caused significant increase in WBCs and insignificant decrease in PLT. The presence of *A. muricata* with SnCl<sub>2</sub> returned the values of the previous parameters to near to the control values. Figures (1-8) were represented results from hematological parameters of male rabbits treated with *A. muricata*, SnCl<sub>2</sub> and their combination among 10 weeks of experiment.

In term of bone marrow smear, all smears are similar in terms of numbers and types of cells. These cell lines include myelomonocytic cells (LY) and erythroid cells (E). Megakaryocytes (MG) were apparent in these fields. General pattern of bone marrow of NA, MO, LY, E, and MG were similar in treated smear in three groups compared to control (at same magnification 100X). (Figure 9)

**Table1: Illustrate the values of BW/ relative organ weights of male rabbits treated with *A. muricata*, SnCl<sub>2</sub> and their combination compared with control at end of experiment.**

Parameter	Control	<i>A.muricata</i>	SnCl <sub>2</sub>	<i>A. muricata + SnCl<sub>2</sub></i>
	Mean± SEM	Mean± SEM	Mean± SEM	Mean± SEM
BW (gm)	1988.2± 193 <sup>a</sup>	2134.5± 230 <sup>a</sup>	1956.3 ± 231 <sup>b</sup>	2107.7 ± 130 <sup>a</sup>
P. values	Groups= 0.034		Weeks=0.915	
Spleen (g/100 gm)	0.043± 0.003 <sup>b</sup>	0.040± 0.005 <sup>b</sup>	0.094± 0.010 <sup>a</sup>	0.050± 0.009 <sup>b</sup>
Liver (g/100gm)	2.177± 0.162 <sup>a</sup>	2.149± 0.286 <sup>a</sup>	2.033± 0.056 <sup>a</sup>	2.173± 0.166 <sup>a</sup>
Kidney (g/100gm)	0.583± 0.081 <sup>a</sup>	0.613 ±0.069 <sup>a</sup>	0.517 ±0.049 <sup>a</sup>	0.627± 0.035 <sup>a</sup>
Lung (g/100 gm)	0.473± 0.061 <sup>a</sup>	0.490± 0.047 <sup>a</sup>	0.403± 0.014 <sup>a</sup>	0.540± 0.011 <sup>a</sup>

Values are expressed as means ± SEM; n = 4 for each treatment group. Mean values within a row not sharing a common superscript letters (a, b) were significantly different, p<0.05.

Comment [H22]: Showed and not shown

Comment [H23]: Pls also illustrate with p>0.05

Comment [H24]: Pls also illustrate with p<0.05

Comment [H25]: As said earlier

Comment [H26]: As said earlier

**Table 2. Mean values of hematological parameters in male rabbits treated with *A. muricata*, SnCl<sub>2</sub> and their combination**

Parameter	Control Mean± SEM	<i>A. muricata</i> Mean± SEM	SnCl <sub>2</sub> Mean± SEM	<i>A. muricata</i> + SnCl <sub>2</sub> Mean± SEM
RBC×10 <sup>6</sup> (μl)	4.99± 0.386 <sup>a</sup>	4.80±0.144 <sup>a</sup>	4.26±0.266 <sup>b</sup>	4.77 ±0.192 <sup>a</sup>
p. values	Groups= 0.000		Weeks= 0.792	
PCV×10 <sup>3</sup> (μl)	33.1 ± 0.76 <sup>a</sup>	33.4 ± 0.44 <sup>a</sup>	25.4 ± 0.91 <sup>b</sup>	27.1 ± 0.8 <sup>b</sup>
p. values	Groups= 0.000		Weeks= 0.924	
Hb (g/dl)	13.49±0.304 <sup>ab</sup>	14.22±0.449 <sup>a</sup>	12.87±0.840 <sup>b</sup>	14.23±0.609 <sup>a</sup>
p. values	Groups=0.001		Weeks= 0.937	
MCV (fl)	86.15± 6.50 <sup>b</sup>	84.40 ±2.47 <sup>b</sup>	93.480±1.31 <sup>a</sup>	86.13± 4.65 <sup>b</sup>
p. values	Groups= 0.006		Weeks=0.997	
MCH (pg)	27.47±2.36 <sup>bc</sup>	26.07±2.42 <sup>c</sup>	30.980±0.51 <sup>a</sup>	29.833±1.13 <sup>ab</sup>
p. values	Groups= 0.000		Weeks=0.692	
MCHC (dl)	27.47 ±2.36 <sup>b</sup>	31.157±1.52 <sup>a</sup>	26.76± 2.40 <sup>b</sup>	29.83± 1.13 <sup>ab</sup>
p. values	Groups= 0.002		Weeks= 0.933	
WBC ×10 <sup>3</sup> (μl)	8.913±0.506 <sup>a</sup>	7.796±0.547 <sup>b</sup>	9.180±0.582 <sup>a</sup>	8.880±0.459 <sup>a</sup>
P. values	Groups= 0.001		Week= 0.934	
PLT ×10 <sup>3</sup> (μl)	255.7±24.13 <sup>b</sup>	313.27±22.18 <sup>a</sup>	193.1±29.38 <sup>c</sup>	250.53±13.50 <sup>b</sup>
P. values	Groups= 0.000		Week= 0.960	

Values are expressed as means ± SEM; n = 4 for each treatment group. Mean values within a row not sharing a common superscript letters (a, b, c) were significantly different, p<0.05.

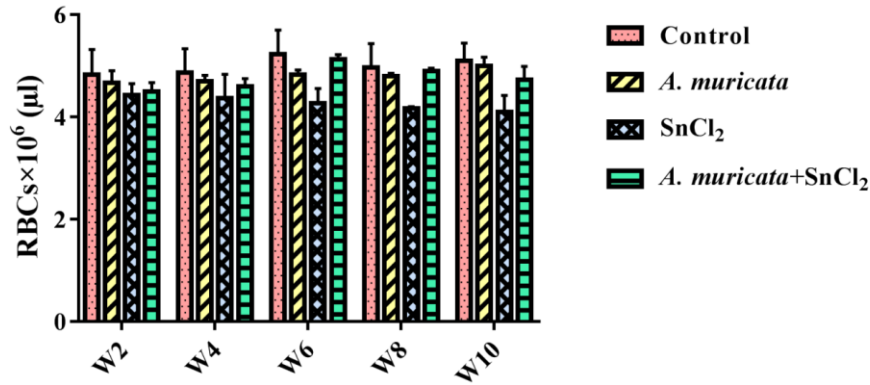


Fig. 1. Biweekly values of RBCs (Mean± SEM) in male rabbits treated with *A. muricata*, SnCl<sub>2</sub> and their combination

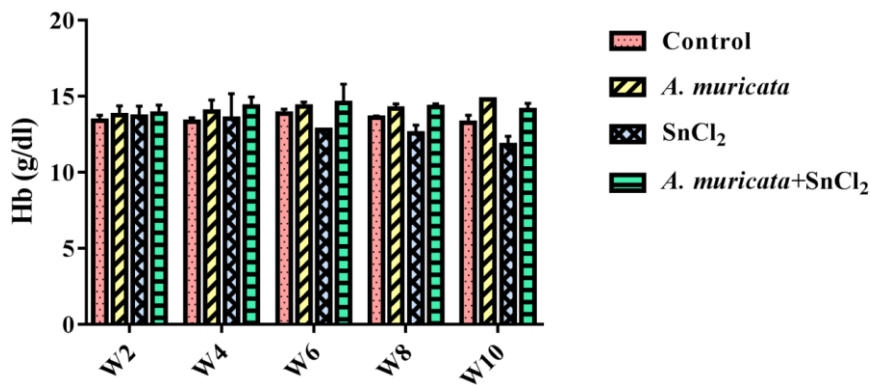


Fig. 2. Biweekly values of Hb (Mean± SEM) in male rabbits treated with *A. muricata*, SnCl<sub>2</sub> and their combination

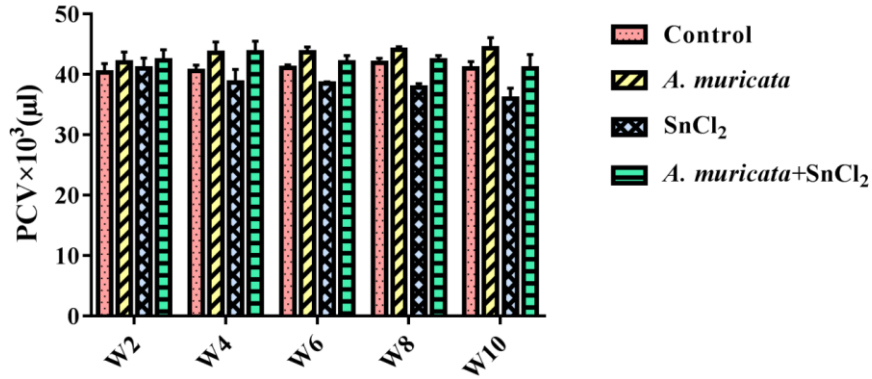


Fig. 3. Biweekly values of PCV (Mean± SEM) in male rabbits treated with *A. muricata*, SnCl<sub>2</sub> and their combination

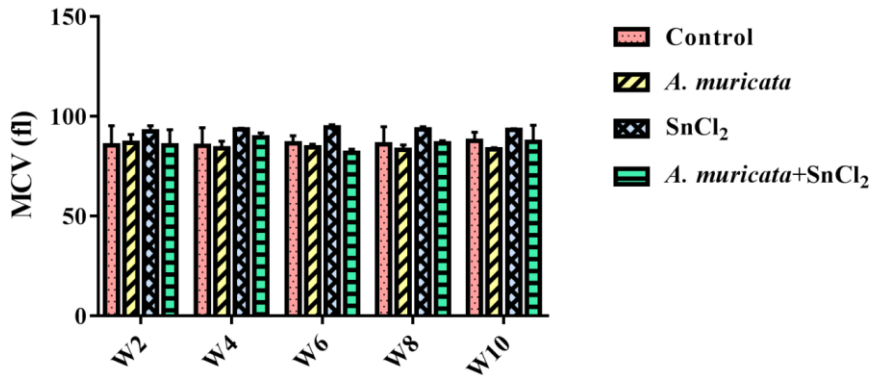


Fig. 4. Biweekly values of MCV (Mean± SEM) in male rabbits treated with *A. muricata*, SnCl<sub>2</sub> and their combination

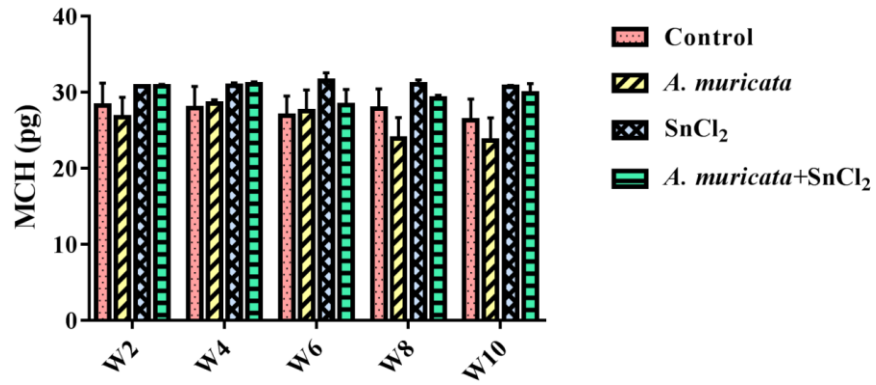


Fig. 5. Biweekly values of MCH (Mean± SEM) in male rabbits treated with *A. muricata*, SnCl<sub>2</sub> and their combination

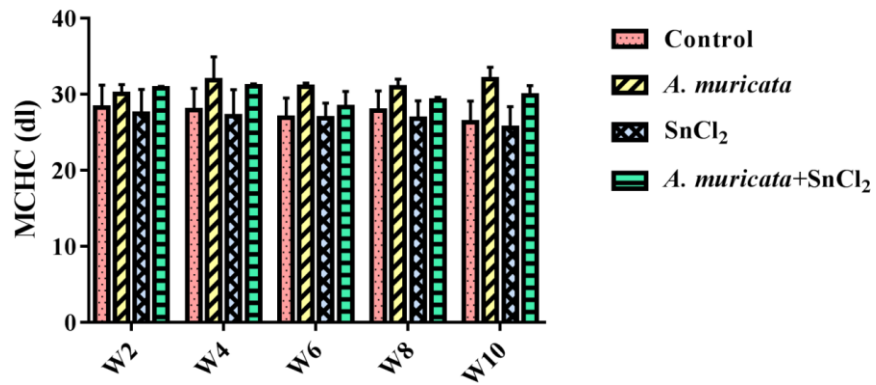


Fig. 6. Biweekly values of MCHC (Mean± SEM) in male rabbits treated with *A. muricata*, SnCl<sub>2</sub> and their combination

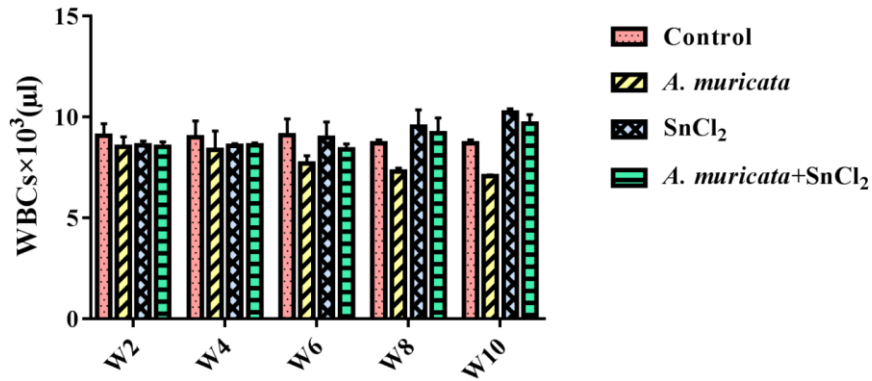


Fig. 7. Biweekly values of WBCs (Mean± SEM) in male rabbits treated with *A. muricata*, SnCl<sub>2</sub> and their combination

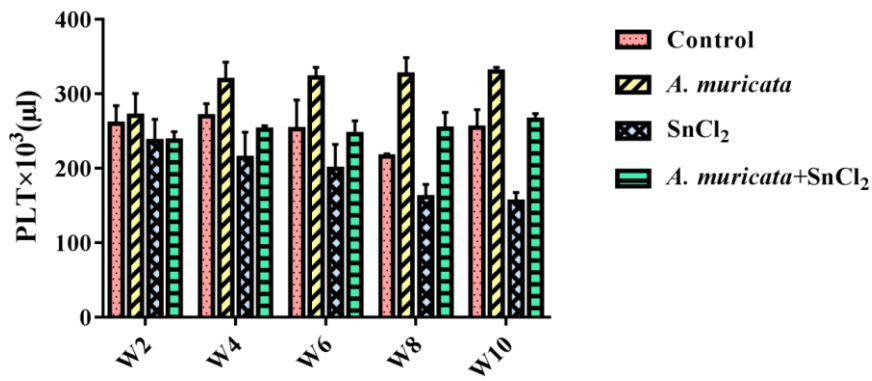
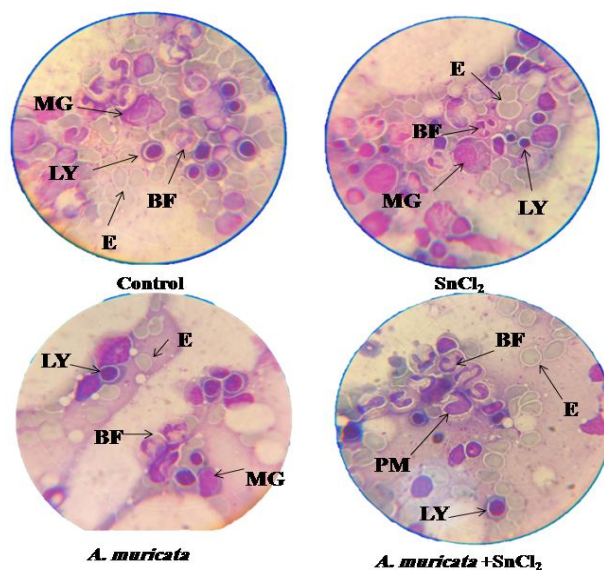


Fig. 8. Biweekly values of PLT (Mean± SEM) in male rabbits treated with *A. muricata*, SnCl<sub>2</sub> and their combination



**Fig. 9.** Different smears of bone marrow for a normal marrow from four groups of treatment after ten weeks of experiment. Three major cell lines are represented. These cell lines include Lymphoblast cells (LY), Megakaryocytes (MG), Promonocyte (PM), erythroid cells (E) and Band Form (BF) is apparent in these fields. (Magnification 100X).

#### 4. DISCUSSION AND CONCLUSION

SnCl<sub>2</sub> is widely used in daily human life to conserve soft drinks, in food manufacturing, processing and packaging, and in biocidal preparations [29]. The reports showed toxicity of SnCl<sub>2</sub> in rats, i.e. pathological changes in liver and kidney, brain edema, pancreatic atrophy, increased incidence of changes in fatty acids and vacuoles in the proximal convoluted tubules [30]. SnCl<sub>2</sub> is known to (i) inhibit the immune response in rodents, (ii) alter the gene expression (iii) induce tumor generation in thyroid gland. SnCl<sub>2</sub> is also capable to induce the generation of reactive oxygen species (ROS) that are responsible for oxidative stress [31-33]. The present study was undertaken to evaluate the potential protective effects of *A. muricata* against hematological parameters in male rabbits induced by SnCl<sub>2</sub>. The present results indicate that treatment with SnCl<sub>2</sub> caused significant reductions in BW and relative organs weight except spleen. The reduction in BW and relative organs weight in SnCl<sub>2</sub> treated rabbits; it is in agreement with the finding of Yousef [34]. Relative organ weights were reduced by SnCl<sub>2</sub> treatment. Similar results were also obtained from previous studies [35-37] in rats. In agreement with Yousef [34] who administered that BW and food intake and relative weights of rabbits treated with SnCl<sub>2</sub> were decreased. Current study was found an increased in relative weight of spleen, similarly, Chiba, et al., [38] reported that a relatively high deposition of tin was found in the spleen of rabbits. The BW and relative weight observed in the present study due to treatment with *A. muricata* leaves capsules induced increase in the final BW comparing to control group. This result agreement with the results of Ezejindu, et al., [39] in rats treated with low dose of *A. muricata* for twenty eight days that

**Comment [H27]:** SnCl<sub>2</sub>

**Comment [H28]:** Replace with a comma (,)

**Comment [H29]:** Expunge

**Comment [H30]:** Not properly written, Chiba et al. [38] et al should be italicised pls

**Comment [H31]:** Not properly written

significantly increased the BW compared with the control group. The results of the present study showed that *A. muricata* has increased relative organs weight in rabbits. The protective antioxidant mechanisms maintain the cellular oxidation-reduction potentials required for normal metabolism and to prevent free radical attack of amino acids, proteins, and the lipid components of cell membranes necessary for functional and structural integrity of cells and tissues [40]. The reduction in BW gains may be due to oxidative stress [41, 42] and/or due to the increased degradation of lipids and proteins as direct effects of toxic compound exposure [43-45].

The present study showed that SnCl<sub>2</sub> caused decrease RBCs, Hb, PCV and PLT that agreement with Beynen, et al., [46] who found that iron status (Hb, PCV, RBC) in rabbits was not influenced by dietary tin concentrations < 100 mg Sn/kg diet as SnCl<sub>2</sub> for 28 days. In previous reports showed the hematological parameters (Hb, RBC, and PCV) were significantly reduced in the high-dose treated groups (720 mg Sn/kg). These similar to previous reports in rat, which were interpreted by tin interfering with iron uptake or by promoting iron loss, as well as inhibition of δ- ALAD activity in the erythrocytes [46, 47, 48]. Haemoglobin was decreased and BW reduced in a dose-related way in the tin-fed groups. A study in Wistar rats fed on diets containing various concentrations of tin (1, 10, 50, 100 and 200 mg Sn/kg as SnCl<sub>2</sub>) for 28 days showed that, the blood Hb concentration and percentage transferrin saturation decreased in a linear manner as the level of dietary tin increased [49]. Chmielnicka, et al., [8] their result also indicates significant decrease in MCHC in rabbits receiving after SnCl<sub>2</sub> administration indicates the toxic influence of this metal on blood morphology. *A. muricata* was caused increase in hematological parameters of rabbits (100 mg/kg), and this also was in agreement with Usunomena [50] who reported that pretreatment with 400mg/kg *A. muricata* significantly enhanced the WBCs, platelets, PCV, RBCs and Hb. This indicates that *A. muricata* improves immunity function and decrease inflammation. Similarly other studies reported that extract of *A. muricata* has a stimulator property which ultimately results in increased PCV, RBC and decrease in the WBC in Swiss albino rats and rabbits [21, 51]. *A. muricata* extract possess the potential to stimulate the release of erythropoietin which is the hormonal regulator of RBC production from the kidney (52). The decrease in MCV indicates that older and healthier erythrocytes were destroyed (52). Chmielnicka, et al., [8] reported morphological changes both in blood and in bone marrow of rabbits exposed to SnCl<sub>2</sub> were demonstrated and suggested a the damaging of erythrocytes by these metals, leading to a reduction of their life-span. This is supported by the fast decrease in hemoglobin and hematocrit values in the blood, as well as of the number of RBCs. Hwoever Ejere, et al., [52] reported that *A. muricata* extract stimulate the bone marrow to production of RBCs by release of erythropoietin from kidney.

**In conclusion**, the results of the present study convincingly demonstrated that SnCl<sub>2</sub> exposure resulted in varying degree of hematological parameters of rabbits. *A. muricata* has been promise as nutritional supplements to help prevent disorders involving SnCl<sub>2</sub> induced toxic effects. *A. muricata* is a potent antioxidant due to its ability to attenuate the reactivity of ROS and to enhance the activities of detoxifying enzymes thereby that prevent lipid peroxidation reactions. Thus *A. muricata* may be helpful to combat SnCl<sub>2</sub> associated sufferings in human as well as animal.

#### COMPETING INTERESTS DISCLAIMER:

Authors have declared that no competing interests exist. The products used for this research are commonly and predominantly use products in our area of research and country. There is absolutely no conflict of interest between the authors and producers of the products because we do not intend to use these products as an avenue for any litigation but for the

Comment [H32]: As said earlier

Comment [H33]: As said earlier

Comment [H34]: As said earlier

Comment [H35]: As said earlier

Comment [H36]: SnCl<sub>2</sub>-induced

advancement of knowledge. Also, the research was not funded by the producing company rather it was funded by personal efforts of the authors.

## REFERENCES

1. Harper C. Toxicological profile for tin and tin compounds. Agency for Toxic Substances and Disease Registry, 2005.
2. Leger J, Haines J, Atouf A. The high pressure behaviour of the cotunnite and post-cotunnite phases of  $\text{PbCl}_2$  and  $\text{SnCl}_2$ . *Journal of Physics and Chemistry of Solids*. 1996;57(1):7-16.
3. Hiles RA. Absorption, distribution and excretion of inorganic tin in rats. *Toxicology and applied pharmacology*. 1974;27(2):366-79.
4. Sun L-H, Zhang N-Y, Zhai Q-H, Gao X, Li C, Zheng Q, et al. Effects of dietary tin on growth performance, hematology, serum biochemistry, antioxidant status, and tin retention in broilers. *Biological trace element research*. 2014;162(1-3):302-8.
5. El-Makawy AI, Girgis SM, Khalil WK. Developmental and genetic toxicity of stannous chloride in mouse dams and fetuses. *Mutation Research/Genetic Toxicology and Environmental Mutagenesis*. 2008;657(2):105-10.
6. Şişman T. Early life stage and genetic toxicity of stannous chloride on zebrafish embryos and adults: toxic effects of tin on zebrafish. *Environmental toxicology*. 2011;26(3):240-9.
7. Janssen PJ, Bosland MC, van Hees JP, Spit BJ, Willems MI, Kuper CF. Effects of feeding stannous chloride on different parts of the gastrointestinal tract of the rat. *Toxicology and applied pharmacology*. 1985;78(1):19-28.
8. Chmielnicka J, Zareba G, Polkowska-Kulesza E, Najder M, Korycka A. Comparison of tin and lead toxic action on erythropoietic system in blood and bone marrow of rabbits. *Biological trace element research*. 1993;36(1)(1):73-8.
9. De Groot A, Feron V, Til H. Short-term toxicity studies on some salts and oxides of tin in rats. *Food and cosmetics toxicology*. 1973;11(1):19-30.
10. Okolie N, Abu O. Effects of Aqueous Extract of *Annona muricata* Leaves on Cyanide-induced Toxicity in New Zealand Rabbits. *Nigerian Society for Experimental Biology*. 2019;16(4):142-7.
11. Moghadamtousi SZ, Fadaeinasab M, Nikzad S, Mohan G, Ali HM, Kadir HA. *Annona muricata* (Annonaceae): A Review of Its Traditional Uses, Isolated Acetogenins and Biological Activities. *International journal of molecular sciences*. 2015;16(7):15625-58. PubMed PMID: 26184167. eng.
12. Adewole SO, Salako AA, Doherty WO, Naicker T. Effect of Melatonin on Carbon Tetrachloride-Induced Kidney Injury in Wistar Rats. *African Journal Biomedical Research*. 2010;10(2):153-64.

Comment [H37]:  $\text{PbCl}_2$  and  $\text{SnCl}_2$

13. De Sousa OV, Vieira GD-V, De Pinho JdJRG, Yamamoto CH, Alves MS. Antinociceptive and Anti-Inflammatory Activities of the Ethanol Extract of *Annona muricata* L. Leaves in Animal Models. *International Journal of Molecular Sciences*. 2010;11(5):2067-78.
14. Mishra S, Ahmad S, Kumar N, Sharma BK. *Annona muricata* (the cancer killer): a review. *The Global Journal of Pharmaceutical Research*. 2013;2:1613-8.
15. Kim G-S, Zeng L, Alali F, Rogers LL, Wu F-E, Sastrodihardjo S, et al. Muricoreacin and murihexocin C, mono-tetrahydrofuran acetogenins, from the leaves of *annona muricata*. *Phytochemistry*. 1998 1998/09/28;49(2):565-71.
16. Zeng L, Wu F-E, Oberlies NH, McLaughlin JL, Sastrodihardjo S. Five New Monotetrahydrofuran Ring Acetogenins from the Leaves of *Annona muricata*. *Journal of Natural Products*. 1996 1996/01/01;59(11):1035-42.
17. Wu FE, Gu ZM, Zeng L, Zhao GX, Zhang Y, McLaughlin JL, et al. Two new cytotoxic monotetrahydrofuran Annonaceous acetogenins, anomuricins A and B, from the leaves of *Annona muricata*. *The Journal of Natural Products* 1995 Jun;58(6):830-6. PubMed PMID: 7673926. Epub 1995/06/01. eng.
18. Alali FQ, Liu X-X, McLaughlin JL. Annonaceous Acetogenins: Recent Progress. *Journal of Natural Products*. 1999 1999/03/01;62(3):504-40.
19. Gleye C, Duret P, Laurens A, Hocquemiller R, Cavé A. cis-Monotetrahydrofuran Acetogenins from the Roots of *Annona muricata*. *Journal of Natural Products*. 1998 1998/05/01;61(5):576-9.
20. Adewole SO, Ojewole JAO. Immunohistochemical And Biochemical Effects Of *Annona Muricata* Linn. (Annonaceae) Leaf Aqueous Extract On Pancreatic B-Cells Of Streptozotocin-Treated Diabetic Rats. *Pharmacologyonline*. 2006;2:335-55.
21. Ibrahim MA, Saad EK, Khaled FA, Ali MS. Hematopoietic and modulatory effects of leaf extract of *Annona muricata* on Male adults rabbits. *International Journal of Pharmacy & Life Sciences*. 2021;12(3):50.
22. Coria-Télez AV, Montalvo-González E, Yahia EM, Obledo-Vázquez EN. *Annona muricata*: A comprehensive review on its traditional medicinal uses, phytochemicals, pharmacological activities, mechanisms of action and toxicity. *Arabian Journal of Chemistry*. 2018;11(5):662-91.
23. Lim Y, Quah E. Antioxidant properties of different cultivars of *Portulaca oleracea*. *Food chemistry*. 2007;103(3):734-40.
24. Fareda. H. Mekal, Kahald FA, Ali. MS. Comparison the role of natural antioxidants (ginger, *A. muricata* L or *P. ginseng*) on hematological parameters in male rabbits. *Libyan Journal Of Basic Sciences (LJBS)*, 2020;10(1):44-52.
25. Somsak V, Polwiang N, Chachiyo S. In vivo antimalarial activity of *Annona muricata* leaf extract in mice infected with *Plasmodium berghei*. *Journal of pathogens*. 2016;4:1-5.

26. Yousef M, Awad T, Elhag F, Khaled F. Study of the protective effect of ascorbic acid against the toxicity of stannous chloride on oxidative damage, antioxidant enzymes and biochemical parameters in rabbits. *Toxicology*. 2007;235(3):194-202.
27. Bain B. Blood cell morphology in health and disease. In: SM L, BJ B, I B, editors. *Practical Hematology* 9th ed. London: Churchill Livingstone; 2001. p. 65-99.
28. Turgeon M. *Clinical Hematology Theory and Procedures, Fundamentals of Hematological Analysis*. 5th ed. Philadelphia: Lippincott Williams & Wilkins, a Wolters Kluwer business. ; 2012. 456-580 p.
29. de Mattos JC, Dantas FJ, Bezerra RJ, Bernardo-Filho M, Cabral-Neto JB, Lage C, et al. Damage induced by stannous chloride in plasmid DNA. *Toxicology Letters*. 2000;116(1-2):159-63.
30. Dreef VD, Meulen H, Feron V, Til H. Pancreatic atrophy and other pathological changes in rats following the feeding of stannous chloride. *Pascal and Francis Bibliographic Databases*. 1974;9(3):185-92.
31. Araújo ACd, Dantas FJ, Moraes MO, Felzenszwalb I, Bernardo Filho M. Stannous chloride participates in the generation of reactive oxygen species. *Ciênc cult(São Paulo)*. 1996;48:13-109.
32. Dantas F, Moraes M, Carvalho E, Valsa J, Bernardo-Filho M, Caldeira-de-Araujo A. Lethality induced by stannous chloride on *Escherichia coli* AB 1157: participation of reactive oxygen species. *Food and Chemical Toxicology*. 1996;34(10):959-62.
33. Dantas FJ, Moraes MO, de Mattos JC, Bezerra RJ, Carvalho EF, Bernardo Filho M, et al. Stannous chloride mediates single strand breaks in plasmid DNA through reactive oxygen species formation. *Toxicology Letters*. 1999;110(3):129-36.
34. Yousef MI. Protective role of ascorbic acid to enhance reproductive performance of male rabbits treated with stannous chloride. *Toxicology*. 2005;207(1):81-9.
35. Beynen A, Pekelharing H, Lemmens A. High intakes of tin lower iron status in rats. *Biological trace element research*. 1992;35(1):85-8.
36. Omura M, Ogata R, Kubo K, Shimasaki Y, Aou S, Oshima Y, et al. Two-generation reproductive toxicity study of tributyltin chloride in male rats. *Toxicological Sciences*. 2001;64(2):224-32.
37. Yu S, Beynen AC. High tin intake reduces copper status in rats through inhibition of copper absorption. *British journal of nutrition*. 1995;73(6):863-9.
38. Chiba M, Ogihara K, Inaba Y, Nishima T, Kikuchi M. The organ distribution of tin and the effect of tin on concentrations of several essential elements in rabbit. *Toxicology*. 1984;31(1):23-32.
39. Ezejindu D, Udemezue O, Chukwujekwu I, Uchefuna R, Maduka S, Akingboye A, et al. The histological effects of *Annona Muricata* (Soursop) on the Adrenal Gland of Adult Wistar Rats. *International Journal of Biomedical and Advance Research*. 2014;5(10):505-8.

40. Feldman RG, Ricks NL, Baker EL. Neuropsychological effects of industrial toxins: A review. *American journal of industrial medicine*. 1980;1(2):211-27.
41. Mansour S, Mossa A. Adverse effects of lactational exposure to chlorpyrifos in suckling rats. *Human & experimental toxicology*. 2010;29(2):77-92.
42. Saafi EB, Louedi M, Elfeki A, Zakhama A, Najjar MF, Hammami M, et al. Protective effect of date palm fruit extract (*Phoenix dactylifera* L.) on dimethoate induced-oxidative stress in rat liver. *Experimental and Toxicologic Pathology*. 2011;63(5):433-41.
43. Goel A, Dhawan D, Kheruka S. Evaluation of zinc in the regulation of serum T 3 and T 4 levels and hepatic functions in carbontetrachloride-intoxicated rats. *Biological trace element research*. 1994;41(1):59-68.
44. Heikal T, Soliman M. Effect of fish oil supplementation on brain DNA damage and hepatic oxidant/antioxidant status in dimethoate-treated rats. *egyptian society of clinical toxicology journal*. 2010;42:1-9.
45. Mossa A-TH, Refaie AA, Ramadan A. Effect of exposure to mixture of four organophosphate insecticides. *Research Journal of Environmental Toxicology*. 2011;5:323-35.
46. Beynen A, Pekelharing H, Lemmens A. High intakes of tin lower iron status in rats. *Biological trace element research*. 1992;35(1):85-8.
47. De Groot A. Subacute toxicity of inorganic tin as influenced by dietary levels of iron and copper. *Food and cosmetics toxicology*. 1973;11(4):955-62.
48. Johnson MA, Greger J. Tin, copper, iron and calcium metabolism of rats fed various dietary levels of inorganic tin and zinc. *The Journal of nutrition*. 1985;115(5):615-24.
49. Janssen PJ, Bosland MC, van Hees JP, Spit BJ, Willems MI, Kuper CF. Effects of feeding stannous chloride on different parts of the gastrointestinal tract of the rat. *Toxicology and applied pharmacology*. 1985;78(1):19-28.
50. Usunomena U. Protective effects of *Annona muricata* ethanolic leaf extract against Dimethylnitrosamine (DMN)-Induced Hepatotoxicity. *IOSR Journal of Pharmacy & Biological Sciences*. 2014;9(4):01-6.
51. Faleye OS, Dada EO. Effects of ethanol extract of unripe *Annona Muricata* (L.) fruits on the Haematological and Histopathological parameters in Swiss albino rats infected with salmonella Typhi. *Journal of Pharmaceutical Research International*. 2016;9:1-13.
52. Ejere VC, Nnamonu D, Chukwuka CO, Ugwu G, Ejim AO, Asogwa CN. Effects of aqueous extract of *Hibiscus sabdariffa* calyces on haematological characteristics of *Rattus norvegicus*. *Animal Research International*. 2013;10(3):1809–16.

**Comment [H38]:** Ensure reference style is what the journal has stated in her author guide, and ensure cited references are not missing in the reference page.