

Case study

PANCREATIC ADENOCARCINOMA ASSOCIATED WITH VOCAL CORD PARALYSIS

ABSTRACT

A 30-year-old male patient presented with a mixed complaint. He initially had developed complaints of backache two months ago. This pain was accompanied by the formation of two lumps in the back in the upper and lower regions. However, this was not the reason behind him presenting to the hospital. He complained of hoarseness of the voice, which seemed to have no background.

The man is neither an alcoholic nor a smoker. He has no significant medical or surgical history. His work history also remains unrelated to the hoarseness of his voice, as he is not required to speak loudly, which is typically linked to over exertion of the vocal cords.

Upon examination, it was learned that the two lumps that the patient had initially observed had grown in number. Now, there were several lumps on his back and shoulder regions.

When this particular observation, coupled with the hoarseness of voice, was investigated via diagnostic imaging techniques such as X-ray, CT, and MRI, it was discovered that the patient was suffering from Grade IV Pancreatic Adenocarcinoma. The cancer had progressed significantly as there was numerous organ involvement observed. The liver, adrenal glands,

lungs, subcutaneous tissues, and muscles were all seen to be involved. Along with this, he had also developed bilateral deep vein thrombosis on both his lower limbs.

Although the patient had no significant symptoms that could have forced an earlier diagnosis, it was evident that the carcinoma was pancreato-biliary in origin.

The patient is now undergoing his chemotherapy, and so far, he has shown a remarkable 'partial' response to his treatment cycles. Therefore, a good prognosis is hoped if the progress remains the same over time.

This case study aims to reflect on all the possible angles of this patient's presentation. It is also the utmost priority to correlate and investigate the link of his hoarseness with his actual cancer. This case study will guide future physicians and clinicians who will come across confusing cases such as these to reach a conclusive diagnosis.

Had it not been for the advanced diagnostic imaging technologies available within reach of both the hospital and the patient, the patient undoubtedly would have only been treated for his hoarseness, leaving the actual disease unchecked, undiagnosed, and untreated.

Keywords: Pancreatic Adenocarcinoma, hoarseness of voice, vocal cords

INTRODUCTION

Pancreatic cancer is the second most common malignancy of gastrointestinal origin in the United States, and has grown in incidence and prevalence in recent years. Given its poor prognosis, it has become the talk of the town for the physicians and surgeons as, sometimes, not even an early diagnosis can help prevent the disease from progressing at such a rapid rate, as seen from this malignancy. (1)

Furthermore, the cost of advanced and top-notch diagnostic imaging facilities such as endoscopic ultrasound and cross-sectional imaging is too much to be ordered without having a highly suspicious doubt about the diagnosis.

Pancreatic cancer is recognized as a disease of the elderly. It most commonly affects men, and it is more prevalent among African-Americans. (2)

The one- and five-year mortality rates associated with pancreatic carcinoma are 24% and 6%, respectively. The disease is such a rapidly spreading one that, at the time of diagnosis, approximately 80% of all patients are seen to be suffering from multiple local and regional metastasis, indicating that the prognosis is generally unfavorable. (3) (4)

The most common risk factors that are associated with the prevalence of pancreatic carcinoma include smoking, diabetes mellitus (type II), obesity, alcoholism, and genetic predisposition, among others. (5)

Generally speaking, about 95% of all pancreatic carcinomas are exocrine in origin, meaning that they arise from the acinar and ductal regions. Since genetic predisposition is a marked risk factor, it becomes extremely important to order genetic screening and mutation tests to look out for links that might help exclude the familial component of pancreatic adenocarcinoma. (6)

70% of all pancreatic adenocarcinomas are found in the head of the pancreas, 10% in the body of the pancreas, and another 10-15% in the tail (7). Surgery stands out as the only treatment of choice for pancreatic adenocarcinoma. It is also the only therapeutic modality that was found to have curative value for the patient.

This case study provides a similar case study to ponder upon, as it already had an interesting presentation. The patient was young and had no significant complaints that could have pointed toward the diagnosis of this tumor. The preceding sections elaborate on how the diagnosis of this case was made possible amidst all the confusing scenarios at hand.

UNDER PEER REVIEW

CASE STUDY

This case revolves around a 30-year-old male patient who presented to the hospital with a mixed scenario. His presenting complaint was that of the hoarseness of his voice associated with the paralysis of his vocal cords. Along with this, he also complained of back pain that was present two months before the hoarseness of his voice developed.

Upon taking a detailed history, it was found that the patient had no comorbidities. He is not a smoker nor an alcoholic. There was no history of any kind of exposure to radiation or other hazardous chemicals that might have led to his symptoms. There was no fever or pain of any kind associated with the patient's condition.

Moreover, there was no kind of laryngeal trauma. The patient also denied having a screaming match or any kind of above-average-volume talking episodes with anyone. His family history of cancer stands out to be unremarkable.

Examinations

On fiber optic laryngoscopy, the patient was found to have a left sided vocal cord immobility. The left vocal cord appeared shorter, was flaccid and in a paramedian position which is typical in a recurrent laryngeal nerve dysfunction. There were no other anomalies on his laryngoscopy that could readily explain this immobility. Palpation of his neck did not reveal any masses or lymphadenopathies.

Despite all this history, there were certain findings that raised suspicions regarding a possible hidden diagnosis. The patient said that he had noticed two lumps on his back two months ago. These lumps were on his upper and lower back. However, when an examination was done, these lumps were found all over his back and shoulder region, indicating that they had increased in

number. The lumps appeared to be subcutaneous in nature and were not deeply embedded within the tissue.

Along with this, bilateral deep vein thrombosis was found on both the legs. This clinical picture was sufficient enough to order the appropriate investigations for the patient.

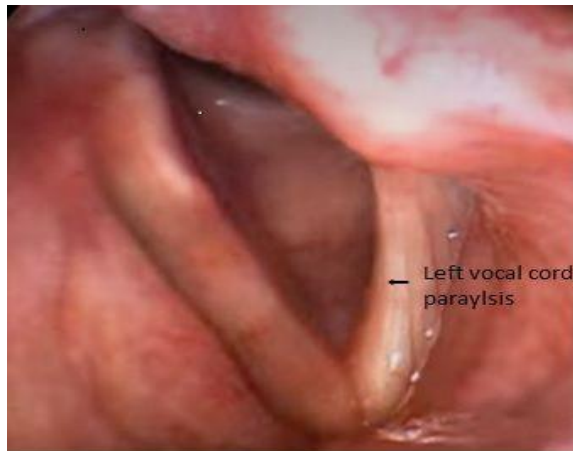

Figure 1: Unilateral vocal cord paralysis

Imaging

Several imaging and investigations were ordered for this patient, as the doctors were unable to reach a conclusive diagnosis that could explain everything clearly and help find an appropriate diagnosis for the patient.

All the imaging modalities, along with their impressions, have been displayed as follows:

Figure 2: CT Scan Chest

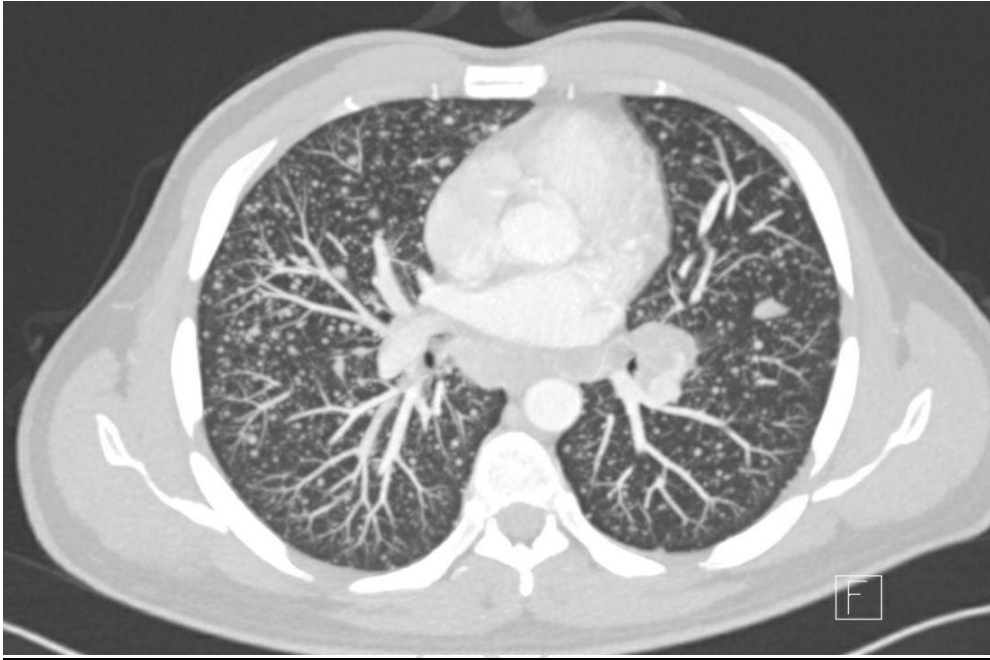
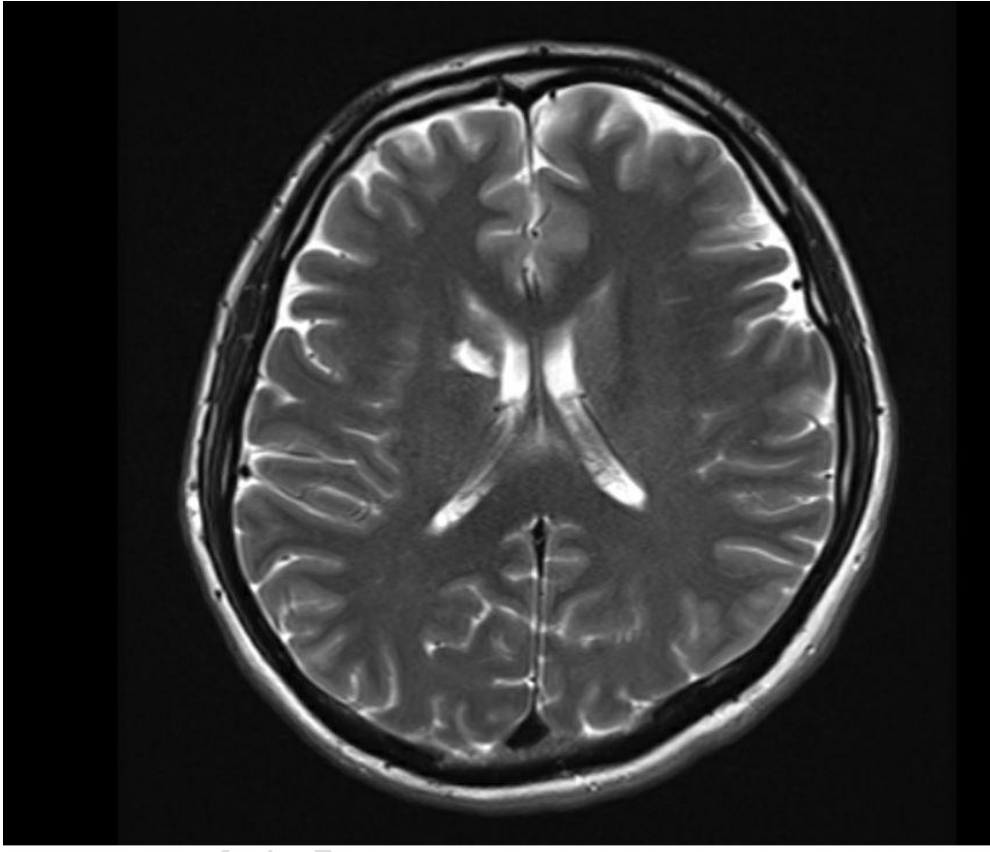


Figure 3: CT Scan Abdomen

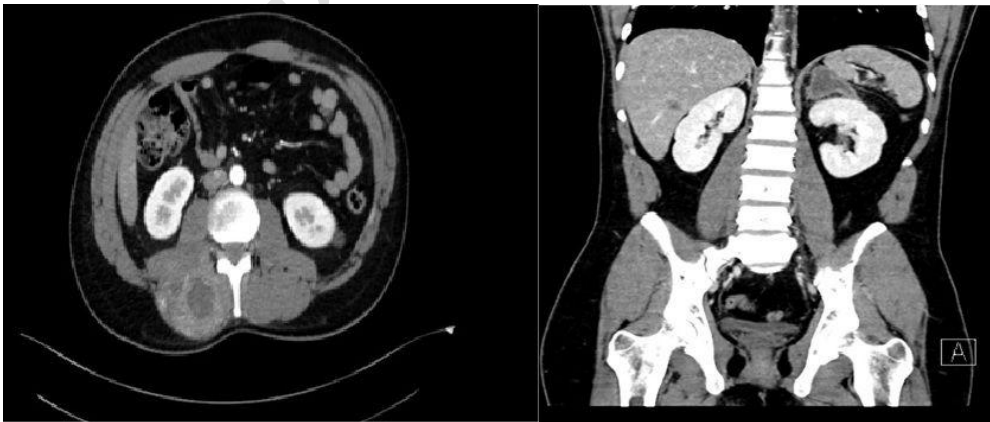

Figure 4: MRI Brain



Findings

From the imaging's displayed above, it is evident that there were several lung, liver, pancreatic masses and bony lesions visualized.

The CT scans showed widespread malignancy, strongly suspected to be of pancreato-biliary origin, which was the actual cause of all the symptoms and metastasis present in the patient.

There were large deposits present in the subcutaneous and intramuscular regions. Along with that, metastasis could be appreciated along with the liver, left adrenal gland, pancreas, and a large portion of the upper lobe of the left lung displaying military metastasis.

The patient was also found to have bilateral pulmonary embolism with an associated deep vein thrombosis on both the lower limbs, thus establishing the correlation between the two. The result was summarized as:

“Widespread metastatic malignancy with large deposits in the subcutaneous, intramuscular, multiple liver metastases, left adrenal, liver, and pancreas deposits and a large left upper lobe lung mass with military metastases in the lungs. The pattern of metastasis would likely be primarily from the lung. An incidental but significant finding of bilateral lower lobe pulmonary artery embolism noted.”

Formatted: Font color: Red

The MRI brain was unremarkable. No brain deposits or metastasis were seen or reported so far.

Biopsy

Upon examination, the findings related to his subcutaneous deposits can be summarized as follows,

“No muscular or bony tenderness, no erythematous joints. Multiple subcutaneous tumor masses over the right shoulder in the back paraspinal region and bilateral upper thigh. They are solid, ranging from 2 cm in size up to 8 cm in size.”

Formatted: Font color: Red

An IR-guided biopsy was performed for his subcutaneous back deposits or lumps to confirm the diagnosis. It was found that it was indeed due to metastatic adenocarcinoma of pancreato-biliary origin. The biopsy results could be summarized as under:

“Section shows malignant cells arranged in glands and trabeculae with a moderate degree of pleomorphism. The nuclei show hyperchromasia with coarse chromatin and small nucleoli. A desmoplastic stromal reaction is seen in the background.”

Immunohistochemistry:

“The tumor cells are positive for CK7, CK19. CDX2 shows moderate nuclear staining. TTF-1 shows very focal nuclear staining. Tumor cells are negative for CK20, P 63, P 40, and Napsin A. The above immunophenotype is suggestive of upper gastrointestinal origin/pancreaticobiliary origin.”

TTF-1 shows weak focal nuclear staining in a small amount of the tumor cells (5%), and lung adenocarcinoma cannot be completely ruled out. Please correlate with tumor serum markers, endoscopy, and radiological findings.

Diagnosis:

A. Right shoulder mass biopsy: Metastatic adenocarcinoma.

B. Tissue biopsy, Para-lumbar: Metastatic adenocarcinoma.

Investigations

Table 1: The investigations and their results have been summarized as under:

CEA	164
CA 19-9	> 100,000
BRCA	Negative
MMR	Proficient

TMB	11 (High)
PDL 1 CPS	5%

Diagnosis

Based on the investigations, imaging, and examinations mentioned above, the patient was confirmed as a case of:

“Stage IV Pancreatic Cancer with Liver, Lung, Left Adrenal And Subcutaneous Tissue and Muscle Metastasis.”

Plan For Treatment

The patient was started on anticoagulants for his bilateral DVT. It was decided that the patient’s vocal cord paralysis was to be left unattended for the time being or until his treatment for the metastases and the tumor showed any significant improvement. The tumors and their shrinkage come first.

The reason for doing so was because only with the complete disappearance of his lung tumor, there is a chance his recurrent laryngeal nerve might recover. However, there is a chance that this might not happen.

Therefore, in such cases, temporary measures were suggested, such as a resorbable filler injection. If his vocal cord mobility does not return after the end of his treatment and the doctor’s team concludes that he has permanent paralysis, procedures such as thyroplasty with silicone or Gore-Tex implants to medialize the vocal cord were to be applied and used.

For his cancer, chemotherapy was to be initiated as soon as possible.

Treatment Status:

The patient is currently undergoing chemotherapy for his cancer and has already received six cycles of FOLFOXIRI. His latest computerized tomography scan shows a reduction in the size of all his metastasis.

Moreover, the tumor marker CA 19-9 decreased to more than 10,000 instead of >100,000, but the LDH decreased from 1100 to about 300.

Anticoagulation is still continued for bilateral lower extremity deep vein thrombosis.

Post-Chemotherapy CT Scan Findings:

Another CT scan was ordered halfway through the treatment to assess the patient's response to chemotherapy and see if any improvement had taken place or not.

The findings could be summarized as follows:

There has been significant tumoral calcinosis within the right shoulder girdle muscle since the previous examination. Small sub-centimeter reactive lymph nodes in the neck. No significant cervical lymphadenopathy.

There has been a reduction in the size of the left upper lobe mass, measuring 3 x 4 cm, and this was previously 5.2 cm. Significant resolution of the miliary metastasis in both lungs since the previous scan. No pleural or pericardial effusions. There was also a reduction in the size of the perivascular lymph nodes.

Formatted: Font color: Red

Further subtle reduction in the size of the multiple liver metastases since a previous scan. Reduction in the size of the left adrenal necrotic metastasis measuring 6 x 4 cm, and this was previously 7 x 5 cm.

Extensive tumor calcinosis in the right paravertebral mass lesion.

No new lesions were seen. No ascites or peritoneal mass lesions. Sclerosis of mid-thoracic vertebrae is most likely to be a tumor response. No vertebral retropulsion.

Impression:

At least partial response to chemotherapy as evidenced by a reduction in the size of the left upper lobe lung mass and a further reduction in the miliary metastases as well as the size of the left adrenal mass. Significant tumor calcinosis was noted in the subcutaneous mass lesions. Sclerosis of the thoracic vertebrae is also likely due to tumor response.

DISCUSSION

Pancreatic cancer or pancreatic adenocarcinoma refers to any cancerous growth that arises from the pancreatic ductal cells. In the United States, pancreatic cancer has been found to be the fourth leading cause of death. (8)

Formatted: Font color: Red

Formatted: Font color: Red

The reason for this is the poor prognosis of the disease. Although the surgical treatment that exists for it is found to be highly curative, only 6% of the cases of pancreatic carcinoma are found to be treatable at the time of diagnosis. (9)

Formatted: Font color: Red

Formatted: Font color: Red

The 5-year survival rate for pancreatic cancer patients rests at about 5% globally. There are several risk factors that exist behind the occurrence of this disease. Smoking, alcoholism, age of more than 55 years (in 90% of all cases), obesity, diabetes, chronic pancreatitis, liver cirrhosis, male gender, and African-American race all contribute to the pathogenesis of this disease. (10)

Formatted: Font color: Red

Formatted: Font color: Red

Pancreatic carcinoma has different origins - it could be an adenocarcinoma, serous, mucinous, or seromucous in origin. Two-thirds of all these cases arise in the head of the pancreas, and the rest of the one-third in the body and tail of the pancreas. (11)

Formatted: Font color: Red

Formatted: Font color: Red

Two tumor markers, CEA and CA 19-9, are of integral importance in the diagnosis of pancreatic cancer. Along with this, an elevation in the liver function tests, bilirubin levels, amylase, and lipase are also reported. (12)

Formatted: Font color: Red

Formatted: Font color: Red

Similarly, vocal paralysis could be either unilateral or bilateral. In both cases, it is accompanied by dysphonia, dysphagia, and shortness of breath.

In the majority of the cases, laryngeal paralysis occurs secondary to trauma of the recurrent laryngeal nerve, which occurs due to surgery, trauma, or cancers. (13)

Formatted: Font color: Red

Formatted: Font color: Red

Iatrogenic trauma during thyroidectomy is one of the most common causes of recurrent laryngeal nerve paralysis. Primary malignancy or metastases of the lung or larynx come secondary to it.

Both pancreatic adenocarcinoma and vocal cord paralysis require extensive investigations before the cause of either of them gets confirmed. For pancreatic malignancy, multidetector computed tomography (MDCT) is the modality of choice. It does not only allow for the detection and diagnosis of the disease but also keeps an eye on any perivascular extensions or distant metastases. PET CT Scan is also useful for determining the extent of the disease in the majority of cases. (14)

Formatted: Font color: Red

Formatted: Font color: Red

Regarding the treatment plans, surgery is the final resort of treatment. However, neoadjuvant therapy (chemotherapy or radiotherapy) is also employed in some cases. Since it is performed prior to surgery, it can help decrease the likelihood of distant disease or metastases in the patient. However, the timing is to be kept in check because the disease could also turn unresectable by the time this neoadjuvant therapy ends. (15)

Formatted: Font color: Red

Formatted: Font color: Red

However, supportive treatment always seems to work best in favor of the patient in palliating some of the symptoms for the time being.

CONCLUSION

Pancreatic cancer is one of the most common cancers worldwide. This cancer has a higher than usual death rate, and in the majority of the cases, people usually succumb to their symptoms before they are even started on any kind of therapy.

Pancreatic cancers are well-known for spreading to distant sites, that is, metastasizing, and this is the usual scenario where the symptoms from other regions force the attention of the affected person towards this diagnosis.

In this case, the patient's initial presenting complaints were related to his vocal cord paralysis. It was only until later that it was found that the vocal cord paralysis occurred due to the spread of cancer to his recurrent laryngeal nerve. And this was not all. The patient had multiple metastases at different sites, and for this, he was started on chemotherapy.

The patient showed a good response to chemotherapy, and there was a decrease in the size of distant metastases. This was a favorable prognosis, and it is expected that if it remains the same, the patient will soon become capable of achieving remission from his therapy.

REFERENCES:

Formatted: Font color: Red

1. Vareedayah AA, Alkaade S, Taylor JR. Pancreatic Adenocarcinoma. *Mo Med* [Internet]. 2018 [cited 2022 Jun 20];115(3):230–5. Available from: <https://www.ncbi.nlm.nih.gov/pmc/articles/PMC6140147/>
2. Puckett Y, Garfield K. Pancreatic Cancer. In: *StatPearls* [Internet]. Treasure Island (FL): StatPearls Publishing; 2022 [cited 2022 Jun 20]. Available from: <http://www.ncbi.nlm.nih.gov/books/NBK518996/>
3. Ri S, Kd M, A J. Cancer Statistics, 2017. *CA: a cancer journal for clinicians* [Internet]. 2017 Jan [cited 2022 Jun 20];67(1). Available from: <https://pubmed.ncbi.nlm.nih.gov/28055103/>
4. Early Diagnosis to Improve the Poor Prognosis of Pancreatic Cancer - PMC [Internet]. [cited 2022 Jun 20]. Available from: <https://www.ncbi.nlm.nih.gov/pmc/articles/PMC5836080/>
5. The Epidemiology of Pancreatitis and Pancreatic Cancer - PMC [Internet]. [cited 2022 Jun 20]. Available from: <https://www.ncbi.nlm.nih.gov/pmc/articles/PMC3662544/>
6. Molecular classification of neoplasms of the pancreas - PubMed [Internet]. [cited 2022 Jun 20]. Available from: <https://pubmed.ncbi.nlm.nih.gov/19362631/>
7. Pancreatic cancer: A review of clinical diagnosis, epidemiology, treatment and outcomes - PMC [Internet]. [cited 2022 Jun 20]. Available from: <https://www.ncbi.nlm.nih.gov/pmc/articles/PMC6250924/>
8. Pancreatic Cancer: A Review - PubMed [Internet]. [cited 2022 Jun 20]. Available from: <https://pubmed.ncbi.nlm.nih.gov/34547082/>
9. Diagnosis and management of pancreatic cancer - PubMed [Internet]. [cited 2022 Jun 20]. Available from: <https://pubmed.ncbi.nlm.nih.gov/24784121/>
10. Pancreatic cancer: A review of epidemiology, trend, and risk factors - PubMed [Internet]. [cited 2022 Jun 20]. Available from: <https://pubmed.ncbi.nlm.nih.gov/34366606/>
11. Pathologic classification of “pancreatic cancers”: current concepts and challenges - PubMed [Internet]. [cited 2022 Jun 20]. Available from: <https://pubmed.ncbi.nlm.nih.gov/29307199/>
12. Detection of serum tumor markers in the diagnosis and treatment of patients with pancreatic cancer - PubMed [Internet]. [cited 2022 Jun 20]. Available from: <https://pubmed.ncbi.nlm.nih.gov/15313690/>
13. Williamson AJ, Shermetaro C. Unilateral Vocal Cord Paralysis. In: *StatPearls* [Internet]. Treasure Island (FL): StatPearls Publishing; 2022 [cited 2022 Jun 20]. Available from: <http://www.ncbi.nlm.nih.gov/books/NBK535420/>

14. Brunner M, Wu Z, Krautz C, Pilarsky C, Grützmann R, Weber GF. Current Clinical Strategies of Pancreatic Cancer Treatment and Open Molecular Questions. *Int J Mol Sci*. 2019 Sep 13;20(18):E4543.
15. Pancreatic Adenocarcinoma, Version 2.2017, NCCN Clinical Practice Guidelines in Oncology - PubMed [Internet]. [cited 2022 Jun 20]. Available from: <https://pubmed.ncbi.nlm.nih.gov/28784865/>

Formatted: Font color: Red

UNDER PEER REVIEW