

Case study

“LUNG CANCER: SOLITARY PULMONARY NODULE”

Abstract

A 55-year old, middle-aged man, known for hypertension and dyslipidemia, presented to the OPD with complaints of fever along with a mild dry cough. There was no shortness of breath or chest pain associated with the patient's complaints. Therefore, as a seemingly obvious diagnosis, he was suspected of having a COVID-19 infection.

The man has a positive smoking history of approximately 20 cigarettes per day for 25 years. However, his COVID-19 PCR tests provided two negative results. His chest X-ray was also unremarkable. Apart from some abnormalities in his laboratory analyses, which have been discussed in detail in the coming sections, there seemed to be nothing unusual or out of place with the patient.

However, when a CT scan without contrast was ordered for the patient, the report showed a mass that was approximately 23 x 21 x 16 mm in size. The mass had a soft, tissue-like consistency. It also appeared to have irregular, lobulated margins. This entire mass was seen to be present in the anterior segment of the upper lobe of the left lung.

Apart from this mass, no COVID-19-related consolidations or signs of respiratory distress were seen in this patient.

When the mass was confirmed, a needle-core biopsy was done to find out the nature of it. The biopsy report confirmed that the mass was indeed a moderate-to-poorly differentiated non-small cell carcinoma of the lung, which was consistent with adenocarcinoma with sarcomatoid features. All these aspects of the tumor, with radiological evidence, have been discussed below.

The patient is being supportively managed as of now and is also being kept on a follow-up schedule.

What's worth mentioning, however, is that despite such minor symptoms, the underlying problem could still be serious. If the patient had not gone for an X-ray or CT for their suspected COVID-19 abnormalities, then their case would not have come to a diagnosis and it would have eventually taken a turn for the worse. The whole case, along with the findings and the patient response has been discussed throughout this paper.

Keywords: COVID19, CT scan, Adenocarcinoma, sarcomatoid

INTRODUCTION

A pulmonary nodule, whether solitary or in a group, is defined as, “a discrete pulmonary density, diagnosed radiographically, and measures less than 3 cm. It is most often surrounded by a well-aerated lung, and usually has no associated complaints of pleural effusion or lymphadenopathy.”^[1]

The incidence of solitary pulmonary nodules has been seen to increase over the past few years. Consequently, the same applies to the incidence of these pulmonary nodules being discovered incidentally on CT scans, which is once again, attributed to the increasing usage of these scans in the field of medicine nowadays.^[2]

The cut off value for a small solitary mass present in the pulmonary region is 3 cm. Any mass that exceeds this value and measures more than 3 cm is termed as ‘lung mass ’and is said to be considered lung cancer unless proven otherwise.

Moreover, to be considered solitary, a lung nodule needs to be surrounded by an area of normal parenchyma. There should also be no enlargement of the hilum or signs of pleural effusion, or any associated atelectasis to complicate the case. ^{[3][4]}

The overall incidence of these solitary pulmonary nodules (SPNs) was found to range from 8 to 51% on average. ^[5]

Once a solitary pulmonary nodule has been discovered and its presence confirmed by a CT scan, the next step is to determine the cause behind its occurrence, all the while correlating its existence with the associated and present symptoms in the patient. The subsequent steps consist of characterising the nodule either as benign, malignant, or equivocal as per the radiological characteristics present. The size, morphology, rate of growth, and all the other remaining features help in determining and later on, grading the likelihood of how far along the malignancy has taken over and how far it will go in a patient at a given time.

The evolution and the management of this patient who presents with a solitary pulmonary nodule depends on the positive biopsy result. In case the biopsy comes out to be positive, then the management plan either comprises surgical resection of the nodule or follow-up imaging over a given time period to assess the growth of the nodule until it acquires a size that is suitable for resection. ^[6]

CASE STUDY

A 55-year old, middle-aged man presented to the hospital with complaints of a history of fever and mild dry cough. This cough was uncomplicated in nature, as the patient denied having any shortness of breath or chest pain. Initially, it was suspected that the patient might have a COVID-19 infection but the test results came back negative for it.

This patient has been a known case of hypertension and dyslipidemia for the last 2 years. However, he was a heavy smoker. His smoking history came out to be positive in the sense that he admitted to smoking at least 20 cigarettes per day for the last 25 years. He was tested for COVID-19 twice, and both times, his tests came out to be negative. NECT-Thorax also came out negative and failed to result in reporting any findings that were consistent with COVID-19.

When a chest X-ray was ordered, it came out to be normal and no remarkable findings were seen. Later on, since the symptoms did not seem to subside, the patient was ordered to go for a chest CT scan without contrast to determine the actual problem and to see if it could be of any help. This CT showed that there was a presence of a mass in the anterior segment of the upper lobe of the left lung. The mass measured approximately 23 x 21 x 16 mm, and had irregular lobulated margins. Overall, the consistency of the mass appeared to be soft and tissue-like.

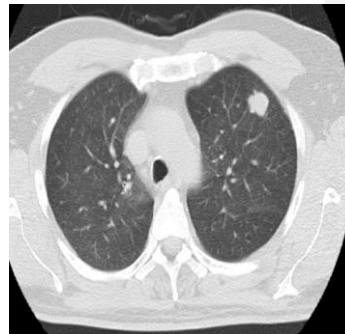
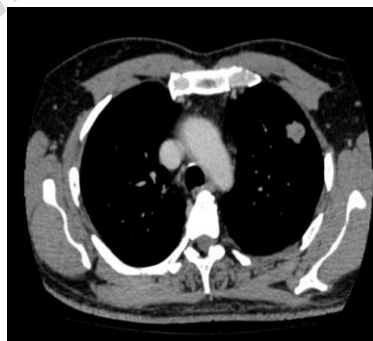
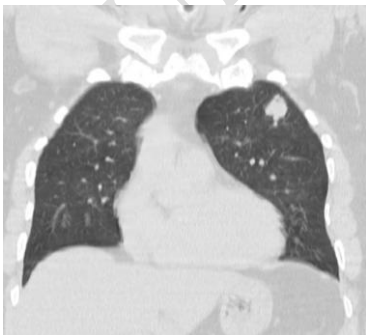
Figure 1: Chest computed tomography scan showing the lung nodule

Comment [M1]: Suggestion: the image is given a description of the image with the number or alphabet a, b, c

Examinations, Investigations, and Findings:

From this point forth, all further examinations, lab reports, and biopsies that were carried out revolved around this nodule to see whether it was resectable or not. It was also to be decided if this nodule was malignant or not, and for doing that, only a needle-core biopsy was the ideal option.

After the initial non-contrast CT scan confirmed the presence of a nodule, a contrast CT scan of the patient’s chest was ordered, and the reports of this scan were summarized as follows:

“There is re-demonstration of a nodule (2.1 x 2.0 x 1.7cm) in the anterior segment of the left upper lobe, which shows mild homogeneous enhancement in the post-contrast scan.”

Some laboratory investigations were also ordered. Their details have been enclosed as follows:

Table 1 : Some laboratory investigations

WBC	> 16,000 (88% Neutrophilia)
CRP	Increased (150)
Procalcitonin	Increased (5)
Ferritin	Increased (> 600)
D-Dimer	Positive
Creatinine	High then improved (from 166 to 127)

Needle Core Biopsy:

The mass in the upper lobe of the left lung was subjected to a needle core biopsy. This biopsy came back positive and showed results consistent with the findings of a moderate-to-poorly differentiated non-small cell carcinoma. The tumor was consistent with adenocarcinoma with sarcomatoid features.

Moreover, it also revealed the following:

PDL1 - the TPS (Tumor proportion score) is 95%

Comment [M2]: Explained PDL1..??

Case of Lung Cancer: **pT1c (3 cm) N0. Stage IA3**

ALK BRAF EGFR ERBB2 HRAS KRAS MET NRAS NTRK1 RET ROS1: NEGATIVE

Comment [M3]: Explained the meaning of this sentence

Comment [M4]: no need to capitalize

Thus, in the light of these reports and analysis, the patient was confirmed as having lung cancer.

As per the current WHO classification (2014) of lung tumors, pleomorphic lung carcinoma is a poorly differentiated non-small cell carcinoma and one of the histologic subtypes of sarcomatoid lung carcinoma.

The basis of diagnosis was as follows:

- **Station 11:**
0/1 lymph nodes.
- **Station 10:**
0/2 lymph nodes.
- **Station 5:**
0/3 lymph nodes.

- **Left Upper Lobe Lung:**

Pleomorphic carcinoma comprising adenocarcinoma intermixed with a poorly-differentiated spindle cell component. **pT1c N0.**

PET Scan:

Hypermetabolic left upper lobe lung lesion, consistent with patient's known malignancy (T1c).

No evidence of FDG-avid nodal or distant metastasis.

Tiny right upper lobe lung nodule, but it was too small to be characterized by PET and so, was declared nonspecific. To follow.

PET/CT Staging:

T1cN0M0, stage IA.

Management & Treatment:

For the management and treatment plan of the patient, the reviewed NCCN Guidelines Version I (2022) were kept under revision.

It was decided that because the patient was pT1c (3 cm), N0 (4 cm), he would not be an ideal candidate for adjuvant chemotherapy.

And because the patient had negative margins, all of which were clear by more than 2 cm. No immunotherapy was indicated either.

The current treatment plan devised was a mere observation of the patient and seeing if his symptoms progressed further or intensified for the worse. A plan was also made for the patient to be kept on a follow-up plan by carrying out repeat CT scans every 6 months for the next 2 years.

Comment [M5]: explained PET and FDG...???

DISCUSSION

Solitary pulmonary nodules have become an increasingly common finding in the context of the most common lung-related pathologies in the developing world today. These nodules are frequently encountered on both chest radiographs as well as computed tomography (CT) scans. It has also been commonly observed that most of these nodules, measuring up to 1-2 mm in size, were incidentally discovered in smokers and mostly those who were 50 years of age or older. ^[7]

On CT scans, these nodules appear either as a rounded or irregular opacity, which could be either well-defined or ill (poorly)-defined, and usually measure up to 3 cm. Any opacity or nodules that measure less than the value of 3 mm is termed as a 'micronodule' whereas those measuring between 5-8 mm are termed as 'acinar' variants. ^[8]

According to the American College of Physicians, further assessment of a nodule should be based on the two most important factors: the size of the nodule and the background history of the patient, which undoubtedly helps in determining whether the patient really is at risk of developing cancer or not.

The risk of developing lung cancer from solitary pulmonary nodules is approximately 10 times in non-smokers and about 15-35 times higher in smokers. ^[9]

However, the presence of a solitary pulmonary nodule does not always indicate malignancy. It could also point towards other diagnosis such as certain benign conditions including hamartomas and granulomas, and some other malignancies such as small-cell carcinoma, non-small cell carcinoma, or maybe metastasis from other distant sites that have come to reside and multiply in the lungs. Sometimes, the development of a nodule can also be attributed to infection or congenital etiology.

Following the diagnosis of this nodule, the next important step is to opt for follow-up imaging of the nodule to see if it is growing or not. A rapidly growing mass becomes a source of concern, and so, needs to be checked urgently.

There are several treatment options that can be considered in these patients. Following a diagnostic biopsy, the surgical resection of a nodule that has been confirmed to be malignant is the best course of action that could be followed in such patients to prolong their life and ensure their survival, provided that the prognosis is favorable and the tumor is present at a treatable and resectable stage. ^[10]

CONCLUSION

Lung cancer is one of the most common forms of cancers that are prevalent in the developing world today. However, despite being one of the most common malignancies, they are often diagnosed incidentally.

However, if a proper course of action is followed from there and then, then these tumors can be managed easily and steps can be taken to assure that the patient gets to live a favorable life. Surgical resection along with follow-up with diagnostic imaging is so far considered to be the best course of action for such malignancies.

REFERENCES:

1. Broaddus, V. C., Ernst, J. D., King Jr, T. E., Lazarus, S. C., Sarmiento, K. F., Schnapp, L. M., ... & Gotway, M. B. (Eds.). (2021). Murray & Nadel's textbook of respiratory medicine e-book. Elsevier Health Sciences.

Comment [M6]: References: update ancient references (number 2, 10) with the latest references if there are at least the last 5-10 years

2. Comstock, G. W., Vaughan, R. H., & Montgomery, G. (1956). Outcome of solitary pulmonary nodules discovered in an x-ray screening program. *New England Journal of Medicine*, 254(22), 1018-1022.
3. Loverdos, K., Fotiadis, A., Kontogianni, C., Iliopoulou, M., & Gaga, M. (2019). Lung nodules: A comprehensive review on current approach and management. *Annals of thoracic medicine*, 14(4), 226–238. https://doi.org/10.4103/atm.ATM_110_19
4. Gould MK, Donington J, Lynch WR, Mazzone PJ, Midthun DE, Naidich DP, et al. Evaluation of individuals with pulmonary nodules: When is it lung cancer? Diagnosis and management of lung cancer, 3rd ed: American College of Chest Physicians Evidence-Based Clinical Practice Guidelines. *Chest*. 2013;143:e93S–120S.
5. Swensen SJ, Jett JR, Hartman TE, Midthun DE, Sloan JA, Sykes AM, et al. Lung cancer screening with CT: Mayo Clinic experience. *Radiology*. 2003;226:756–61.
6. Ahn MI, Gleeson TG, Chan IH, McWilliams AM, Macdonald SL, Lam S, et al. Perifissural nodules seen at CT screening for lung cancer. *Radiology*. 2010;254:949–56.
7. Khan, A. N., Al-Jahdali, H. H., Irion, K. L., Arabi, M., & Koteyar, S. S. (2011). Solitary pulmonary nodule: A diagnostic algorithm in the light of current imaging technique. *Avicenna journal of medicine*, 1(2), 39–51. <https://doi.org/10.4103/2231-0770.90915>

Comment [M7]: update the ancient this reference

8. Hansell DM, Bankier AA, MacMahon H, McLoud TC, Müller NL, Remy J. Fleischner Society: glossary of terms for thoracic imaging. *Radiology*. 2008;246:697–722.
9. Tan BB, Flaherty KR, Kazerooni EA, Iannettoni MD. American College of Chest Physicians. The solitary pulmonary nodule. *Chest*. 2003;123(1 Suppl):89S–96S.
10. The health consequences of smoking: a report of the surgeon general. Atlanta, GA: U.S. Department of Health and Human Services, Centers for Disease Control and Prevention, National Center for Chronic Disease Prevention and Health Promotion, Office on Smoking and Health; 1982. U.S. Department of Health and Human Services.

UNDER PEER REVIEW