

## Original Research Article

### ILEUM HISTOARCHITECTURE FOLLOWING ASPARTAME CONSUMPTION: ASSESSMENT OF ACTIONS OF *MORINGA OLEIFERA* SEED EXTRACT

#### ABSTRACT:

This study aims to determine the effect of *Moringaoleifera* seedextract on ileum histoarchitecture following aspartame consumption. Twenty-seven adult male Albino Wistar rats were used for the study. They were divided into nine groups comprising of: group A (control), administered distilled water;group B, given 0.4ml (low dose) aspartame; group C, given 1.5ml (high dose) aspartame;group D1, given 0.6ml (low dose) aspartame for the first three weeks followed by 1.5ml (low dose) ethanolic extract of *Moringaoleifera*seed on the fourth week; group D2 given 0.5ml (low dose) aspartame for the first three weeks followed 1.30ml (low dose) n-hexane extract of *Moringaoleifera*seed on the fourth week; group E1, given 1.5ml (high dose) aspartame for the first three weeks and on the fourth week 2.5ml (high dose) ethanolic extract of *Moringaoleifera*seed; group E2, given 1.5(high dose) aspartame for the first three weeks and on the fourth week 3.0 ml (high dose) n-hexane extract of *Moringaoleifera*seed; group F1 given 1.4ml (high dose) aspartame followed by 2.8ml (high dose) ethanolic extract of *Moringaoleifera*seed for four weeks; group F2, given 1.3ml (high dose) aspartame followed by 2.5ml (high dose) n-hexane extract of *Moringaoleifera*seed for four weeks. Weight measurement of rats wastaken once a week throughout the twenty eight days duration of the study. Following anaesthetization, their ileum were harvested and fixed in 10 % buffered formalin. Hematoxylin and Eosin (H&E) staining technique was adopted for routine histological procedure.Data were expressed as mean  $\pm$  standard error of mean (M  $\pm$  SEM) and subjected to one-way analysis of variance (ANOVA).At 95 % confidence interval, *P* is significant (*P*< 0.05). There was a significant increase (*P*= 0.05) in body weight of both the control and the experimental groups as the experiment progressed. Histological findings revealed that aspartame both in low and high doses has disruptive effects on the histoarchitecture of ileum and high dose ethanolic extract of *Moringaoleifera* seed has the capacity to ameliorate the effects.Hence, caution is needed in aspartame consumption.

**Key words:** Albino Wistar Rats. Aspartame.Ethanolic Extract *MoringaOleifera*seed. N – Hexane Extract *Moringaoleifera*seed.

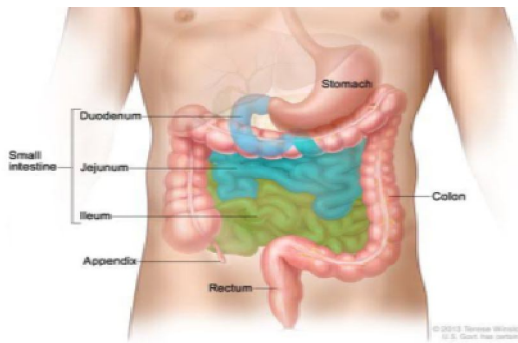
#### INTRODUCTION

Ileum: The second part of the small intestine, the jejunum, begins at the duodenojejunal flexure where the gastrointestinal tract resumes an intraperitoneal course. The third part of the small intestine, the ileum, ends at the ileocecal junction, the union of the terminal ileum and the cecum. Together, the jejunum and ileum are 6 to 7 m long, the jejunum constituting approximately

Comment [U1]: approximately

two fifths and the ileum approximately three fifth of the intraperitoneal section of the small intestine (Moore,2014).Most of the jejunum lies in the left upper quadrant (LUQ) of the **infracolic** compartment, whereas most of the ileum lies in the right lower quadrant (RLQ). The terminal ileum usually lies in the pelvis from which it ascends, ending in the medial aspect of the cecum. Although no clear line of demarcation between the jejunum and ileum exists, they have distinctive characteristics that are surgically important. The mesentery is a fan-shaped fold of peritoneum that attaches the jejunum and ileum to the posterior abdominal (Moore,2014).

**Comment [U2]:** infrasonic (or) infracolic?



**Image1.** Part of the Small Intestine

**Source:** (Moore,2014).

**Comment [U3]:** figure not image

**Comment [U4]:** The figure needs to be arranged, It is must place in the center of the page.

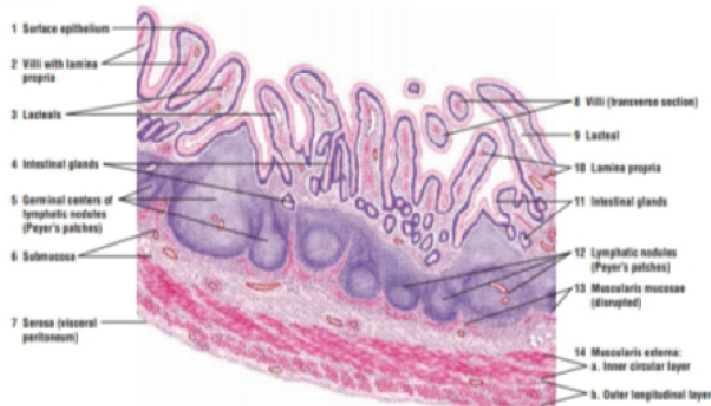**Comment [U5]:** This word must be delete.

Histologically, the mucosa is lined by simple columnar epithelium comprising enterocytes and goblet cells. Underneath lies a connective tissue layer (lamina propria) and a muscle layer (lamina **muscularis** mucosae). Compared to the rest of the small intestine the circular folds are rather flat and the villi relatively short. The submucosa contains blood vessels, lymph nodes and the Meissner's plexus. The **muscularis** consists of an inner circular and outer longitudinal muscle layer. The ileum is entirely covered by serosa from the outside. It is made up of simple squamous epithelium and a connective tissue layer underneath (lamina propria serosae).A characteristic feature of the ileum is the Payer's patches lying in the mucosa. It is an important part of the GALT (gut-associated lymphoid tissue). One patch is around 2 to 5 centimeters long and consists of about 300 aggregated lymphoid follicles and the parafollicular lymphoid tissue. The dome-like bulge above one follicle is called dome area. M cells

**Comment [U6]:** muscular is

**Comment [U7]:** muscular is

(microfold cells) are found in the dome epithelium which are counted among the FAE cells (follicle-associated epithelial cells). Their function is to pick up antigens from the intestinal lumen and transport them to the antigen-presenting cells (APC) (Alexandru, 2017).



**Image 2.** Small intestine: ileum with lymphatic nodules (Peyer's patches) (transverse section).  
Stain: haematoxylin and eosin. Low magnification.  
**Source:** Eroschenko, 2005.

**Comment [U8]:** It needs more clarification.

**Comment [U9]:** Figure 2.

Aspartame is an intense sweetener which is almost 180 to 200 times sweeter than sucrose, with a respective low calorific value. Aspartame is widely used in more than 6000 products worldwide with a huge commercial outcome under many brand names (Henkel, 2007). Aspartame is very much popular owing to its reduced costs, low caloric intake, attractive advertisements and assurance to contribute in weight management (Abu, 2016). The popularity of aspartame among consumers lies down within the problems associated with sucrose consumption (Tandel, 2011). Aspartame helps in limiting the sucrose intake in the form of substituting sugar and releases very low amount of energy respectively. It is metabolized more slowly than sucrose, allowing blood sugar levels to remain more stable over time. Individuals with reactive hypoglycemia produce an excess of insulin after quickly absorbing glucose into the bloodstream (Bellisle, 2007). This causes their blood glucose levels to fall below the amount needed for physiological function. Like diabetic, high glycemic food avoidance often force them

to choose artificial sweeteners as an alternative. (Bentley, 2015). For these reasons aspartame increasingly introduced into commonly consumed foods such as diets sodas, cereals, and sugar-free desert, yoghurt, chewing gums, mouth fresheners nutritional supplements are being recommended for weight loss and for individuals suffering from glucose intolerance and type 2 diabetes mellitus (Portela *et al.*, 2014). Aspartame is harmful and toxic to human beings, its toxicity is due to its corrosive properties, which can damage internal organs. It tends to accumulate in the ileum, which can lead to Cohn's disease and ulcerative colitis. (Bentleg, 2015).

*Moringaoleifera* belongs to a monogeric family of shrubs and tree, Moringaceae. The plant possesses many valuable properties of great scientific interest. These include the high protein content of the leave twigs and stems, the high protein and oil content of the seeds, the large number of unique polypeptides in the seeds that can bind to many moieties; the presence of growth factors in the leaves. ( Foidlet *al*, 2001; Oduro *et al*, 2008). *Moringaoleifera* is a fairly large tree native to north India. Almost all part of the tree is eaten or used as ingredients in traditional herbal medicines. They are strong natural antioxidants; they also display other medicinal properties like anti-inflammatory, chemo preventive (Morales, 2015). *Moringaoleifera* leaves have essential amino acids, including the sulphur-containing amino acids in higher levels ( Makkar and Becker, 1997) than those recommended by the Food and Agricultural Organisation (FAO, 1985) and with pattern similar to those of soya bean seeds (Foidlet *al*, 2001).

*Moringaoleifera* leaves are always available throughout the whole year (Price, 1985). *Moringaoleifera* is widely used for its nutritional and medicinal properties. It is packed with antioxidants, substances that can protect cells from damage and boost the immune system; though studies have also indicated that *Moringaoleifera* at about 2000 mg/kg is toxic (Millan, 2015) and we intend not to reach this level in our research.

Many studies on *Moringaoleifera* had been carried out, but there is paucity of data on studies making use of *Moringaoleifera* seed via its ethanolic and n-Hexane extraction. Hence, this study aims: to determine the effect of aspartame on the histoarchitecture of ileum of adult male Albino Wistar rats; to determine the effect of aspartame and *Moringaoleifera* seed extract on the body weight of adult male Albino Wistar rats; to evaluate the effect of ethanolic extract of *Moringaoleifera* seed on ileum histology following aspartame administration in adult male Albino Wistar rats; and to evaluate the effect of n-Hexane extract of *Moringaoleifera* seed on ileum histology following aspartame administration in adult male Albino Wistar rats.

## METHODOLOGY

Twentyseven adult male Albino Wister rats were used for the study. They were fed pelletized grower mash and clean drinking water ad libitum. The rats were kept under standard

Comment [U10]: *M. oleifera*.

Comment [U11]: *M. oleifera*

Comment [U12]: *M. oleifera*

Comment [U13]: *M. oleifera*

Comment [U14]: *M. oleifera*

Comment [U15]: *M. oleifera*

Comment [U16]: *M. oleifera*

Comment [U17]: *M. oleifera*

Comment [U18]: *M.oleifera*

Comment [U19]: *M. oleifera*

Comment [U20]: Experiments should be separated by several paragraphs, and references should be made to the references that have been cited.

room temperature. They were housed in nine wooden cages, measuring about 18 by 12 inches with wire gauze covers and sawdust as beddings. The animals were handled in compliance with applicable guidelines for the care and use of laboratory animals.

Comment [U21]: Need reference here

The *Moringaoleiferapods* were purchased from the market. The pods were broken and the seeds removed and well ground using a manual grinder. The Soxhlet method of extraction was used. Typically, Soxhlet extraction is used when the desired compound has a limited solubility in a solvent and the impurity is insoluble in that solvent. It allows for unmonitored and unmanaged operation while efficiently recycling a small amount of solvent to dissolve a large amount of material. 80% of ethanol was added to 500g of the ground seed; 80% of N-hexane was added to a separate 500g of the ground seed. Both extracts were gotten by filtration, stored in a glass beaker, covered with foil and placed in the fridge to preserve the efficacy of the extract.

Comment [U22]: *M. oleifera*

Comment [U23]: Need reference here

The aspartame was also gotten from the market. The aspartame was weighed using an electric weighing balance in the laboratory. The aspartame used was 1.0g and was dissolved in 50ml of distilled water. The dissolved aspartame was administered to the rats according to their required dose based on weight. This procedure was carried out daily for 28 days. Group A (control), were administered distilled water; group B, given 0.4ml (low dose) aspartame; group C, given 1.5ml (high dose) aspartame; group D1, given 0.6ml (low dose) aspartame for the first three weeks followed by 1.5ml (low dose) ethanolic extract of *Moringaoleiferaseed* on the fourth week; group D2 given 0.5ml (low dose) aspartame for the first three weeks followed 1.30ml (low dose) n-hexane extract of *Moringaoleiferaseed* on the fourth week; group E1, given 1.5ml (high dose) aspartame for the first three weeks and on the fourth week 2.5ml (high dose) ethanolic extract of *Moringaoleiferaseed*; group E2, given 1.5 (high dose) aspartame for the first three weeks and on the fourth week 3.0 ml (high dose) n-hexane extract of *Moringaoleiferaseed*; group F1 given 1.4ml (high dose) aspartame followed by 2.8ml (high dose) ethanolic extract of *Moringaoleiferaseed* for four weeks; group F2, given 1.3ml (high dose) aspartame followed by 2.5ml (high dose) n-hexane extract of *Moringaoleiferaseed* for four weeks.

Comment [U24]: *M. oleifera*

Comment [U25]: *M. oleifera*

Comment [U26]: *M. oleifera*

Comment [U27]: *M. oleifera*

Comment [U28]: *M. oleifera*

Comment [U29]: *M. oleifera*

Weight measurement of rats was taken once a week throughout the twenty eight days duration of the study. Data were expressed as mean  $\pm$  standard error of mean ( $M \pm SEM$ ) and subjected to one-way analysis of variance (ANOVA). At 95 % confidence interval,  $P$  is significant ( $P < 0.05$ ).

Following anaesthetization, 1000ml of normal saline was perfused to clear the blood impurities, the ileum harvested and fixed in 10 % buffered formalin. Hematoxylin and Eosin (H&E) staining technique was adopted for routine histological procedure. The tissue processing involved the following stage: dehydration, clearing, infiltration, embedding, sectioning (microtomy), staining and mounting. The processed tissues were then subjected to microscopy. The Processed tissues were viewed under the light microscope and photomicrographs from control and experimental groups were obtained using the microscope's camera attached to the computer.

Comment [U30]: Need reference here.

There was no conflict of interest among the authors. Ethical approval was provided.

## RESULTS

### Findings

**1.1. Phytochemical analysis of *Moringaoleifera*:** The extract from the *Moringaoleifera* was screened for the presence of secondary metabolites using standard methods (Odebiyi and Sofowora, 1978). The result is shown in the table below:

Comment [U31]: *M. oleifera*

Comment [U32]: *M. oleifera*

**Table 1. Phytochemical results.**

TEST	OBSERVATION	INFERENCE
<b>Alkaloids</b>		
1. Dragendof	Red precipitate observed	++
2. Mayer	Red precipitate observed	++
<b>Tannin</b>	Bluish-black coloration observed	+++
<b>Saponin</b>	Persistent frothing observed	++
<b>Flavenoid</b>	Orange precipitate observed	++
<b>Cardiac glycoside</b>		
1. Salkawski	Reddish-brown ring	+++
2. KellLillirin	Brown ring observed at the interphase	++
3. Lieberman	Violet ring observed at the interphase	++

**KEY:** - = absent, + = slightly present, ++ = moderately present, +++ = heavily present.

### 1.2. Comparison of changes in body weight of adult male albino Wistar rats

The result of the changes in body weight following the administration of aspartame and *Moringa oleifera* seed extract for twenty-eight days is shown in table 2. There was progressive increase in the weight of both control and experimental rats, contrary to the widely held belief that artificial sweeteners, example, aspartame, are of low calories, hence, implicated in weight reduction and maintenance.

Comment [U33]: *M. oleifera*

**Table 2. Comparison of Changes in Body Weight of Adult Male Albino Wistar Rat in Grams(gm)**

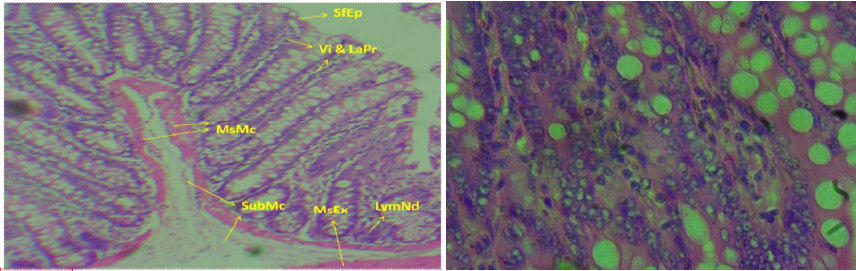
Groups	Week 1	Week 2	Week 3	Week 4
A	205.50±6.50	220.50±8.50	313.00±8.00	313.00±7.00
B	143.00±5.13	144.50±5.50	238.00±9.00	242.00±10.00
C	182.33±1.20	192.33±1.45	288.00±3.21	292.33±4.18
D1	182.00±9.50	188.67±10.68	286.33±13.45	289.00±14.01
D2	151.67±1.20	161.33±1.45	254.67±4.67	255.67±4.41
E1	144.33±3.84	155.67±2.33	244.67±6.39	245.33±7.31
E2	174.67±4.98	191.00±6.51	282.67±6.94	284.00±9.07
F1	179.33±8.69	197.00±10.82	281.33±10.73	276.67±8.97
F2	154.67±4.81	171.33±4.37	253.00±3.51	248.67±3.84
	F = 13.50 P = 0.000	F = 12.72 P = 0.000	F = 9.60 P = 0.000	F = 9.12 P = 0.000

Values are expressed as mean ± standard error of mean (S±SEM). At 95% confidence interval, P is significance (P < 0.05)

### 1.3. Hematoxylin and Eosin (H&E) Method for General Demonstration of Ileum

Histological findings revealed that aspartame both in low and high doses has disruptive effects on the histoarchitecture of ileum; and only high dose ethanolic extract of *Moringa oleifera* seed has the capacity to ameliorate the effect. The figures adopted as low and high doses were calculated and determined based on weight of the rats. The figures representing dosage of aspartame consumed were implicated in the inflammation of the surface epithelium of the ileum and atrophy of the intestinal villi and lamina propria, which predisposes to apoptosis.

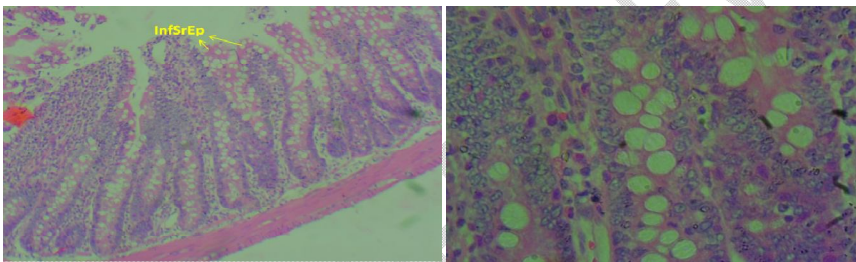
Comment [U34]: *M. oleifera*



**Figure I. (H&E method, X100). Figure II. (H&E method, X400).**

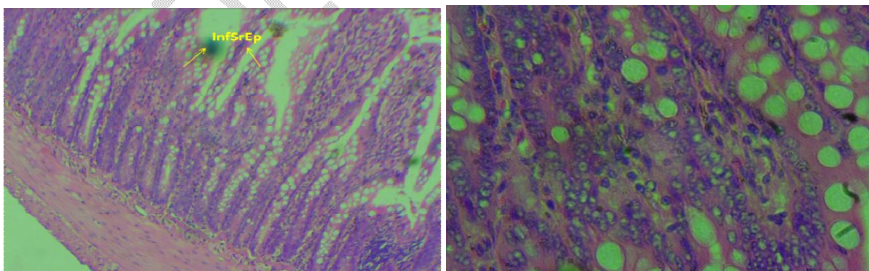
Transverse section of the ileum of adult male Albino Wistar rat given distilled water **Group A (Control). (H&E method).** Section revealed some features typical of normal ileum, Surface epithelium (SfEp), Villi and Lamina propria (Vi&LaPr), Lymphoid nodule (Payers patch) (LymNd). Muscularis externa (MsEx), Serosa (Srs), Muscularis mucosa (MsMc), Submucosa (SubMc).

**Comment [U35]:** The numbering of the figures is rearranged and is in English, not Latin.



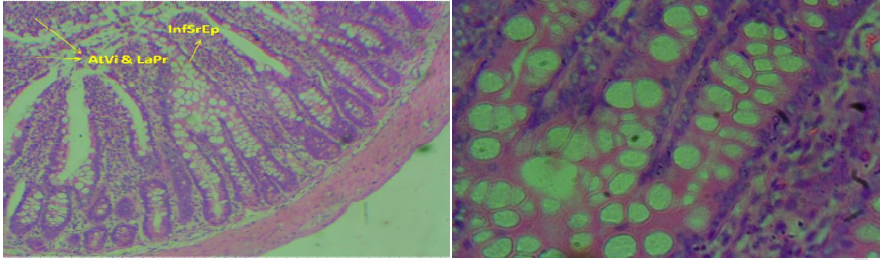
**Figure III:(H&E method, X100). Figure IV:(H&E method, X400).**

Transverse section of the ileum of adult male Albino Wistar rat given 0.4ml (low dose) aspartame for 4 weeks (28 days) **Group B. (H&E method, X100).** Section revealed: Inflammation of Surface epithelium (InfSrEp). **Inference:** Slightly affected.



**Figure V:(H&E method, X100). Figure VI:(H&E method, X400).**

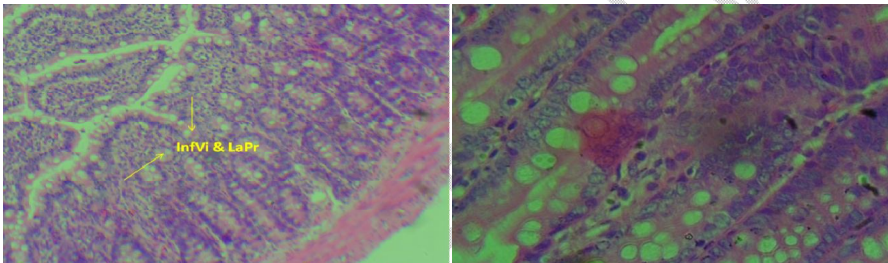
Transverse section of the ileum of adult male Albino Wistar rats given 1.5ml (high dose) aspartame for 4 weeks (28 days). **Group C. (H&E method).** Section revealed: Inflammation of Surface epithelium (InfSrEp). **Inference:** Slightly affected



**Figure VII. (H&E method, X100). Figure VIII. (H&E method, X400).**

Transverse section of the ileum of adult male Albino Wistar rats given 0.6ml (low dose) aspartame for the first 3 weeks and on the fourth week, 1.50 ml (low dose) ethanolic extract of *Moringa oleifera* seed only. **Group D1. (H&E method, X100).** Section revealed. Inflammation of Surface epithelium (**InfSEp**), Atrophy of the Villi and Lamina propria (**AtVi&LaPr**). **Inference:** Severely affected.

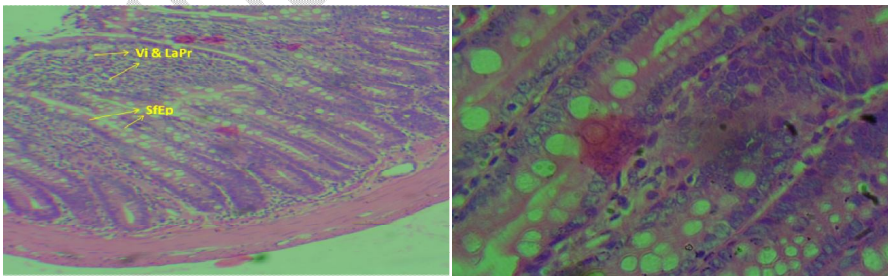
Comment [U36]: *M. oleifera*



**Figure IX. (H&E method, X100). Figure X. (H&E method, X400).**

Transverse section of the ileum of adult male Albino Wistar rats given 0.5ml (low dose) aspartame for the first 3 weeks and on the fourth week, 1.30 ml (low dose) n-Hexane extract of *Moringa oleifera* seed only. **Group D2. (H&E method, X100).** Sections revealed. Inflammation of villi and lamina propria (**InfVi&LaPr**). **Inference:** Slightly affected

Comment [U37]: *M. oleifera*

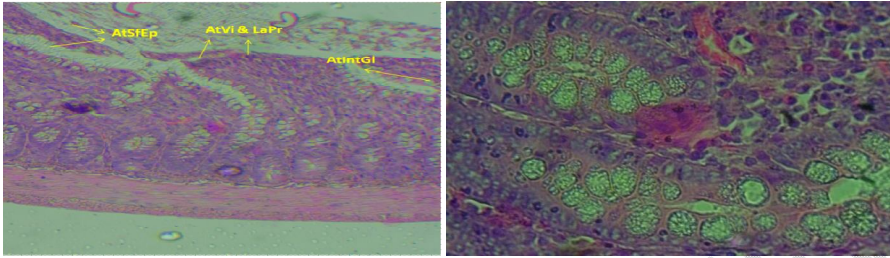


**Figure XI. (H&E method, X100). Figure XII. (H&E method, X400).**

Transverse section of the ileum of adult male Albino Wistar rats given 1.3ml (high dose) aspartame for the first 3 weeks and on the fourth week, 2.5ml (high dose) ethanolic extract of *Moringa oleifera* seed only. **Group E1. (H&E method, X100).** Section revealed

Comment [U38]: *M. oleifera*

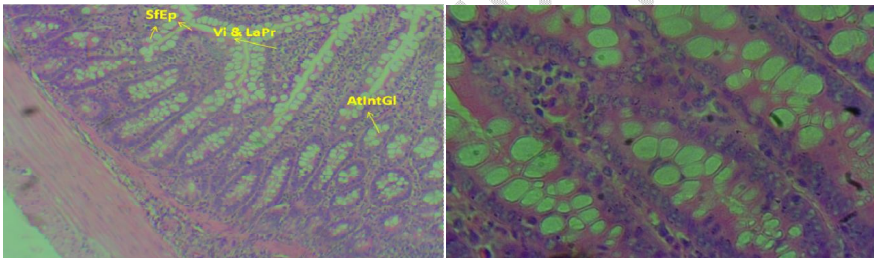
intact: Surface epithelium (SfEp), Villi and Lamina propia (Vi&LaPr). **Inference:** Not affected



**Figure XIII.** (H&E method, X100). **Figure XIV.** (H&E method, X400).

Transverse section of the ileum of adult male Albino Wistar rats given 1.5ml (high dose) aspartame for the first 3 weeks and on the fourth week, 3ml (high dose) n-Hexane extract of *Moringaoleiferaseed* only. **Group E2.** (H&E method, X100). Section revealed: Atrophy of villi and lamina propria (AtVi&LaPr), atrophy of surface epithelium (AtSfEp) and atrophy of intestinal glands (AtIntGI). **Inference:** Severely affected

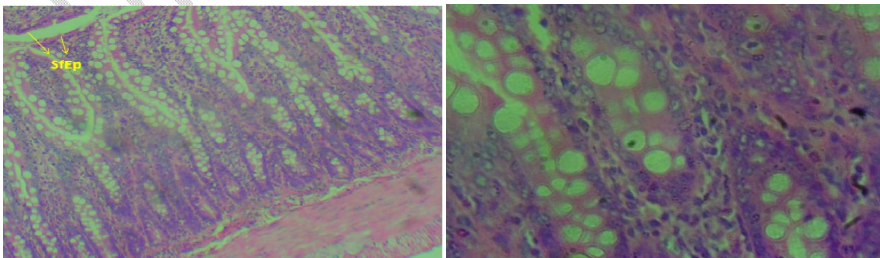
Comment [U39]: *M. oleifera*



**Figure XV.** (H&E method, X100). **Figure XVI.** (H&E method, X400).

Transverse section of the ileum of adult male Albino Wistar rats given 1.4ml (high Dose) aspartame followed by 2.8ml (high dose) ethanolic extract *Moringaoleiferaseed* for four weeks. **Group F1.** (H&E method, X100). Section revealed intact: Villi and lamina propria (Vi&LaPr), Surface epithelium (SfEp) and Intestinal glands (IntGI). **Inference:** Unaffected

Comment [U40]: *M. oleifera*



**Figure XVII.** (H&E method, X100).

**Figure XVIII.** (H&E method, X400).

Transverse section of the ileum of adult male Albino Wistar rats given 1.3ml (high dose) aspartame followed by 2.5ml (high dose) n-Hexane extract *Moringaoleifera* seed for four weeks. **Group F2. (H&E method, X100)** Section revealed: Slight inflammation of Surface epithelium (**InfSfEp**). **Inference:** Slightly affected

Comment [U41]: *M. oleifera*

## REFERENCES

- Abu Taweel G.M. (2016). Effect of monosodium glutamate and aspartame on the behavioural and biochemical parameters of albino mice. *American Journal Biotech* 15(15): 601-612.
- Alexandru, Sieroslawska (2017). Histology of the Ileum. Histology of kenhub – Wurznetstrabe 154a
- Aparna, S., Oluwatobi, O., Zaynub, G., Benjamin, F., Joanne, M., and Havovi, C. (2020). Artificial Sweeteners Disrupt Tight Junctions and Barrier Function in the Intestinal Epithelium through Activation of the Sweet Taste Receptor, T1R3. *Nutrients*.12(6): 1862. doi: 10.3390/nu12061862
- Bellisle F., Altenburg de Assis Felix B., Prezxlasi P., Galan P., Guy. Grand B., Drewpiuwski. (2007). Low-energy substitutes for sugars and fats in the human diet: impact on Nutritional regulation. *Neuroscience behaviour* 18-197-205.
- Bentleg, E. and Mackee, M. (2015). A qualitative investigation into general practitioner views on prescribing sugar free medicines for children. *Journal of Health Education* 8:819.
- Eroschenko, V. P. (2005). Di Fiore's atlas of histology with functional correlations. — 10th ed
- Foidl, N. and Becker, K. (2001). What development potential for *Moringa* products? A conference on the potential of *Moringaoleifera* for Agricultural and industrial uses. October 20<sup>th</sup> – November 2<sup>nd</sup> 2001. Dar Es Salaam.
- FAO.(1985). Energy and Protein Requirements. Report of a Joint FAO/WHO/UNU Expert Consultation Meeting Series, N.724, Geneva, Switzerland.
- Guo S., Nighot M., Al-Sadi R., Alhmoud T., Nighot P., Ma T.Y. (2015). Lipopolysaccharide Regulation of Intestinal Tight Junction Permeability is Mediated by TLR4 Signal Transduction Pathway Activation of FAK and MyD88. *J. Immunol.* ;195:4999–5010. doi: 10.4049/jimmunol.1402598.
- Henkel, J. (2007). Sugar Substitutes Americans opt for sweetness and lit. *American Journal of food consumption* 3(6): 12-16.

- Hunty, De La., Gibson, S., and Ashwell, M. (2005). A review of the effectiveness of aspartame in helping with weight control. *Nutrition Bulletin*. 31(2):115-128. DOI: 10.1111/j.1467-3010.2006.00564.x
- Isabela, A.F., Caroline, A.B., Isabel, T. C., Sergio, R.P., Marcelo, d. V., Maria, I.R., Maria, A.P., and Salvador, P. (2021). Long-Term Aspartame Administration Leads to Fibrosis, Inflammation Activation, and Gluconeogenesis Impairment in the Liver of Mice. *Biology*, 10(2), 82; <https://doi.org/10.3390/biology10020082>
- Kanders, B.S., Lavin, I.P.T., Kowalchuk, M.B., Greenberg, I., and Blackburn, G.L. (1988). An evaluation of the effect of aspartame on weight loss. *Appetite*;11Suppl 1:73-84.
- Makkar, H. P.S. and Becker, K. (1997). Nutrients and Antiquality Factors in Different Morphological Parts of *Moringaoleifera* Tree. *J. Agric Sci., Cambridge* 128: 311 - 322
- Miltan, M. J., Agid, V., Brune, M., and Carter, C. S. (2012). Cognitive Dysfunction in Psychiatric disorders characteristics, causes and the quest for improved therapy. *National Drug Discovery*.141-145.
- Moore, K.L., Arthur, F.D., and Anne, M.R.A. (2014). Clinically Oriented anatomy.
- Morales, F. M., Cervantes, E. M., Espinoza, M., and Martinez, O. H. A. (2015). Nutritional and Biochemical Effect of Aspartame Intake in rat under experimental diet. *Journal of Biology and Agriculture Science* 3(3): 298-306.
- Nettleton J.E., Reimer R.A., Shearer J. (2016). Reshaping the Gut Microbiota: Impact of Low Calorie Sweeteners and the Link to Insulin Resistance? *Physiol. Behav.* ;164:488–493. doi: 10.1016/j.physbeh.2016.04.029.
- Norah, S., Johani, A., and Bazzaz, A. A. (2019). Acute Impact of the Artificial Sweetener Aspartame on the Ultrastructures of Hepatocyte in Mice. DOI: [10.4236/abb.2019.106012](https://doi.org/10.4236/abb.2019.106012)
- Odebiyi, O. O. and Sofowora, E. A. (1978). Phytochemical screening of Nigerian Medicinal Plants Part II, *Lloydia*, 41: 1-25.
- Oduro, I., Ellis, W.O., and Owusu, D. (2008). Nutritional Potential of two leafy Vegetables: *Moringaoleifera* and *Ipomoea batatas* leaves. *Scientific Research and Essay*, Vol. 3 (2): 57 - 60
- Polyák, E., Gombos, K., Hajnal, B., Bonyár-Müller, K., Szabó, Sz., Gubicskó-Kisbenedek, A., Marton, K., and Ember, I. (2010). Effects of artificial sweeteners on body weight, food and drink intake. *Acta Physiologica Hungarica*, Volume 97 (4), pp. 401–407 (2010) DOI: 10.1556/APhysiol.97.2010.4.9
- Portela, G. S., Azoubel, R. and Battagaliay F. (2014). Effect of Aspartame on mental-petal and placental weight. *International Journal of Morphology* 25:549-554.
- Price, M.L. (1985). *TeMoringa Tree*, ECHO Technical Note (revised 2000 by Kristine Davis)

Qing Yang (2010). Neuroscience. Gain weight by “going diet?” Artificial sweeteners and the neurobiology of sugar cravings. *Yale J Biol Med.*; 83(2): 101–108.

Suez J., Korem T., Zeevi D., Zilberman-Schapira G., Thaiss C.A., Maza O., Israeli D., Zmora N., Gilad S., Weinberger A., *et al.* (2014). Artificial Sweeteners Induce Glucose Intolerance by Altering the Gut Microbiota. *Nature.* ;514:181–186. doi: 10.1038/nature13793.

Tandel, K.R. (2011). Sugar substitutes. Health controversy over perceived benefits. *Journal Pharmacol Pharmacology* 2(4): 236-243.

UNDER PEER REVIEW