

Original Research Article

Association Between Vessel Density and Visual Acuity in Patients with Diabetic Retinopathy

Abstract

Background: In the non-proliferative stage, diabetic retinopathy (DR) is a retinal vascular disease. Characterised by the formation of micro aneurysms, retinal haemorrhages, exudates, venous alterations, and capillary non-perfusion. With the usage of optical coherence tomography angiography (OCTA), the purpose of this study was to determine the correlation between vessel density and BCVA in DR patients.

Methods: This prospective observational research was done on 50 eyes of 35 consecutive diabetic patients who were diagnosed with mild, moderate or severe non-proliferative diabetic retinopathy (NPDR) and patients with proliferative diabetic changes (as NVD and NVE) as well as a control group consisting of 20 eyes of 10 healthy age-matched participants.

Participants were divided into two groups: group A (diabetic patients): sub divided group A1: 40 eyes diagnosed with NPDR and A2: 10 eyes diagnosed with proliferative diabetic retinopathy (PDR) and group B (control group): 20 healthy eyes of age matched participants as a control group. All the eyes were subjected to fundus fluorescein angiography (FFA) and OCTA. Comparison was made between the vascular density index (VD) in the different slaps between NPDR and PDR group, as well as correlation between the VD and BCVA.

Results: Significant positive correlation was observed between visual acuity (Log MAR) and vascular density index of superficial layer, deep layer in NPDR group and PDR group. Significant positive correlation was observed between vascular density index of superficial, deep layer and best corrected visual acuity (BCVA) (Log MAR) in NPDR group and PDR group.

Write the whole word before :[1DK]Comment abbreviation

Write the whole word before :[2DK]Comment abbreviation

Conclusions: Using OCTA enhance our awareness of the microvascular alterations found in DR and allow assessment of disease severity.

Keywords: Vessel Density, BCVA, Diabetic Retinopathy

The whole manuscript needs :[3DK]Comment editing and proofreading by native English person. Also, abstract is vague.

UNDER PEER REVIEW

Introduction:

There is over 415 million persons suffer from diabetes worldwide, and it is predicted that this number will reach around 642 million by 2040. Worldwide, due to diabetes mellitus, blindness is increasing rapidly. ^[1]

In the non-proliferative stage, diabetic retinopathy (DR) is retinal vascular disease characterised by the formation of micro aneurysms, retinal haemorrhages, exudates, venous alterations and capillary non-perfusion. Neovascularization development is the distinguishing characteristic of progression to the proliferative phase.

Disease severity grading is based on the early treatment DR study (ETDRS) extension of the modified Airlie House classification. ^[2]

Five-stage classification system of the International Clinical DR Disease Severity Scale was used: No apparent DR (NDR), mild non proliferative DR (NPDR), moderate NPDR, severe NPDR, and proliferative DR (PDR). ^[3]

The progression of proliferative disease or macula involvement lead to vision-threatening complications., such as in diabetic macular edema (DME) and diabetic macular ischemia (DMI). ^[4]

The standard method for the staging of DR has long been fluorescein angiography (FA). However, it is invasive, time-consuming, and requires the inoculation of a dye, however, serious consequences are uncommon. The optical coherence tomography angiography (OCTA) new evolution of has enabled noninvasive 3D imaging of the retina's vasculature. ^[5]

OCTA is based on a movement of contrast method that presumes that the only moving component in a static eye is vascular flow.

Visualization of both the superficial and deep retinal capillary plexuses, vessel density calculation and areas of capillary nonperfusion in each plexus is allowed by OCTA. ^[5-9]

Deep capillary plexus (DCP) damage significance, undetectable by FA, was recently observed by OCTA in diabetic individuals, having no or early-stage DR ^[10] or DME. ^[11-13]

This study aimed to assess the relation between vessel density using OCTA and visual acuity in participants with DR.

Patients and Methods:

This prospective observational research was done on 50 eyes of 35 consecutive diabetic participants who had mild, moderate or severe NPDR diagnosis by examination of fundus based on the International Clinical DR Classification. ^[14] and patients suffering from proliferative diabetic changes (as NVD and NVE) diagnosed by clinical examination and fundus fluorescein angiography (FFA) and 20 eyes of 10 healthy age- matched participants.

From the patient or the patient's family, a written informed consent was obtained. The research was done after approval from the Ethical Committee Tanta University Hospitals.

Exclusion criteria were patients with motion artifacts which prevents the precise analysis of the micro vascularization were excluded, patients with severe complications of DR as vitreous hemorrhage or tractional detachment, patients who received laser photocoagulation as a kind of treatment for DR, patients with any media opacity affecting the quality of imaging studies as corneal opacity, dense cataract and participants with other diseases in retina (e.g., vascular occlusion, dystrophy, or degeneration in macula related to aging).

Patients were divided into two groups: group A (diabetic patients): sub divided group A1: 40 eyes diagnosed with NPDR and A2: 10 eyes diagnosed with proliferative diabetic retinopathy (PDR) and group B (control group): 20 healthy eyes of age matched subjects as a control group.

Initial patient evaluations: included personal data, duration and treatment regimen, as well as the control, of DM, history of systemic diseases other than DM as Hypertension, uncorrected visual acuity, best-corrected-visual acuity (BCVA): On a Snellen chart, visual acuity was

assessed and converted into the Log MAR, anterior segment was examined with the use of slit lamp, examination of dilated fundus of the central and peripheral retina using slit lamp bio microscopy with Volk+78 D lens and binocular indirect ophthalmoscopy using Volk +20 D lens and examination of the fundus was used to categorize the diabetic retinopathy according to the International Clinical Diabetic Retinopathy. ^[15]

All the eyes were subjected to: OCTA and FFA.

Fundus fluorescein angiography :

This was performed using Heidelberg FA device (Spectralis, Heidelberg, Germany), confirm diagnosis and classify severity of the NPDR/PDR. With the aid of mydriatic eye drops (MYDRIACYL, ALCON, EGYPT) before examination, all research subjects' eyes were dilated. FFA was captured for diabetic subject using Heidelberg FA device (Spectralis, Heidelberg, Germany). FFA was done using an intravenous injection of 3 ml Sodium fluorescein dye 10%.

Optical coherence tomography angiography:

A colour scale at the bottom of the scan indicated the scan's quality; to be considered an acceptable quality scan, it had to be in the green range. All research participants were dilated with Cyclophorine 1% eye drops before examination. All participants were imaged with the usage of a swept source OCTA device. The images obtained from the OCTA machine in different slaps was be analyzed using the Image J software, with binarization and skeletonization of the scans. Vessel density was calculated as the area covered by the vessels' percentage and the capillaries in an area defined by a 3x3 mm² centered on the fovea. ^[16]

Definition of vascular density was the sample area occupied by vessel lumens percentage after images' binary reconstruction. We measured vessel density at different levels: Superficial vascular plexus and DCP. Correlations were found between OCTA findings and

visual acuity, and the results were compared to those obtained from healthy age-matched controls.

Statistical analysis

SPSS v25 performed the statistical analysis (IBM Inc., Chicago, IL, USA). The parametric quantitative data were given as mean and standard deviation (SD) and analysed using the ANOVA (F) test with post hoc comparisons (Tukey). Non-parametric quantitative data were provided as median and interquartile range (IQR) and analysed using the Mann Whitney test. When applicable, qualitative variables were given as frequency and percentage (percent) and analysed using the Chi-square test or Fisher's exact test. Coefficient of Linear Correlation (r) was utilised to determine correlation between two quantitative variables within one group. A two-tailed P value less than or equal to 0.05 was deemed statistically significant.

Results:

No statistically considerable change in age, sex and duration of D.M among the studied groups was found. Table 1

Table 1: Age, sex and duration of D.M among the studied groups

		Type of D.M			P-value
		NPDR	PDR	Control	
Age (years)		53.725 ± 8.092	53.600 ± 11.394	48.900 ± 9.147	0.133
Sex	Male	8 (27.50 %)	3 (43.00 %)	3 (30.00 %)	0.386
	Female	20 (72.50 %)	4 (57.00 %)	7 (70.00%)	
Duration of D.M (years)		10.383 ± 5.360	12.100 ± 4.954	---	0.363

Data are presented as mean ± SD or frequency (%). D.M: diabetes mellitus, NPDR: non-proliferative diabetic retinopathy, PDR: proliferative diabetic retinopathy

The visual acuity was decreased considerably in both NPDR group and PDR group than control group (P <0.001) and no considerable difference between NPDR group and PDR group (P = 0.003*) was found. There was a considerable change among the studied groups (P <0.001). The BVCA was significantly decreased in both NPDR group and PDR group than

control group ($P < 0.001$) and no considerable difference between NPDR group and PDR group ($P = 0.160$) was found. Table 2

Table 2: Visual acuity and BCVA among the studied groups

	Type of D.M			ANOVA
	NPDR	PDR	Control	
Visual acuity (Log MAR)	0.453 ± 0.245	0.716 ± 0.268	0.198 ± 0.087	<0.001*
TUKEY'S Test	0.003*	<0.001*	<0.001*	
BCVA (Log MAR)	0.442 ± 0.243	0.586 ± 0.308	0.138 ± 0.060	<0.001*
TUKEY'S Test	0.160	<0.001*	<0.001*	

Data are presented as mean ± SD or frequency (%), D.M: diabetes mellitus, NPDR: non-proliferative diabetic retinopathy, PDR: proliferative diabetic retinopathy, BCVA: Best Corrected Visual Acuity, β Results in Log MAR

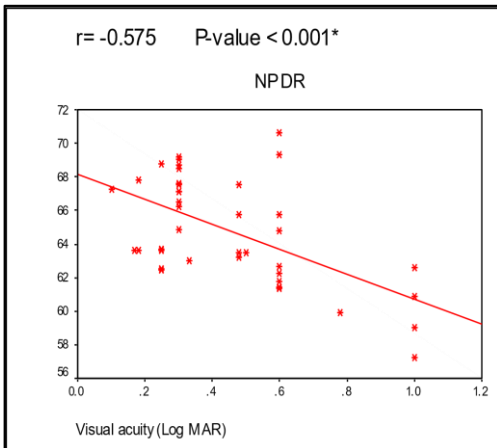
A considerable change among the three groups ($P < 0.001$) in the superficial layer vascular density index of the patients was found. The superficial layer vascular density index was considerably decreased in PDR group than both NPDR and control group ($P < 0.001$) and was considerably decreased in NPDR group than control group ($P < 0.001$). There was a considerable change among the studied groups ($P = 0.001$) in the index of deep layer. The index of deep layer was considerably decreased in PDR group than both NPDR group ($p < 0.001$) and control group ($p < 0.001$) and there was a considerable change between PDR and control group ($p < 0.001$). Table 3

Table 3: Vascular density index of superficial layer and index of deep layer among the studied groups

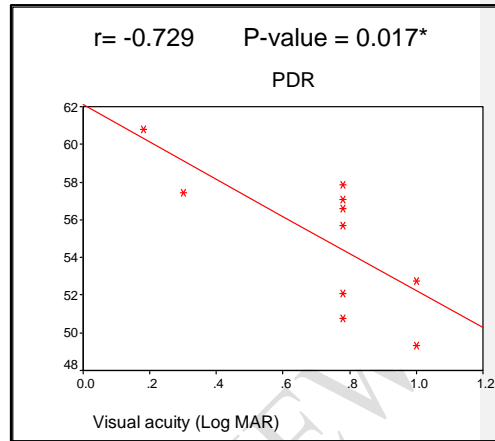
	Type of D.M			ANOVA
	NPDR	PDR	Control	
Vascular density index of superficial layer	64.794 ± 3.187	55.046 ± 3.633	70.084 ± 2.998	<0.001*
TUKEY'S Test	<0.001*	<0.001*	<0.001*	
Index of deep layer	64.228 ± 4.262	53.879 ± 3.555	73.437 ± 6.425	<0.001*
TUKEY'S Test	<0.001*	<0.001*	<0.001*	

Data are presented as mean ± SD or frequency (%), D.M: diabetes mellitus, NPDR: non-proliferative diabetic retinopathy, PDR: proliferative diabetic retinopathy

A considerable positive correlation between the superficial, deep layer vascular density index and visual acuity (Log MAR) in NPDR group and PDR group was found. Figure 1 – Figure 2

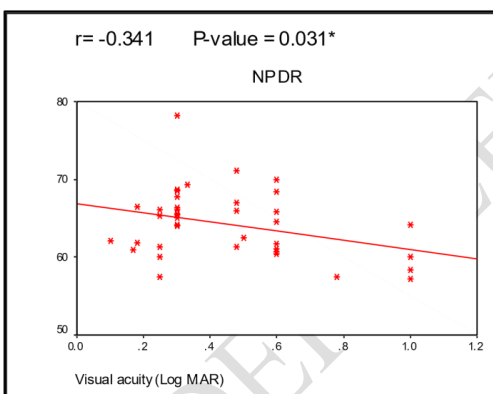


(A)

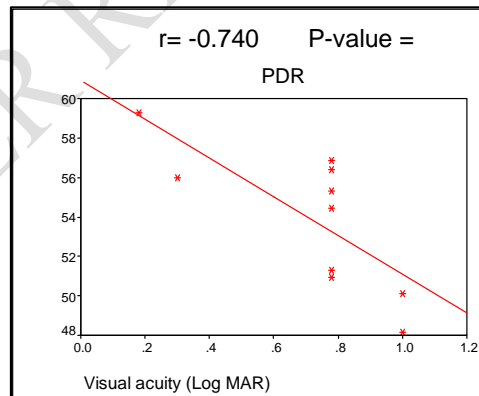


(B)

Figure 1: Correlation between the vascular density index of superficial layer and visual acuity in (A) NPDR group and (B) PDR group



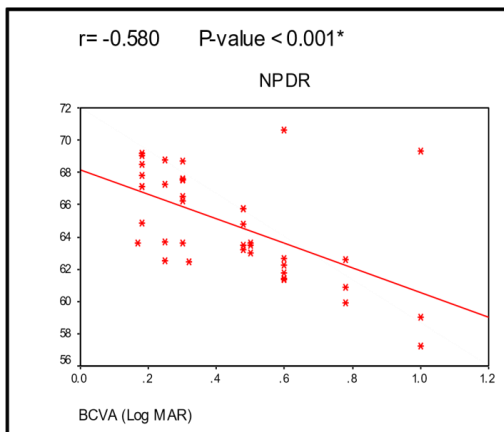
(A)



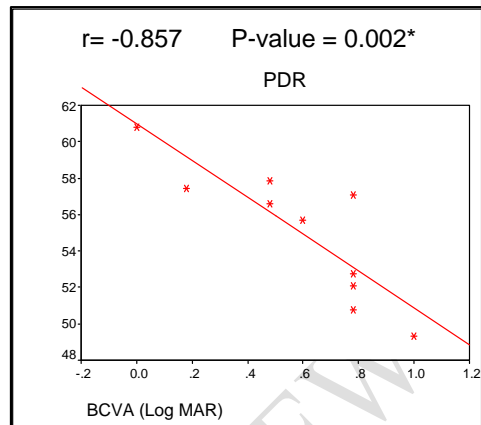
(B)

Figure 2: Correlation between the vascular density index of deep layer and visual acuity in (A) NPDR group and (B) PDR group

A significant positive correlation between vascular density index of superficial, deep layer and BCVA (Log MAR) in NPDR group and PDR group was found. Figure 3 – Figure 4

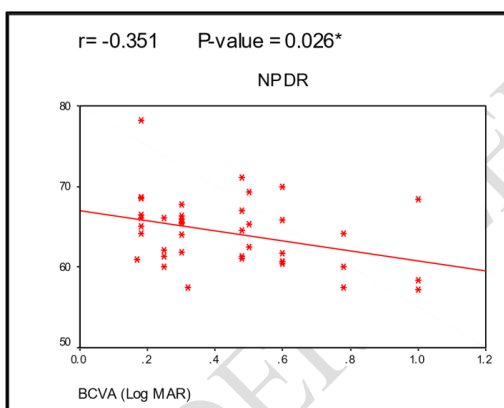


(A)

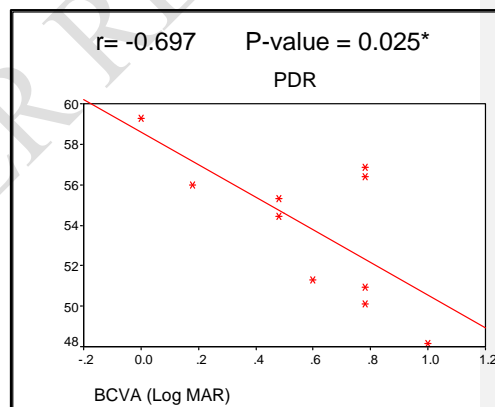


(B)

Figure 3: Correlation between the vascular density of superficial layer and BCVA (Log MAR) in (A) NPDR group and (B) PDR group



(A)



(B)

Figure 4: Correlation between the index of deep layer and BCVA (Log MAR) in (A) NPDR group and (B) PDR group

Discussion

In comparison to FA, OCTA is an unique non-invasive imaging method allowing 3-dimensional imaging of retinal and optic nerve capillary networks without the inoculation of extrinsic dyes.^[17]

Visual acuity was statically significant lower in PDR group than NPDR and control groups and it was statically significant poor in NPDR group than control group.

Also, among the three groups, BCVA was statically significant different. The BCVA was statically considerably decreased in both NPDR group and PDR group than control group.

This agreed with a study by Ghassemi et al. ^[18] who recruited 188 eyes of 97 patients in a cross-sectional research and performed OCTA scan for macula on them to quantitatively measure vascular density with the use of OCTA in DR subtypes including those with NDR, NPDR and to make a comparison of these observations to one another and to the normal population. They found that BCVA was considerably reduced in the participants having PDR and NPDR compared to non-DR and normal participants.

The vascular density index of superficial, deep layer of the patients were significantly different among the studied groups. The superficial layer vascular density index was considerably decreased in PDR than NPDR and control group and was considerably decreased in NPDR than control group. The index of deep layer was considerably decreased in PDR group than both NPDR group and control group and was significant different between PDR and control group.

This agreed with a study by Dupas et al. ^[19] who made a retrospective cohort study of visual acuity and OCTA which included 22 eyes of 22 participants with type 1 diabetes who doesn't suffer from edema in macula but with progressive bilateral DR which progress rapidly to find the association between density of macular vessel and visual acuity, they found that less vessel density in eyes with DR and lowered visual acuity in comparison with eyes with DR and normal visual acuity.

The ratio of vascularized area in the central macula is represented by vessel density. Dropout of parafoveal capillary or lowered perfusion may result from low vessel density and would have an effect on vision. ^[20]

Usui et al. ^[21] hypothesised that neurovascular regions with capillaries in the DCP are formed from amacrine and horizontal cells and are interdependent to a high degree. They revealed that loss of 1 or both of them provokes major effects on function and survival of photoreceptor, these data imply that a threshold of macular non-perfusion might be discovered, specifically in the DCP, beyond which normal eyesight cannot be preserved. Although in both the SVP and DCP a reduction in vessel density is usually seen, such a reduction in the DCP alone could be adequate to cause blindness. Alternately, any retinal vascular plexus capillary perfusion moderate loss is aligned with normal eyesight, and it is likely that vessel density reduction precedes a VA reduction.

In this study, a significant positive correlation between superficial, deep layer vascular density index and visual acuity (Log MAR) in PDR and NPDR group was found.

The visual acuity and vessel density relationship has also been researched by Samara et al. ^[22] who found a positive correlation between log MAR visual acuity and vessel density both in the superficial layer and the deep layer ($r, -0.5; P < 0.001$).

In this study, a significant positive correlation between vascular density index of superficial layer, deep layer and BCVA (Log MAR) in PDR and NPDR group was found.

This agreed with Abdelshafy et al. ^[23], as a significant decrease in BCVA (Log MAR) with decreased vascular density in superficial layer in PDR and NPDR group was found.

But this in contrast with a study by Hsiao et al. ^[24] who performed OCTA in 81 eyes of 48 patients with DME to explore the macular ischemia impact on vision in DME by analyzing the visual acuity and micro vascular parameters of macula relationship. Microvasculature It has been demonstrated that fractional dimension assessed with OCTA decreases at DR various stages, and the alterations in the DCP is more evident than in the SCP ^[25, 26], possibly due to central macula's capillary dropout. They found that none of the superficial layer characteristics were related with BCVA after alteration of CRT and disruption of ellipsoid

zone at the fovea, only in the DCP, low vessel density was related significantly with decreased BCVA ($p = 0.006$). This contrast between the two studies may be related to that this study concentrated on diabetic patients with DME mainly and demonstrated that DME patients manifest considerable damage to the DCP integrity but not the SCP. ^[27]

Conclusions:

OCTA helps increase our understanding of the microvascular alterations associated with DR and allow assessment of disease severity.

COMPETING INTERESTS DISCLAIMER:

Authors have declared that they have no known competing financial interests OR non-financial interests OR personal relationships that could have appeared to influence the work reported in this paper.

References:

1. Das A. Diabetic retinopathy: Battling the global epidemic. *Invest Ophthalmol Vis Sci.* 2016;57:6669-82.
2. Abramoff MD, Fort PE, Han IC, Jayasundera KT, Sohn EH, Gardner TW. Approach for a Clinically Useful Comprehensive Classification of Vascular and Neural Aspects of Diabetic Retinal Disease. *Invest Ophthalmol Vis Sci.* 2018;59:519-27.
3. Sorour O, Arya M, Waheed N. New findings and challenges in OCT angiography for diabetic retinopathy. *Ann Eye Sci.* 2018;3:44.
4. Adhi M, Brewer E, Waheed NK, Duker JS. Analysis of morphological features and vascular layers of choroid in diabetic retinopathy using spectral-domain optical coherence tomography. *JAMA Ophthalmol.* 2013;131:1267-74.
5. Or C, Sabrosa AS, Sorour O, Arya M, Waheed N. Use of OCTA, FA, and ultra-widefield imaging in quantifying retinal ischemia: A review. *Asia Pac J Ophthalmol (Phila).* 2018;7:46-51.

6. de Carlo TE, Romano A, Waheed NK, Duker JS. A review of optical coherence tomography angiography (OCTA). *Int J Retina Vitreous*. 2015;1:5.
7. Couturier A, Mané V, Bonnin S, Erginay A, Massin P, Gaudric A, et al. Capillary plexus anomalies in diabetic retinopathy on optical coherence tomography angiography. *Retina*. 2015;35:2384-91.
8. Ishibazawa A, Nagaoka T, Takahashi A, Omae T, Tani T, Sogawa K, et al. Optical coherence tomography angiography in diabetic retinopathy: A prospective pilot study. *Am J Ophthalmol*. 2015;160:35-44.
9. Matsunaga DR, Yi JJ, De Koo LO, Ameri H, Puliafito CA, Kashani AH. Optical coherence tomography angiography of diabetic retinopathy in human subjects. *Ophthalmic Surg Lasers Imaging Retina*. 2015;46:796-805.
10. Miwa Y, Murakami T, Suzuma K, Uji A, Yoshitake S, Fujimoto M, et al. Relationship between functional and structural changes in diabetic vessels in optical coherence tomography angiography. *Sci Rep*. 2016;6:29064.
11. Schaal KB, Munk MR, Wyssmueller I, Berger LE, Zinkernagel MS, Wolf S. Vascular abnormalities in diabetic retinopathy assessed with swept-source optical coherence tomography angiography widefield imaging. *Retina*. 2019;39:79-87.
12. Manjaramkar A, Kokare M. Statistical geometrical features for microaneurysm detection. *J Digit Imaging*. 2018;31:224-34.
13. Kar SS, Maity SP. Automatic detection of retinal lesions for screening of diabetic retinopathy. *IEEE Trans Biomed Eng*. 2018;65:608-18.
14. Browning DJ, Altaweel MM, Bressler NM, Bressler SB, Scott IU, Network DRCR. Diabetic macular edema: what is focal and what is diffuse? *Am J Ophthalmol*. 2008;146:649-55.

15. Wilkinson CP, Ferris FL, 3rd, Klein RE, Lee PP, Agardh CD, Davis M, et al. Proposed international clinical diabetic retinopathy and diabetic macular edema disease severity scales. *Ophthalmology*. 2003;110:1677-82.
16. Ghasemi Falavarjani K, Al-Sheikh M, Akil H, Satta SR. Image artefacts in swept-source optical coherence tomography angiography. *Br J Ophthalmol*. 2017;101:564-8.
17. Kim DY, Fingler J, Zawadzki RJ, Park SS, Morse LS, Schwartz DM, et al. Optical imaging of the chorioretinal vasculature in the living human eye. *Proc Natl Acad Sci U S A*. 2013;110:14354-9.
18. Ghassemi F, Fadakar K, Berijani S, Babeli A, Gholizadeh A, Sabour S. Quantitative assessment of vascular density in diabetic retinopathy subtypes with optical coherence tomography angiography. *BMC Ophthalmol*. 2021;21:82.
19. Dupas B, Minvielle W, Bonnin S, Couturier A, Erginay A, Massin P, et al. Association between vessel density and visual acuity in patients with diabetic retinopathy and poorly controlled type 1 diabetes. *JAMA Ophthalmol*. 2018;136:721-8.
20. Țălu Ș, Călugăru DM, Lupașcu CA. Characterisation of human non-proliferative diabetic retinopathy using the fractal analysis. *Int J Ophthalmol*. 2015;8:770-6.
21. Usui Y, Westenskow PD, Kurihara T, Aguilar E, Sakimoto S, Paris LP, et al. Neurovascular crosstalk between interneurons and capillaries is required for vision. *J Clin Invest*. 2015;125:2335-46.
22. Samara WA, Shahlaee A, Adam MK, Khan MA, Chiang A, Maguire JI, et al. Quantification of diabetic macular ischemia using optical coherence tomography angiography and its relationship with visual acuity. *Ophthalmology*. 2017;124:235-44.
23. Abdelshafy M, Abdelshafy A. Correlations between optical coherence tomography angiography parameters and the visual acuity in patients with diabetic retinopathy. *Clin Ophthalmol*. 2020;14:1107-15.

24. Hsiao CC, Yang CM, Yang CH, Ho TC, Lai TT, Hsieh YT. Correlations between visual acuity and macular microvasculature quantified with optical coherence tomography angiography in diabetic macular oedema. *Eye (Lond)*. 2020;34:544-52.
25. Bhardwaj S, Tsui E, Zahid S, Young E, Mehta N, Agemy S, et al. Value of fractal analysis of optical coherence tomography angiography in various stages of diabetic retinopathy. *Retina*. 2018;38:1816-23.
26. Chen Q, Ma Q, Wu C, Tan F, Chen F, Wu Q, et al. Macular vascular fractal dimension in the deep capillary layer as an early indicator of microvascular loss for retinopathy in type 2 diabetic patients. *Invest Ophthalmol Vis Sci*. 2017;58:3785-94.
27. Lee J, Moon BG, Cho AR, Yoon YH. Optical coherence tomography angiography of DME and its association with anti-VEGF treatment response. *Ophthalmology*. 2016;123:2368-75.