

Original Research Article

Verification of Fascial Fissure Direction at the Port-site: the Search for a Reliable Closure

Method

ABSTRACT

Background

One of the complications of endoscopic surgery is port-site hernia. The risk of port-site hernia is minimized by proper port-site closure, which relies on appropriate characterization of the fascia, particularly the direction of fascial fissures.

Methods

The following 4 procedures were examined to identify the fascial fissure direction: mobility of the port, observation from the lumen of the port, palpation for fascia, and visual confirmation. The match rate of each procedure with visual confirmation was verified. Modified Z-sutures were performed using a new fascial closure system.

Results

51 port-sites without fasciotomy were examined. The direction of the fissure was from 12 to 6 o'clock in 11 cases and 3 to 9 o'clock in 40 cases. The match rate between mobility and the fissure was 45.1%. The match rate of observation from the lumen was 96.1%. The VersaOne™ fascial

closure system was used in 33 cases. Comparing the suturing time, the average time was significantly shortened to 327 seconds in the second half compared to 494 seconds in the first half of our study period.

Conclusion

Treatment of port-site hernia can be done by suture or mesh repair, although ideally it is best to prevent the hernia in the first place. Examination of the port-site revealed vertical or horizontal fissure directions in most cases. In addition, fissure direction was almost always identifiable via observation from the lumen of the port. Closure of the port-site using modified Z-sutures allowed for full fascial closure, particularly in cases of patients with obesity.

Keywords: Port site hernia, Port site closure, obesity, fascial fissure

INTRODUCTION

Although the incidence of port-site hernia (PSH) is rare, at about 1%, it can be associated with serious complications such as necrosis of incarcerated intestine [1,2]. Prevention of PSH requires reliable suture closure of the abdominal wall penetrated by the port. The European Hernia Society guidelines [3] recommend a suture pitch of 4-5 mm for abdominal wall closure, and note that one-needle suture closure may be inadequate for fascial fissure with ports larger than 10mm in

diameter. We use 2 threads or Z-suture to close port-sites with a diameter of 10mm or more. Additionally, in complex cases such as in patients with severe obesity, additional time and effort is required to appropriately identify the fascia and ensure suture closure. It is important to identify the fascia, confirm the direction of the fissures, and move the needle perpendicular to the long axis of the fissure. Usually, the direction of the fissure is identified by direct finger palpation or direct visual confirmation. However, it is not easy to identify the fascia and the direction of the fissure in obese cases. In addition, the recently available fascia closure system is a conventional system that assists in suturing the abdominal wall by simply inserting a guide without removing the port from the abdominal cavity. However, if the true direction of the fissure is unknown, then the system's effectiveness at appropriate closure may be questioned.

In this study, we focus on the shape of the port-site, specifically fascial fissure direction, as this is often difficult to evaluate, but crucial for hernia prevention.

METHODS

Observation of the fascial fissure at the port-site

A total of 61 cases using 12mm ports from September 2020 to December 2020 were evaluated.

Four procedures were examined to identify the direction of the facial fissure at the port-site:

- Mobility of the port (to estimate that the fissure would be in the most mobile direction)

- Observation from the lumen of the port (to evaluate the direction connecting the two places where the fascia is thin)

- Direct finger palpation of the fascia

- Visual confirmation

After examining the 4 procedures, the matching rate of each procedure with visual confirmation was verified. We also examined whether age, gender, body mass index (BMI), abdominal wall thickness (measured by computed tomography; CT), site of port, and/or type of surgery influenced the determination of fissure direction match rate. Fissure direction of the fascia was described via clock time, with the head and caudal side of the body at 0-6 o'clock, the left side at 3 o'clock, and the right side at 9 o'clock.

Statistical analysis

Values are presented as mean \pm SD. Comparisons of the continuous variables were using t-test. Fisher's exact test was used to compare categorical variables. P-value <0.05 was considered to indicate statistical significance.

Modified Z-suture using VersaOneTM fascial closure system

Using the VersaOneTM fascial closure system (VFCS) (Medtronic Japan), the port-site was closed with modified Z-sutures by rotating the port[4]. The VFCS is designed so that when the thread is inserted from the channel, it comes out about 15 degrees away from the opposite side. Therefore, in

order to pass the thread from 1:30 to 7:30, it is necessary to pass the thread from 2 o'clock and pull it out from 8 o'clock (Fig.1 a,b), so that the suture is now oriented vertically across the port site. The port is then rotated 90 degrees counterclockwise and the passer grip is used to grasp the suture that is now exiting from the 11 o'clock position (Fig.1 c). Afterwards, the suture is returned to the abdominal cavity and grasped with a passer inserted from 5 o'clock (Fig.1 d,e). The modified Z-suture is completed by removing the port and tying off the suture (Fig. 1 g, h).

RESULTS

In all cases where the port was inserted after fasciotomy, the direction of the fasciotomy and fissure were the same. For that reason, of the 79 port-sites in our original 61 cases, 28 port-sites in 21 cases with fasciotomy were excluded from examination. The 40 remaining cases include cholecystectomy in 8 cases, appendectomy in 10 cases, hernia repair in 9 cases, colectomy in 10 cases, and gastrectomy in 3 cases. There were 51 port-sites in 40 cases. There were 29 males and 11 females with an average age of 61.9 years. Average BMI was 22.4kg/m² with 2 cases exceeding 30kg/m². Regarding the direction of fissure, one case was estimated to be 2:30-8:30 o'clock and one was estimated to be 2:30-6:30 o'clock. In this study, they were classified as 3-6 o'clock and 12-6 o'clock respectively (Table 1).

The direction of the fissure was 12-6 o'clock in 10 cases (19.6%) and 3-9 o'clock in 41 cases

(80.4%), with the percentage of cases in the 3-9 o'clock group being significantly higher. No association was found between fissure direction and site of port, port for scope or not, and midline or not. Interestingly, at the scopic port, the rate of fissure in the 12-6 o'clock direction was high at 34.8% (8/23).

The matching rate between port mobility and fissure direction was 25/51 (45.1%). The matching rate between observation from the lumen and fissure direction was 49/51 (96.1%). The matching rate by direct finger palpation was 100%.

The port site was median in 26 cases and non-midline in 25 cases. The rates of fissure in the 12-6 o'clock direction at each site were similar at 5/25 (20%) in the midline and 6/26 (23.1%) in the non-midline. The ratio of 12-6 o'clock judged from port mobility was 20/25 (80%) in the middle compared to 11/26 (42.3%) in the non-median position. In the midline, the rate of misdiagnosis was significantly higher at 12-6 o'clock ($p < 0.01$).

VFCS was used in 28 cases (33 port-site), with 11 males and 17 females. The average BMI was 26.9kg/m² and 7 cases exceeded 30kg/m². The average thickness of the abdominal wall was 39.2 mm. The average time required for suturing the port-site was 413 seconds. There was no correlation between suture time and abdominal wall thickness and BMI. When the cases were divided into the first half and the second half, the average suturing time was significantly shortened to 327 seconds in the second half compared to 494 seconds in the first half (Table 2).

With this method, as shown in figure 1, it can be confirmed that the peritoneum is tightly sutured as compared with the fascia-only suture as usual. No post-site hernias have been reported to date.

DISCUSSION

Laparoscopic surgery has become highly utilized for abdominal surgeries, particularly due to the advantage of preserving the abdominal wall. Preservation of the abdominal wall contributes not only to cosmetic benefit, but also to reduction of postoperative pain and intra-abdominal adhesions.

However, a rare complication of laparoscopic surgery is post-site hernia (PSH), and is reported in about 1% of cases. Although PSH is typically uncomplicated, it can be associated with intestinal incarceration necessitating resection. Additionally, the true incidence of PSH is likely underestimated as most patients only present when symptomatic [5,6].

There are patient-related factors and surgery-related factors associated with the development of PSH [7-11]. Patient-related risk factors include BMI>28kg/m², age>60 years, post-operative port site infection, uncontrolled diabetes mellitus, previous abdominal surgery, and positive smoking status. Surgery-related risk factors include prolonged surgical duration, excessive manipulation of the port site, the size of the port-site incision, the site of port placement (umbilical sites are more prone to hernias), non-closure of the fascia at the port-site, and the type of port tip. Ultimately, PSH correction requires surgical management, therefore primary prevention of PSH is desired via proper

port-site closure, particularly in high-risk patients.

During laparoscopic surgery, the skin is typically incised based on port diameter. However, in cases of patients with BMI greater than 30kg/m² or when the abdominal wall is thicker than 30mm, identification, grasping, suturing, and threading of the fascia is difficult [12]. Given these challenges, there have been several techniques proposed for suturing the port-site wound: Lasheen needle [13], Deschamps needle [14], VersaStep™ trocar system, use of two S-retractors, use of a skin hook and Langenbach retractor, non-bladed, radially dilating and conical blunt devices, Carter-Thomason devices [14], tangential insertion of ports, endoscopic placement of fascial suture under direct vision, and insertion of a surgical plug into the muscular layer. In recent years, a system has been developed that can easily suture port-sites during laparoscopic surgery [4]. In cases using a 12mm port, the port-site can be sutured simply by inserting a guide into the port without removing the port. However, it is not easy to safely and securely suture and close the port-site in obese cases using either technique.

From our past experience, we recognize two issues with port-site closure. The first issue pertains to direction of closure and the second pertains to port-site length. Identification of the direction of fissure is crucial to determine the appropriate direction the thread should be hung at the port-site. Threading perpendicular to the longitudinal direction of the fissure is important for reliable closure of the port-site incision. In the open method, the direction of the fascial fissure coincides with the

fascial incision. However, other than the open method, it may be difficult to identify the direction of fissure especially in obese cases [16]. In addition, using the VFCS, it cannot be confirmed by finger or direct vision of the port-site. In obese cases, the fascial incision itself is not easy; the optical method is often used and its safety has been previously verified. However, the direction of the fascial fissure is unpredictable in cases using the optical method. In addition, there are no reports that verified the direction of the fissure at the port-site using this method.

There was a slight deviation in 2 cases, but 49 of the 51 port-sites (96%) had vertical (0-6 o'clock) or horizontal (3-9 o'clock) fissure direction. The concordance rate with fascia fissure was 45.1% in port mobility and 96.1% in observation from the lumen. The concordance rate of observation from the lumen was found to be sufficiently predictable. Observation from the lumen of the port confirms the condition of the fascia in contact with the port. As shown in figure 2a, the fascia observed from the lumen is considered to be uniform if the fascia fissure is a perfect circle. However, in many cases, the fascia forms a linear fissure (Fig. 2c). Therefore, there may be a gap between the fascia and the port at both ends compared to near center of the fissure (Fig. 2d). Also, the adhesion at both ends of the fissure is scarce, and the fascia appears to be slightly defective when observed from the lumen. It was clarified that the direction connecting these two points coincided with the direction of the fascial fissure (Fig. 2.e).

Regarding estimation of fissure direction based on mobility of the port, 20 out of 25 port-sites

(80%) were judged to be 0-6 o'clock in the midline of the abdomen, whereas 11 out of 26 port-sites (42.3%) were judged to be 0- 6 o'clock in the non-midline. The percentage of the 0-6 o'clock fissure direction in direct vision was about 20% in both the midline and non-midline groups. We believe that not only the fascia but also the rectus abdominis and other muscles influence mobility.

We believe that the length of the fascial fissure at the port-site is influenced by the number of suture threads required for closure [17]. We closed the port-site with at least 2 needles or Z-suture in 12 port-site cases. Given that the calculated circumference of the 12mm port-site is about 38mm, the suture length requiring closure is 19mm. Unlike muscle, the fascia is less affected by tension, and long-term surgery may further prolong the fascial fissure. From the results of comparative verification of the wound closure interval by Deerenberg et al. and the suture pitch recommended by the guidelines of the European Hernia Society, it is possible that one stitch is not enough to close the port-site and two stitches or Z-suture are recommended.

Based on the above results, we measured the thickness of the abdominal wall at the planned port insertion site by CT, and closed the port-site with modified Z-suture using VFCS in cases of 31mm or more. Since in most cases the fascial fissure direction was 0-6 or 3-9 o'clock, the first thread was hung in the 1.5-7.5 o'clock direction, as shown in Figure 1b. There is a choice between clockwise and counterclockwise rotation of the port prior to the next step. The fissure direction is estimated by observing from the lumen before rotation. When the fissure direction is 0-6 o'clock, the port is

rotated counterclockwise so that the thread existing on the fascia surface is perpendicular to the fissure. However, even when rotated clockwise, the thread on the fascia is horizontal in the fissure. In each case, the thread crosses in an X-shape in the abdominal cavity and the port-site can be reliably closed (Fig. 3).

This method was applied to 28 cases at 33 port-sites, and the suture time was shortened with the period. One of the favorable features of this method is that the fascia is securely closed and the peritoneum is also reliably threaded (Fig. 4). There have been prior reports of preperitoneal herniation at the port-site even without fascial defect, particularly in patients with obesity, further emphasizing the importance of complete peritoneal closure [18].

CONCLUSION

Although rare, PSH can lead to detrimental complications necessitating intestinal resection, therefore prevention is a key factor in port-site incision. Examination of the shape of the port-site revealed that there were vertical or horizontal fascia fissures in most cases. In cases where it is difficult to close the port-site, it is very useful to take full advantage of VFCS and close the port-site with modified Z-sutures. At first glance, it may seem like a complicated procedure including thread insertion/removal and port rotation, but it is easy to become familiarized with the procedure after a few times. This method is safe and reliable, and we would like to observe the long-term course in

many cases.

CONSENT

The authors declared that informed consent was obtained from the patients of the study for publication of this paper.

ETHICAL APPROVAL

Authors confirmed that all necessary ethical approval from institution were obtained.

FIGURE CAPTIONS

Figure 1. Schematic of the modified Z-suture technique

- a. The suture is inserted from the channel located at 1 o'clock
- b. The passer is inserted through the opposite guide channel, located at 7 o'clock. The suture is grasped and removed from the abdominal cavity
- c. The port is rotated 90 degrees clockwise
- d. The suture that has rotated to the 10 o'clock position is grasped with a passer and returned to the abdominal cavity

- e. The suture in the abdominal cavity is grasped with a passer inserted from the 4 o'clock position
- f. The port is removed
- g. Modified Z-suture is completed
- h. The modified Z-suture, seen from inside the abdominal cavity

Figure 2 Verification of port-site shape

- a. Assuming the shape of the port-site is a circle
- b. No gap between the port and the port-site
- c. Assuming the shape of the port-site is portrait
- d. Gap between the port and the port-site at both ends (arrow)
- e. Operative findings: Difficult to identify the fascia at the point of the arrows

Figure 3 Modified Z-suture

- a. The thread is hanging perpendicular to the fascial fissure
- b. The thread is hanging parallel to the fascial fissure
- c. Both are sutured in a X shape observing from the abdominal cavity

Figure 4 Port-site, seen from inside the abdominal cavity

- a, b: Only the anterior sheath of the fascia is sutured
- c, d: The peritoneum is also securely and tightly closed by modified Z-suture

Table 1

Verification of fascial fissure direction at port-site

Table. 2

Characteristics of 28 patients using VersaOne™ fascial closure system

REFERENCES

1. Uketa S, Shimizu Y, Ogawa K, et al. Port-site incisional hernia from an 8-mm robotic trocar following robot-assisted radical cystectomy: Report of a rare case. *IJU Case Rep* 2020; 21: 97-99.
2. Noorshafiee S, Maddah G, Riyabi FN, et al. Port site port site interpariental hernia after laparoscopic splenectomy: a case report. *J Minim Invasive Surg Sci* 2014; 3: e7748.
3. Muysoms FE, Antoniou SA, Bury K, et al: European Hernia Society guidelines on the closure of abdominal wall incision. *Hernia* 13:343-403, 2009
4. Hagui E, Kimura M, Katada T, et al. Port site hernia repair using VersaOne™ Fascial Closure System: a case report. *J Surg Case Rep* 2020; 26: 1-4.
5. Gogacz M, Kaminska A, Winkler I, et al. Suture or not suture? Trocar-site bowel herniation as a rare complication after trocar placement in laparoscopic surgery: case report and review. *Clin Surg* 2018; 3: 1-3.
6. Nacef K, Chaouch MA, Chaouch A, et al. Trocar site post incisional hernia: about 19 cases

- PanAfr Med J 2018; 29: 183.
7. Pilone V, Micco RD, Hasani A, et al. Trocar site hernia after bariatric surgery: our experience without fascial closure. *Int J Surg* 2014; 12: 83-86.
 8. Zhu J Liu W. Laparoscopic trocar site hernia: a case report and literature review. *Int J Clin Exp Med*. 2016; 9: 1-8.
 9. Bunting DM, Port-site hernia following laparoscopic cholecystectomy. *JLS*. 2010; 14(4): 490-497.
 10. Zhu YP, Liang S, Zhu L, et al. Trocar-site hernia after gynecological laparoscopic surgery: a 20-year, single-center experience. *Chin Med J*. 2019; 20: 2677-2683.
 11. Nofa MN, Yosef A, Hamdan FF, et al. Characteristics of Trocar Site Hernia after Laparoscopic Cholecystectomy. *Sci Rep* 2020; 10: 2868.
 12. Duke JM, Pillay. A case report of a double port site hernia and their laparoscopic repair with intra corporeal suturing of the hernia necks and an underlay mesh repair. *Int J Surg Case Rep*. 2018; 51: 86-89.
 13. Lasheen A, Safwat K, Fiad A, et al. Port-site closure using a modified apotos needle. *JLS* 2013; 17: 312-315.
 14. Pulle MV, Siddhartha R, Dey A, et al. Port site hernia in laparoscopic surgery: mechanism, prevention and management. *Curr Med Res Pract*. 2015; 5: 130-137.

15. Aziz HH. A simple technique of laparoscopic port closure. *JLS*. 2013; 17: 672-674.
16. Tanaka C, Fujiwara M, Kanda M, et al. Optical trocar access for initial trocar placement in laparoscopic gastrointestinal surgery: a propensity score-matching analysis. *ASIAN j Endosc Surg*. 2019; 12: 37-42.
17. Deerenberg EB, Harlaar JJ, Steyerberg EW, et al. Small bites versus large bites for closure of abdominal midline incisions (STITCH): a double-blind, multicentre, randomized controlled trial. *Lancet*. 2015; 386: 1254-1260.
18. Cottam DR, Gorecki PJ, Curvelo M, et al. Preperitoneal herniation into a laparoscopic port site without a fascial defect. *Obes Surg*. 2002; 12: 121-123.

Table 1: Verification of fascial fissure direction at port-site

Age, mean \pm SD, year	61.9 \pm 19.5
Sex (Male/Femal)	29/11
BMI, mean \pm SD, kg/m ²	22.4 \pm 3.9
Abdominal wall thickness, mm	19.6 \pm 8.7
Type of surgery	
Cholecystectomy	8
Appendectomy	10
Hernia repair	9
colectomy	10
Gastreotomy	3
Site of port	

Epigastric	8
Around navel	18
Lateral abdomen	25
Port for scope/Not	23/28
Midline/Non-midline	26/25
Fascial fissure direction	
12-6, n(%)	10(19.6%)
3-9, n(%)	41(80.4%)
Concordance rate with fascial fissure	
Port mobility	23/51(45.1%)
Observation from the lumen	49/51(96.1%)
Palpation with finger	51/51(100%)

Table 2 : Characteristics of 28 patients using VersaOne™ fascial closure system

Age, mean \pm SD, year	55.5 \pm 1.8
Sex (Male/Femal)	11/17
BMI, mean \pm SD, kg/m ²	26.9 \pm 5.3
Abdominal wall thickness, mm	39.2 \pm 8.2
Type of surgery	
Cholecystectomy	12
Appendectomy	9

Hernia repair	4
Port-site hernia	2
Gastrectomy	1
Suture time, sec	413±253
First half	494±217
Second half	327±129

Figure 1. Schematic of the modified Z-suture technique

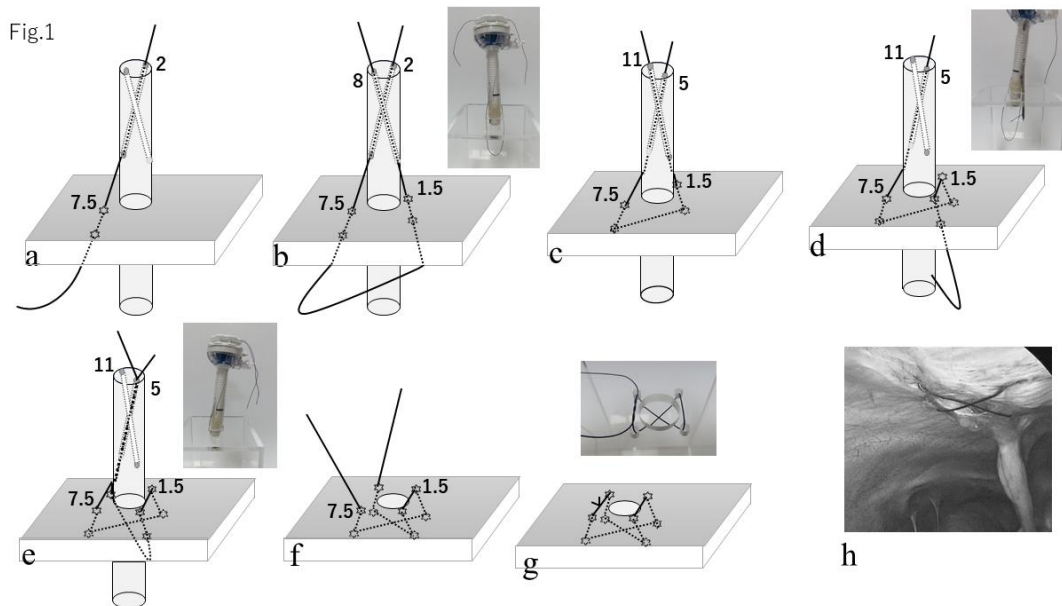


Figure 2: Verification of port-site shape

Fig. 2

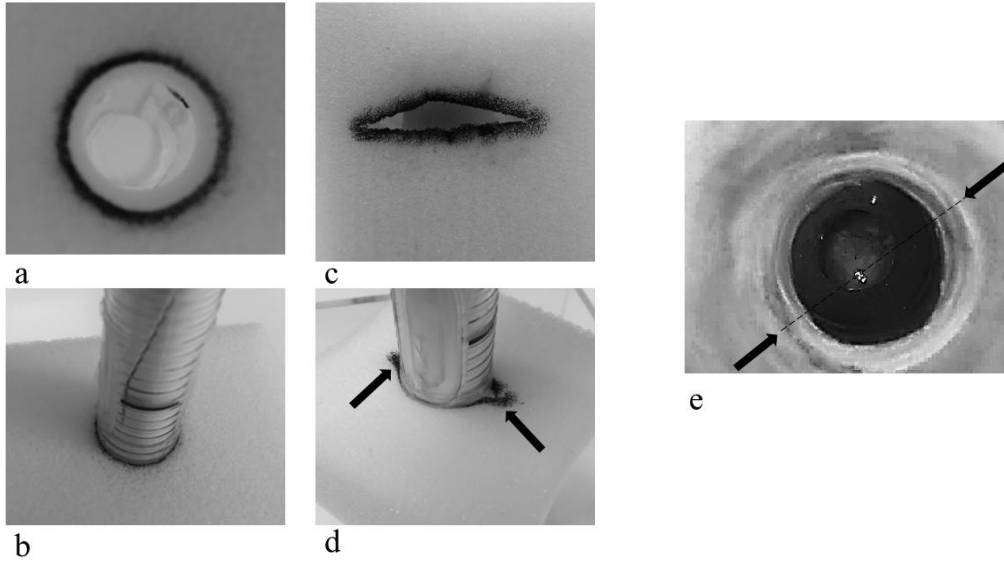


Fig. 3




Figure 3 Modified Z-suture

Fig. 4

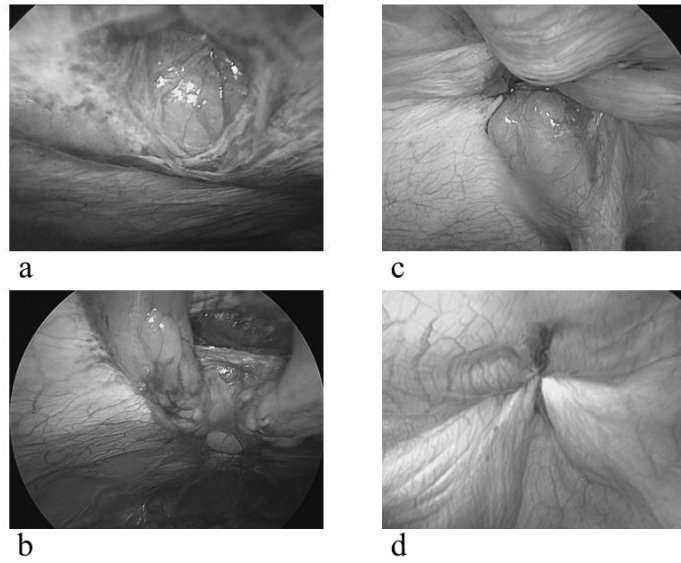


Figure 4 Port-site, seen from inside the abdominal cavity

UNDER PEER RE