

# Original Research Article

## Prevalence of Dermatophytosis in patients attending a Research hospital for Skin Disorders in Hyderabad, South India

Comment [nj1]:

### ABSTRACT

**Aim:** Dermatophytosis is a superficial fungal distributed worldwide, more prevalent in the tropical countries like India. Dermatophytosis is diagnosed based on the history, physical examination, and laboratory diagnosis by Microscopic examination of Potassium Hydroxide (KOH) Mount followed by fungal culture. KOH mount is a rapid, simple, time saving and cost effective diagnostic method. This study was taken up with the objective to determine the prevalence of dermatophytosis with help of Potassium Hydroxide Mount in Hyderabad, South India.

**Materials and Methods:** The study was carried out in Clinical Microbiology section of the Laboratory of the Skin Research Institute in Hyderabad, South India, over a period of 1 year from August 2020 to September 2021. A total of 236 skin scarping samples from clinically suspected cases of dermatophytosis were collected. Patient history and demographic data was collected, direct microscopy by Potassium Hydroxide (KOH) Mount was done.

**Results:** Of all the 236 patients, 186 patients (78.81%) were found to be positive of fungal elements. Males (58.06 %) were more commonly affected than females (41.94 %). Tinea corporis was the most common clinical type (50%) followed by Tinea Cruris(22.58%). The microscopic finding showed Long, refractile, branching, septate hyphae in 92 cases (49.46%); Spaghetti and meatball appearance in 74 cases (39.78%) and pseudohyphae with budding yeast cells forms in only 20 cases (10.75%)

**Conclusions:** The prevalence of Dermatophytosis is high in the study population. In experienced hands, a potassium hydroxide mount is one of the most useful procedures in medical mycology and can be used as screening test and routine investigation in the diagnosis of dermatophytosis so that definite treatment can be commenced without delay.

Comment [nj2]: Redrift the sentence

Comment [nj3]: Not clear

Comment [nj4]: Redrift

**Keywords:** Dermatophytosis, KOH mount, Potassium Hydroxide, Tinea

### 1. INTRODUCTION

Dermatophytosis is an important superficial fungal infection of keratinized tissues of skin infection caused by closely related keratinophilic mycelial fungi (Dermatophytes) belonging to three asexual genera Microsporum, Trichophyton, and Epidermophyton.<sup>1,2</sup> Dermatophytes infections are one of the earliest known fungal infections of mankind and prevalent throughout the world. Although dermatophytosis does not cause mortality, it causes much discomfort and distress to the patient, creating a major public health problem, especially in developing tropical countries like India.<sup>3</sup>

Comment [nj5]: Reference citation style in all text material

The prevalence and frequency of dermatophytosis and their etiology vary according to the geographic region, epidemiological factors like environmental temperature and humidity, the socioeconomic level of the population, personal

hygiene, and the climatic variations. The hot and humid climate in tropical and subtropical countries like India makes dermatophytoses a very common fungal skin infection in India.<sup>3</sup> The severity of the infection depends on strain or species of fungus, the sensitivity of the host and the site of infection.<sup>4</sup>

The dermatophytoses can easily be diagnosed based on the history, physical examination, and laboratory diagnosis. The laboratory diagnosis of dermatophytosis routinely involves Potassium Hydroxide (KOH) Mount and direct microscopic examination of clinical specimen followed by in vitro fungal culture techniques.<sup>5</sup> With the advent of molecular technology, the techniques like polymerase chain reaction which is a highly sensitive and specific test, can be used for confirmation of diagnosis of fungal infections.<sup>5</sup> In fungal culture though is the gold standard specific diagnostic test, but it is a slow technique taking minimum 2-3 weeks and require sophisticated lab and trained personnel hence not feasible for routine investigation in developing country like India. <sup>6, 7</sup>

Microscopic identification of fungal elements by KOH mount is a rapid diagnostic method and can be used as screening test and routine investigation in the diagnosis of dermatophytoses since it is simple, time saving and cost effective when compared with fungal culture.<sup>8</sup> The local data about the disease prevalence is lacking as the treatment is often initiated without any laboratory support or confirmation. This study was taken up with the main objective to determine the prevalence of dermatophytosis with help of Potassium Hydroxide Mount in Hyderabad, South India, and also to study the incidence of dermatophytosis according to age and sex factors.

## 2. MATERIAL AND METHODS

The study was conducted over a period of 1 year from August 2020 to September 2021 and included 236 clinically suspected cases of dermatophytoses attending the Out Patient Services of National Research Institute of Unani Medicine For Skin Disorders, Hyderabad. Patient history and demographic factors such as age, sex and related history of risk factors and history of the present illness were recorded. Samples were collected from site of suspected infection using standard methods.<sup>9, 10</sup>

Prior to sampling, the areas affected were cleaned with a 70% ethanol solution. Then skin samples were collected by scrapping of lesion with sterile blade and transferred to sterile folded papers. Each of these papers was appropriately labeled with the age, sex, date of collection, code of a patient, and location of infection and taken to the Clinical Microbiology section of the Laboratory of the National Research Institute of Unani Medicine for Skin Disorders, Hyderabad within the date of collection. The skin scrapping is then transferred to on a microscope slide labeled with patients identity, followed by applying one or two drop of freshly prepared 10% potassium hydroxide (KOH) solution and coving the slide with the cover slip.

Each treated slide was then carefully examined under low (X10) and high (X40) power objective for the presence of hyphae spores, yeasts, and pseudohyphal forms. The test was considered positive if hyphae and/or spores were detected under the microscope.

## 3. RESULTS AND DISCUSSION

### 3.1 RESULTS

This study included 236 cases of clinically diagnosed superficial dermatophytoses. Direct microscopy with KOH mount was positive in 186 patients (78.81%). (Table.1)

**Table.1:** Direct microscopy with KOH mount finding

KOH mount finding	Number of patients	Percentage
Positive	186	78.81 %
Negative	50	22.03 % 21.18

The patients' age ranged from 10 years to 62 years with average age 29.96 ±10.94. The commonest age group involved was 21-30 years (40.32 %) followed by 31-40 years (23.11 %). Majority of patient (108, 58.06 %) were Males and 78 (41.94 %) were Female. (Table 2)

**Table 2:** Age and Sex distribution of patients

Parameter	Number of patients	Percentage
AGE: 10-20	40	21.50 %
21-30	75	40.32 %
31-40	43	23.11 %
41-50	17	9.13 %
>50	11	5.91 %

**Comment [nj6]:** Check the sentence

**Comment [nj7]:** Causative agents of superficial mycoses not mentioned ?? Give the complet detail.

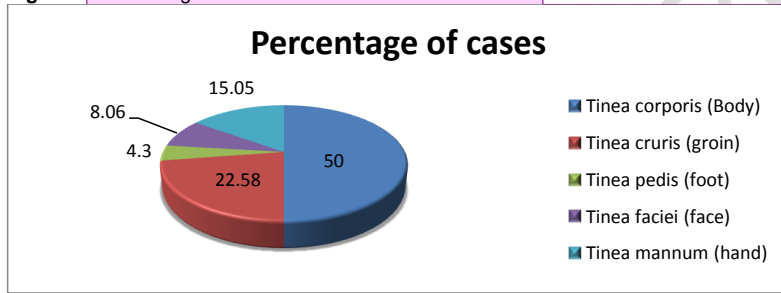
SEX		
Male	108	58.06 %
Female	78	41.94 %

**Distribution of site of Infection:** Frequency and percentage distributions of clinical manifestations in relation to sex. Tinea Corporis, Tinea Mannum and Tinea Pedis is observed more commonly in males compares to females, while Tinea Cruris and Tinea Faciei is common in females then in males **The (Table 3)**. Tinea Corporis is commonly observed in age group 21 -30 years while Tinea Cruris is observed commonly in age group 31-40 years. (Table 4)

**Table 3:** Frequency and percentage distributions of clinical manifestations in relation to sex (n = 186)

Clinical manifestation	SEX		Total (Percentage)
	Male (%)	Female (%)	
<b>Tinea Corporis (Body)</b>	60 (64.51 %)	33 (35.48%)	93 (50%)
<b>Tinea Cruris (groin)</b>	19 (45.23%)	23 (54.76%)	42 (22.58%)
<b>Tinea Pedis (foot)</b>	08 (100%)	0	8 (4.3%)
<b>Tinea Faciei (face)</b>	3 (20%)	12 (80%)	15 (8.06%)
<b>Tinea Mannum (hand)</b>	19 (67.85%)	9 (32.14%)	28 (15.05%)
<b>TOTAL</b>	109 (58.6%)	77 (41.39%)	186 (100%)

**Figure 1:** Percentage distributions of clinical manifestations



**Comment [nj8]:** Please mention the body parts name where these infection commonly seen. Like Tinea manuum is a superficial mycosis of the palm, dorsum, or interdigital folds of one or both hands.

**Table 4:** Frequency of clinical manifestation in different age groups (n = 186).

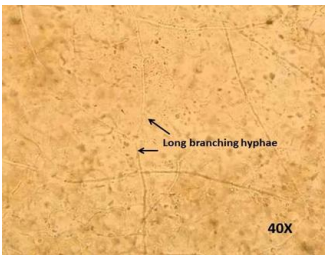
Site	10-20 (%)	21-30 (%)	31-40 (%)	41-50 (%)	>50 (%)	Total
<b>Tinea Corporis (Body)</b>	16 (17.20%)	40 (43.01%)	20 (21.5%)	10 (10.75%)	7 (7.52%)	93
<b>Tinea Cruris (groin)</b>	09 (21.42%)	10 (23.80%)	16 (38.09%)	05 (11.90%)	02 (4.76%)	42
<b>Tinea Pedis (foot)</b>	01 (12.5%)	04 (50%)	01 (12.5%)	02 (25%)	0 (0%)	08
<b>Tinea Faciei (face)</b>	05 (33.3%)	06 (40%)	04 (26.66%)	0 (0%)	0 (0%)	15
<b>Tinea Mannum (hand)</b>	03 (10.71%)	11 (39.28%)	08 (28.57%)	04 (14.28%)	02 (7.14%)	28

**Microscopic Findings of Potassium Hydroxide Mount:** The distributions of clinical manifestations in relation to the direct microscopic potassium hydroxide examination of the scales or erosions from lesions showed Long refractile branching septate hyphae in 48.92% of subjects , Spaghetti and meatball appearance in 39.78% of subjects and pseudohyphae with budding yeast cells forms in only 11.29% of subjects. (Table 5)

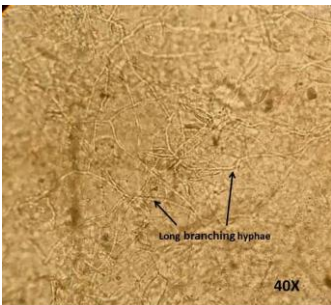
**Table 5:** Microscopic Findings of Potassium Hydroxide Mount (n = 186).

Clinical manifestation	Microscopic Findings		
	Long refractile, branching and	Spaghetti and meatball	Pseudohyphae and

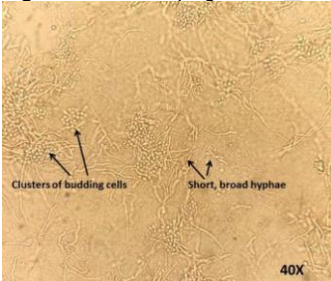
	septate hyphae	appearance	budding yeast cells
<b>Tinea corporis (Body)</b>	56	37	0
<b>Tinea cruris (groin)</b>	16	14	12
<b>Tinea pedis (foot)</b>	1	2	5
<b>Tinea faciei (face)</b>	8	7	0
<b>Tinea manuum (hand)</b>	11	14	3
<b>TOTAL (percentage)</b>	92 (49.46%)	74 (39.78%)	20 (10.75%)



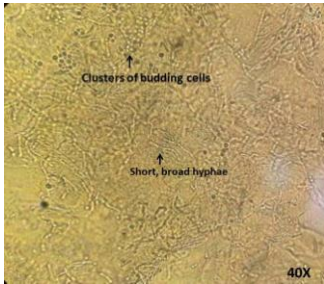
**Figure 2:** Skin scraping and KOH mount showing long branching, refractile, septate fungal hyphae (KOH Mount 40X)



**Figure 3:** Skin scraping and KOH mount showing long branching, refractile, septate fungal hyphae (KOH Mount 40X)



**Figure 4:** Skin scraping and KOH mount showing short, broad hyphae and clusters of budding cells long branching, refractile and septate fungal hyphae having appearance of "spaghetti & meat balls." (KOH Mount 40X)



**Figure 5:** Skin scraping and KOH mount showing short, broad hyphae and clusters of budding cells long branching, refractile and septate fungal hyphae having appearance of "spaghetti & meat balls." (KOH Mount 40X)

### 3.2 Discussion .

Dermatophytosis is an important superficial fungal distributed worldwide, but it is more prevalent in the tropical and subtropical countries like India, where hot and humid climate plays an important role in promoting the growth of these organisms. Dermatophytosis is diagnosed based on the history, physical examination, and laboratory diagnosis by Microscopic examination of Potassium Hydroxide (KOH) Mount followed by fungal culture techniques. The present study attempted to determine the prevalence of Dermatophyte infections in patients attending a Skin Research Institute in Hyderabad, South India over a period of one year with the help of Potassium Hydroxide (KOH) Mount.

In the present study, of all the 236 patients presenting with clinical features of skin infection, 186 patients (78.81%) were found to be positive of fungal elements in Potassium Hydroxide (KOH) Mount. Males (58.06 %) were more commonly affected than females (41.94 %). These observations are comparable with other studies like Vara et al.,<sup>3</sup> Noronha et al.,<sup>1</sup> and Gupta et al.<sup>7</sup> This may be due to the occupation of men and their nature of work leading to excessive sweating and the increase exposure with different people of the society. The lower incidence in females may be also due to the non-reporting of the female patients to the hospitals or due to the prevailing social stigma associated with this condition. The patient data was categorized on the basis of age groups of 10 years to 60 years and above in groups of 10 years gap and it was found that the maximum incidence (40.32%) was observed in the age group of 21 to 30 years. This finding is in accordance with study done by Gupta et al.<sup>7</sup> where 47% patients was observed in the age group of 16 to 30 years and also in study done by Noronha et al.<sup>1</sup> where majority of the patients belonged to the age group of 21–30 years.

In our study, Tinea corporis was the most common clinical type with 93 (50%), followed by Tinea Cruris with 42 cases (22.58%) and tinea manuum with 28 cases (15.05%). This finding is comparable with studies by Noronha et al.,<sup>1</sup> Surendran et al.,<sup>11</sup> Bindu et al.,<sup>12</sup> Singh et al.<sup>13</sup> In this study, Tinea Corporis was more common in the age group of 21–30 years with 40 cases (43.01%). Tinea Cruris was more common in the age group of 31–40 years with 16 cases (38.09%). Tinea Mannum was more common in the age group of 21–30 years with 11 cases (39.28%). Tinea Faciei and Tinea Pedis were also more common in the age groups of 21–30 years.

KOH mount microscopic examination of Dermatophytic infection shows long, refractile, smooth, branching, and septate hyphal filaments with/without spores. Dermatophytes are moulds belonging to the three genera of fungi imperfection- Microsporium, Trichophyton, and Epidermophyton.<sup>11</sup> KOH mount microscopic findings of Pityriasis versicolor caused by *Malassezia furfur* shows numerous short, broad hyphae and clusters of budding cells, which have been described as having the appearance of "spaghetti & meat balls."<sup>14</sup> Infection with Candidiasis demonstrate Pseudohyphae and budding yeast cells in microscopic examination of KOH mount.<sup>15</sup>

In our study, fungal elements were demonstrated by direct microscopy in 186 (78.81%) cases (60%) out of 236 cases. The distributions of clinical manifestations in relation to the direct microscopic potassium hydroxide examination of the scales or erosions from lesions showed Long, refractile, branching, septate hyphae in 92 cases (49.46%); Spaghetti and meatball appearance in 74 cases (39.78%) and pseudohyphae with budding yeast cells forms in only 20 cases (10.75%).

The KOH positivity rate of present study (78.81%) correlates well with findings of other studies like Komal et al.,<sup>16</sup> (73.6%), Begari et al.,<sup>8</sup> (81.82%), Jain et al.<sup>17</sup> (72.5%) and Poluri et al.,<sup>18</sup> (58.18%). The present study demonstrates that rapid diagnosis of superficial fungal infections can be done using KOH mount microscopic examination as this method is a reliable, inexpensive, outpatient procedure which yields quick results so that definite treatment can be commenced without any delay. Fungal culture although a good confirmatory test for identifying fungus, takes a minimum 3 weeks' time to obtain results, hence not very practical.

The KOH wet mount using can be used as a primary screening tool for the detection of fungal elements. The main disadvantages of the KOH wet mount is that it requires expertise for interpretation as KOH wet mount lacks a color contrast and artifacts such as clothing fibers and mosaic fungus may interfere with the results and it can be easily

mistaken for fungal hyphae. KOH wet mount has low sensitivity when hyphae and fungal elements are sparse in the material collected hence a negative test does not rule out fungal infection.

#### 4. CONCLUSION

Dermatophytosis is a common fungal infection in developing countries like India. In the present study, it is found to be more prevalent in male than in females, common in 2<sup>nd</sup> to 3<sup>rd</sup> decade of life and *Tenia corporis* being the most common clinical presentation. The KOH positivity rate is 78.81%. KOH mount can be used as screening test and routine investigation in the diagnosis of dermatophytosis so that definite treatment can be commenced without delay as fungal culture takes a long time to obtain results and not very practical. Nevertheless the KOH wet mount requires expertise for interpretation.

#### CONSENT

"All authors declare that 'written informed consent was obtained from the patient (or other approved parties) for publication of this clinical data and accompanying images."

#### COMPETING INTERESTS DISCLAIMER:

Authors have declared that no competing interests exist. The products used for this research are commonly and predominantly use products in our area of research and country. There is absolutely no conflict of interest between the authors and producers of the products because we do not intend to use these products as an avenue for any litigation but for the advancement of knowledge. Also, the research was not funded by the producing company rather it was funded by personal efforts of the authors.

#### NOTE:

The study highlights the efficacy of " Unani Medicine " which is an ancient tradition, used in some parts of India. This ancient concept should be carefully evaluated in the light of modern medical science and can be utilized partially if found suitable.

#### REFERENCES

1. Noronha TM, Tophakhane RS, Nadiger S. Clinico-microbiological study of dermatophytosis in a tertiary-care hospital in North Karnataka. *Indian Dermatol Online J.* 2016 Jul-Aug;7(4):264-71. doi: 10.4103/2229-5178.185488. PMID: 27559499; PMCID: PMC4976403.
2. Hay RJ, Moore MK. Mycology. In: Burns T, Breathnach S, Cox N, Griffiths C, editors. *Rook's Textbook of Dermatology.* 7th ed. Oxford: Blackwell Science; 2004. p. 31.5- 31.60.
3. Vara, Aarthi & Khan, Rozina & Narayan, L. Prevalence of dermatophytes in patients attending a teaching hospital in Hyderabad, South India. *Indian Journal of Microbiology Research.* 2021. 8. 132-134. DOI: 10.18231/j.ijmr.2021.026
4. Richardson MD, Warnock DW. *Fungal infection: diagnosis and management.* 4th edn. Oxford: WileyBlackwell, 2012: 256–258.
5. Islam, T.A., Majid, F., Ahmed, M., Afrin, S., Jhumky, T., Ferdouse, F. Prevalence of dermatophytic infection and detection of dermatophytes by microscopic and culture methods. *J. Enam Med. Coll.* 2018. 8, 11–15.
6. Maulingkar, Saleel V.; Pinto, M. J. W.; Rodrigues, S.A Clinico-Mycological Study of Dermatophytoses in Goa, India. *Mycopathologia,* 2014. 178(3-4), 297–301. doi:10.1007/s11046-014-9806-9

**Comment [nj9]:** Reference style are not according to journal format

7. Gupta, Sarika ., Purva, Agrawal., Rajawat, Rahul & Saksham, Gupta. Prevalence of dermatophytic infection and determining sensitivity of diagnostic procedures. *International Journal of Pharmacy and Pharmaceutical Sciences*,2014. Vol 6, Issue 3, 35-38
8. Begari V, Pathakumari P, Takalkar AA. Comparative evaluation of KOH mount, fungal culture and PAS staining in onychomycosis. *Int J Res Dermatol* 2019;5:554-58.
9. Weitzman I, Kane J. *Manual of clinical microbiology*. In: Balows A, Hausler Jr WJ, Herrmann KL, Isenberg HD, Shadomy HJ, editors. *Dermatophytes and agents of superficial mycoses.*, 5Washington, D.C.: American Society for Microbiology; 1991. p. 601–6.
10. Kurade SM, Amladi SA, Miskeen AK. Skin scraping and a potassium hydroxide mount. *Indian J Dermatol Venereol Leprol* 2006;72:238-41.
11. Surendran K, Bhat RM, Bolor R, Nandakishore B, Sukumar D. A clinical and mycological study of dermatophytic infections. *Indian J Dermatol* 2014;59:262- 7.
12. Bindu V, Pavithran K. Clinico- mycological study of dermatophytosis in Calicut. *Indian J Dermatol Venereol Leprol* 2002;68:259- 61.
13. Singh S, Beena PM. Profile of dermatophyte infections in Baroda. *Indian J Dermatol Venereol Leprol* 2003;69:281- 3.
14. Kabbin, J.S. & Vijaya, D. & Meundi, M.D. & Budamakuntla, Leelavathy. A clinicomycological study of Pityriasis versicolor with a special reference to the Calcofluor white stain. *Journal of Clinical and Diagnostic Research*. 2012. 5. 1356-1358.
15. Gautam M, Bhatia S. Mount the menace! - Potassium hydroxide in superficial fungal infections. *Indian J Paediatr Dermatol* 2020;21:343-6.
16. Komal D. P, Jaysukh D. Mangukiya, Mahendra M .V. Prevalence of Dermatophytes in skin, hair and nail at tertiary care hospital at Ahmdeabad. *National Journal Of Medical Research*. NJMR | Volume 5 | Issue 4 | Oct – Dec 2015.p 278-281.
17. Jain N, Sharma M, Saxena V N. Clinico-mycological profile of dermatophytosis in Jaipur, Rajasthan. *Indian J Dermatol Venereol Leprol* 2008;74:274-275
18. Poluri LV, Indugula JP, Kondapaneni SL. Clinicomycological study of dermatophytosis in South India. *J Lab Physicians* 2015;7:84-9.