

## **Case report**

**Oral erosive/ulcerative lichen planus in a 3 years old child. A rare case report.**

### **Abstract**

Aim: Oral lichen planus (OLP) is a chronic inflammatory disease of unknown etiology. It mainly affects middle-aged adults, while its occurrence in childhood is rare. The aim of this paper is to present a rare case of erosive/ulcerative OLP in a 3 years old girl, who presented with chronic ulcers on the tongue.

Presentation of Case: A 3 years old girl presented to an Oral Medicine clinic, due to a history of chronic erosive/ulcerative lesions on the tongue causing mild discomfort while feeding. According to the mother, the lesions were first noticed two years ago with periods of remission and exacerbation. The medical history was unremarkable, and no other lesions on the skin or elsewhere were observed. Clinically, diffuse ulcerations and erosions were present on the dorsal surface and the lateral borders of the tongue. A diagnostic biopsy was performed under general anesthesia and histopathological examination with direct immunofluorescence revealed findings compatible with erosive/ulcerative OLP.

Discussion: The occurrence of OLP in childhood is particularly rare with few published cases in the literature. Nonetheless, OLP should be included in the differential diagnosis of chronic ulcerative lesions of the oral mucosa in children.

Conclusion: Accurate diagnosis and discrimination from other, also rare in childhood, vesiculobullous/ulcerative mucocutaneous diseases with oral involvement requires evaluation of the histopathologic and immunophenotypic features and careful clinicopathologic correlation.

Keywords: oral lichen planus, childhood, oral ulcerations/erosions, direct immunofluorescence

### **Introduction**

Oral lichen planus (OLP) is a chronic inflammatory disease associated with a T-cell mediated immune reaction of unknown etiology. It has been suggested that an autoimmune reaction targeting the epithelial basal cells against an unknown antigen, possibly caused by different viruses (e.g. hepatitis C virus, human herpes virus-6, cytomegalovirus), bacteria, contact allergens, drugs (e.g. non-steroid anti-inflammatory and angiotensin-converting enzyme inhibitors), or chemical antigens, could be responsible for the development of the disease [1]. Other predisposing factors, such as trauma or psychological factors, e.g. stress or anxiety, have been demonstrated with controversial results in various studies [1,2].

Lichen planus (LP) usually affects middle aged adults, while its occurrence in childhood is infrequent, accounting for 1-10% of all cases in various studies [3-6]. Genders are almost equally affected, even though some studies have shown a preponderance of boys [6,7]. Most cases of LP in children present with cutaneous lesions, while oral manifestations are less common [6,8-10]; according to a recent systematic review, oral involvement was seen in 22% of childhood LP cases [6], while the prevalence of OLP in children has been estimated to be approximately 0.03%, compared to 1-2% in the general population [8,10]. Further, OLP clinical manifestations in children may be atypical causing diagnostic challenges [8,10]. The most common clinical form of OLP in childhood is reticular, followed by erosive/ulcerative, and buccal mucosa and

tongue are the most common locations [6,10,11]. Diagnosis is usually based on clinical and histopathologic findings, while direct immunofluorescence (DIF) is necessary in diagnostically cumbersome cases, in order to distinguish OLP from other vesiculobullous/ulcerative diseases [6,10].

Management of OLP in children is also challenging, mainly including topical treatment options, among which corticosteroids are considered to be the first line treatment. In general, it has been suggested that treatment of LP in children seems to have better results compared to adults, who usually suffer from more persistent lesions and symptoms [6,12,13].

The aim of this study is to present a rare case of erosive/ulcerative OLP in a 3 years old girl and to highlight the importance of careful clinicopathologic correlation for early and accurate diagnosis and discrimination from other vesiculobullous/ulcerative mucocutaneous diseases in childhood.

#### **Presentation of case**

A 3 years old Caucasian female child was referred to an Oral Medicine clinic, due to a history of chronic erosive/ulcerative lesions on the tongue. According to the mother, the lesions were first noticed two years ago with periods of remission and exacerbation and were causing mild discomfort while feeding. The medical history was non-contributory without any known systemic diseases or use of medications. On oral clinical examination, diffuse ulcerations and erosions were noticed surrounded by erythematous and atrophic areas, located on the dorsum and the lateral borders of the tongue; limited areas of whitish papule-like lesions and mild reticulation were noticed in the periphery (**Fig. 1a-c**). There were no other lesions on the skin or other mucous membranes. The clinical differential diagnosis included vesiculobullous/ulcerative diseases, such as erosive/ulcerative OLP, juvenile-onset systemic lupus erythematosus, mucous

membrane pemphigoid, pemphigus vulgaris, and lichen planus pemphigoid. A diagnostic incisional punch biopsy of the dorsum and the right lateral border of the tongue was performed under general anesthesia, due to patient's young age and inability to cooperate under local anesthesia. Microscopic examination revealed an ulcerative lesion covered by a fibrinopurulent membrane; the adjacent stratified squamous epithelium was completely detached from the connective tissue, also showing inflammatory cell exocytosis with areas of hydropic degeneration of the basal cell layer (**Fig. 2a**). In addition, an intense chronic, mainly lymphocytic, inflammatory infiltrate was noticed in the underlying connective tissue, partially in a subepithelial band-like distribution (**Fig. 2b**). Direct immunofluorescence revealed no specific immunophenotypic findings for IgA, IgG, IgM, C1q, C3, C4 and fibrinogen (**Fig. 3 a,b**). The clinical and microscopic findings, along with the lack of immunophenotypic features of other vesiculobullous/ulcerative diseases, such as pemphigus, mucous membrane pemphigoid or lichen planus pemphigoid, led to a final diagnosis of erosive/ulcerative OLP. Treatment with topical corticosteroids of high potency, applied 3 times daily, for two weeks with re-evaluation and tapering upon improvement was administered; in addition, the parents were given oral hygiene and dietary instructions with avoidance of irritating foods. Close follow-up was also recommended.

## **Discussion**

The occurrence of OLP in children and adolescents is rare with few cases reported in the literature [8,10,11,14-22]. In a systematic review of 985 LP cases in childhood, Merhy et al. [6] reported that the oral cavity was affected in 22% (216 patients), among which 7% (70 patients) had only oral lesions, while 15% exhibited both cutaneous and oral lesions. In our case, only oral involvement was present at the time of diagnosis. On the other hand, Cascone et al. [10] reported

that among 34 reported cases of OLP in children, only 5 (14.7%) exhibited extraoral involvement.

In a series of 22 children with OLP, the average age was about 15 years, ranging from 8 to 18 [11]. In a review of the literature, Cascone et al. [10] identified 34 published cases with an age range of 6-17 and an average of 11.18 years. Therefore, our patient of only 3 years of age appears to be one of the youngest OLP pediatric patients reported so far, along with a recently reported case of familial OLP in a 3 years old boy [16]. An almost equal gender predilection of childhood OLP has been reported; in the series of Chatterjee et al. [11], an exact 1:1 male to female ratio was noticed, while Cascone et al. [10] identified 15 reported cases in boys and 19 in girls.

The etiology of OLP in children is unknown. A few studies have suggested that poor oral hygiene may play some role, while others have proposed that OLP may develop as a complication of hepatitis-B or other vaccinations that may trigger a cell-mediated autoimmune response [10,11,18,19]. Other possible predisposing factors are local trauma and contact allergens, drugs, or chemical antigens and dental restorative materials, although the latter may be quite rare in children [6]. Interestingly, among pediatric patients, family history of LP might play an important role, as a rare familial LP type has been recognized, accounting for 1-4.3% of pediatric patients [6,10,16]. In this type, children are usually affected at a younger age, demonstrating higher severity of the disease, more widespread distribution and a tendency to recur [16].

The majority of OLP pediatric cases appear to be asymptomatic; however, burning sensation is the most common symptom and, in many cases, is associated with spicy foods consumption, especially in Indian patients [8,10,19]. For example, Chaitra et al. [19] reported a case of a 9

years old girl with OLP lesions affecting the buccal mucosa and causing burning sensation during consumption of spicy foods. Other reported symptoms are dryness, soreness, pain and stinging. In our case, a discomfort of the child during feeding was the only symptom reported, similar to the case reported by Hasan et al. [21] in an 8 years old boy, also complaining for eating difficulty.

Several clinical variants of OLP are recognized, such as reticular, atrophic, erosive or ulcerative, papular, plaque-like and bullous [1,2]. Different studies demonstrate that the most predominant type of OLP in pediatric patients is the reticular, characterized by small white papules coalescing and forming striated lines (Wicham's striae), followed by the erosive or ulcerative form [6,8,11,20]; in their comprehensive literature review, Cascone et al. [10] reported that reticular and erosive OLP accounted for 70.5% and 32.3% of cases, respectively. Buccal mucosa is the most common intraoral site of involvement followed by the tongue and the gingiva [6,8,11,29]; the corresponding percentages for the three aforementioned locations were 76.4%, 55.8% and 17.6%, respectively [10]. In our patient, lesions were exclusively located on the dorsum and the lateral borders of the tongue in a diffuse erosive/ulcerative form. Similar to our case, Padmini et al. [8] and Hasan et al. [21] noticed ulcerative lesions on the dorsum of the tongue of their patients.

Because OLP clinical features are variable and non-pathognomonic, the differential diagnosis may include several other entities; especially the erosive/ulcerative form of OLP may resemble several other vesiculobullous/ulcerative diseases, which can be distinguished only after histopathologic and DIF examination. In our case, the clinical appearance of diffuse ulcerations along with the microscopic feature of epithelium detachment from the underlying connective tissue at the level of the basement membrane elicited a main differential diagnosis of

erosive/ulcerative OLP or mucous membrane pemphigoid. In the latter, DIF would demonstrate deposition of immunoreactants, consisting of IgG and C3 and, less commonly, IgA and IgM, at the basement membrane zone. The absence of such immunophenotypic findings established the final diagnosis of OLP.

Interestingly, the biopsy procedure of our patient was performed under general anesthesia. Although the vast majority of oral biopsies require just local anesthesia, it is not uncommon for children at this age to not tolerate even a minor oral surgery. Further, invasive dental procedures can increase the anxiety of the child, as well as the parents, who may manifest a negative and reactive behavior that can disturb and complicate clinician's work, especially when subtlety and accuracy are required [23]. In such cases, sedation or general anesthesia can be the preferred approach, in order to secure that the young patient remains calm and an adequate and representative biopsy specimen is obtained.

Treatment of OLP in children does not differ significantly compared to adults. Various topical and systemic therapeutic modalities have been proposed for childhood OLP [6,12,13]. Topical corticosteroids remain the mainstay of treatment of OLP in children, along with adequate plaque control and topical antifungals to prevent secondary infection [10,12]. Studies with alternative topical medications, such as calcineurin inhibitors, e.g. tacrolimus and cyclosporine, are limited in the OLP pediatric population. Sharma et al. [22] reported a case of a 12 years old boy with oral lesions in the gingiva and the posterior mandibular vestibule, who did not respond to topical treatment with triamcinolone acetonide 0.02% and was subsequently managed with topical tretinoin 0.05% (twice daily for two weeks) with remarkable results. Systemic corticosteroid administration is limited only for severe, persistent or recurrent cases, due to patients' young age [6]. In cases of persistent OLP lesions that do not respond to topical treatment, intralesional

corticosteroids may be an effective alternative [17]. The patients should be followed up weekly during therapy [3,22]. In general, OLP lesions in pediatric patients respond better compared to adults [18]. In addition, total remission of the lesions has been reported in 38.2% of cases, which is much higher compared to the corresponding percentage in adults (2-5%) [10]. Overall, prognosis is good, and no malignant transformation of OLP to squamous cell carcinoma has been reported so far [10]. Nonetheless, long term follow-up, at least once or twice a year, is recommended.

### **Conclusions**

The occurrence of OLP in childhood is particularly rare with few published cases in the literature. Nonetheless, OLP should be included in the differential diagnosis of chronic ulcerative lesions of the oral mucosa in children. Accurate diagnosis and discrimination from other, also rare in childhood, vesiculobullous/ulcerative mucocutaneous diseases with oral involvement requires evaluation of the histopathologic and immunophenotypic features and careful clinicopathologic correlation.

**Ethics Statement:** The study was performed in accordance with the Declaration of Helsinki.

### **References**

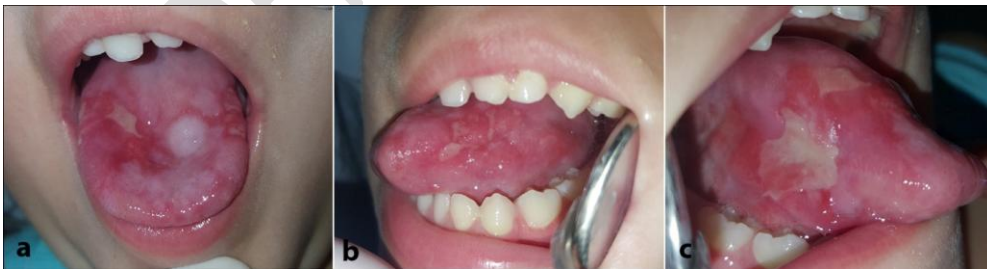1. Carbone M, Arduino PG, Carrozzo M, Gandolfo S, Argiolas MR, Bertolusso G, et al. Course of oral lichen planus: a retrospective study of 808 northern Italian patients. *Oral Dis.* 2009;15(3):235-43.
2. Farhi D, Dupin N. Pathophysiology, etiologic factors, and clinical management of oral lichen planus, part I: facts and controversies. *Clin Dermatol.* 2010;28(1):100-8.
3. Pandhi D, Singal A, Bhattacharya SN. Lichen planus in childhood: a series of 316 patients. *Pediatr Dermatol.* 2014;31(1):59-67.

4. Walton KE, Bowers EV, Drolet BA, Holland KE. Childhood lichen planus: demographics of a U.S. population. *Pediatr Dermatol.* 2010;27(1):34-8.
5. Luis- Montoya P, Dom niguez- Soto L, Vega- Memije E. Lichen planus in 24 children with review of the literature. *Pediatr Dermatol* 2005;22:295- 8
6. Merhy R, Sarkis AS, Assaf J, Afiouni R, Zeinaty P, Kechichian E, et al. Pediatric lichen planus: a systematic review of 985 published cases. *Int J Dermatol.* 2021.
7. Sharma R, Maheshwari V. Childhood lichen planus: a report of fifty cases. *Pediatr Dermatol.* 1999;16(5):345-8.
8. Padmini C, Bai KY, Chaitanya V, Reddy MS. Ulcerative lichen planus in childhood. *Case Rep Dent.* 2013;2013:874895.
9. Kanwar AJ, De D. Lichen planus in childhood: report of 100 cases. *Clin Exp Dermatol.* 2010;35(3):257-62.
10. Cascone M, Celentano A, Adamo D, Leuci S, Ruoppo E, Mignogna M. Oral lichen planus in childhood: a case series. *Int J Dermatol.* 2017;56(6):641-652
11. Chatterjee K, Bhattacharya S, Mukherjee CG, Mazumdar A. A retrospective study of oral lichen planus in paediatric population. *J Oral Maxillofac Pathol.* 2012;16(3):363-7.
12. Malathi M, Thapa DM. Management of Childhood Lichen Planus. *Nepal J Dermatol Venereol Leprol.* 2014;12:1-6.
13. Mutalik SD, Belgaumkar VA, Rasal YD. Current perspectives in the treatment of childhood lichen planus. *Indian J Paediatr Dermatol.* 2021;22:316-25.
14. Alam F, Hamburger J. Oral mucosal lichen planus in children. *Int J Paediatr Dent.* 2001;11(3):209-14.

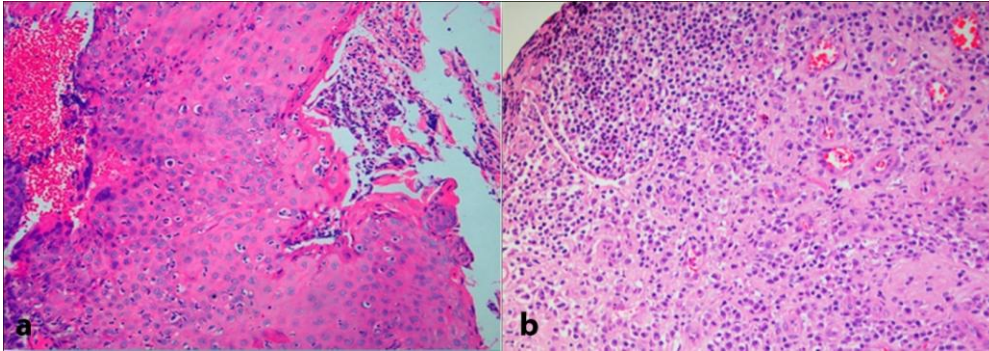
15. Patel S, Yeoman CM, Murphy R. Oral lichen planus in childhood: a report of three cases. *Int J Paediatr Dent.* 2005;15(2):118-22.
16. Wang F, Tan YQ, Zhang J, Zhou G. Familial oral lichen planus in a 3-year-old boy: a case report with eight years of follow-up. *BMC Oral Health.* 2020;20(1):341.
17. De Moraes PC, Teixeira RG, Tacchelli DP, Bönecker M, Junqueira JL, Oliveira LB. Atypical case of oral lichen planus in a pediatric patient: clinical presentation and management. *Pediatr Dent.* 2011;33(5):445-7.
18. George S, John SA, Anandaraj S, Issac JS, Harris A, Reshmi J. Childhood Oral Lichen Planus: Report of Two Cases. *J Dent (Tehran).* 2015 May;12(5):374-8.
19. Chaitra TR, Telgi RL, Kishor A, Kulkarni AU. Juvenile oral lichen planus: a clinical rarity. *BMJ Case Rep.* 2012;2012:bcr2012006192.
20. Woo VL, Manchanda-Gera A, Park DS, Yoon AJ, Zegarelli DJ. Juvenile oral lichen planus: a report of 2 cases. *Pediatr Dent.* 2007;29(6):525-30.
21. Hasan S, Mansoori S, Ansari MI, Siddiqui S. Oral lichen planus in an 8- year- old child: A case report with a brief literature review. *J Oral Maxillofac Pathol* 2020;24:S128-34.
22. Sharma G, Sardana D, Vohra P, Rehani S, Nagpal A. Oral Lichen Planus in a Pediatric Patient: A Novel Therapeutic Approach. *J Dent (Tehran).* 2017;14(2):109-114.
23. Al-Eheideb AA, Herman NG. Outcomes of dental procedures performed on children under general anesthesia. *J Clin Pediatr Dent.* 2003;27(2):181-3.

**Comment [NA1]:** Needs to be edited according to the structure of Case report (20 references)

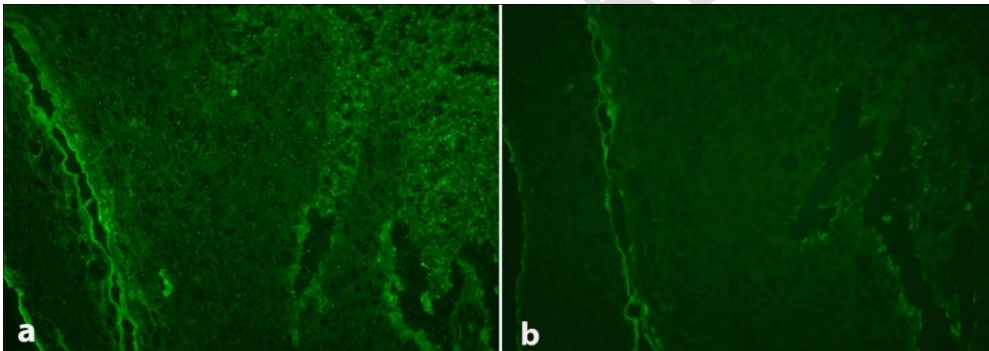
**Figure Legends**



**Figure 1:** Clinical examination. Diffuse erosions and ulcerations with peripheral atrophy and erythema and limited whitish papule-like and striated lesions, located: a) on the dorsum, b) left lateral border and c) right lateral border of the tongue.



**Figure 2:** Histopathologic examination (*H&E original magnification: X 200*). **a)** Completely detached stratified squamous epithelium showing inflammatory cell exocytosis. **b)** The underlying connective tissue shows intense chronic lymphohistiocytic inflammatory infiltrate, mainly in a subepithelial distribution.



**Figure 3:** Direct immunofluorescence (*DIF original magnification X 200*). Absence of specific immunophenotypic findings for: **a)** IgG and **b)** IgM.