

Case study

Mucosal Brucella Infection in Human: a case report during Covid-19 pandemic

Abstract

Brucellosis in human is an uncommon disease in Libya and usually diagnosed by serological assays. The clinical symptoms of this disease in many times are none specific and vague. This report describes a case of clinical human brucellosis in Libya. The patient was a sixteen years old girl, lives in a rural area. She was suffering from intermittent fever for several days associated with chills, mild cough, and headache. The patient had history of occasional drink of goat's raw milk during the previous two months. She had no history of travel abroad and direct animal contacts. Comprehensive physical examination revealed the patient was generally unwell, pallor and, had tenderness and mild hepatosplenomegaly. Laboratory investigations revealed that the patient had pancytopenia (low number of blood cells count) and a marked increase in C-reactive protein (CRP), Procalcitonin (PCT), Lactate dehydrogenase (LDH), Aspartate transaminase (AST). Viral screen tests were non-reactive for HCV, HBs Ag, HIV and covid-19. Provisional diagnosis on admission time was acute leukemia or aplastic anemia with common microbial infection. Empirical antibiotic (Meropenem 1 gm) was prescribed intravenously every eight hours for seven days. The patient was also given antipyretic, IV fluid hydration, and one unit of packed red blood cells. Following that, bacterial growth in aerobic blood culture was noticed and it was Gram-negative coccobacilli, non-motile. The bacterium was positive for catalase, oxidase and urease tests. It could not clearly be identified by phoenix bacterial identification system. It was provisionally diagnosed *Haemophilus* spp., but as it was able to growth on blood agar plate, it was finally diagnosed as *Brucella* spp. and that was confirmed by collection of patient serum and performing Rose-Bengal pate test (RBPT) as was significantly increased (1:640). The patient general condition was improved and blood count recovered over one week. The patient was then discharged and asked for routine follow ups during the next six months.

Keywords: Brucellosis, Brucella, Human, Oral, Mucosal, Infection, Rose-Bengal test.

1. Introduction

Infection with *Brucella* is known as Brucellosis (also known as undulant fever, Malta fever and Mediterranean fever); is a disease that affects various systems in the body with a broad spectrum of symptoms and clinical signs [1]. Patients fail to specify these symptoms that are usually appear within two weeks of inoculation, but sometimes up to six months and the symptoms may last over a number of years if no effective treatment was provided [2].

Comment [UW1]: Abstract must be written in this form:

Introduction: Brucellosis in human is an uncommon disease in Libya and usually diagnosed by serological assays. The clinical symptoms of this disease are none specific which makes differential diagnosis difficult.

Presentation of Case : is too long

Discussion : Author did not summarize discussion

Conclusion : What does the clinical case study bring to the medical literature?

Clinically, it can evolve in different degree as a subclinical, acute, subacute or chronic infection. Occurrence of this disease in human is attributed to close contact with domestic livestock and/or oral intake of contaminated dairy products, such as raw milk of infected goat without pasteurization, or soft cheese contaminated with bacteria called *Brucella melitensis* (*B. melitensis*). Also, the infection with this type of bacterium can be acquired in humans by inhalation of contaminated aerosols through the respiratory mucosa [2]. Accordingly, mucosa of the oral cavity is the first site of contact between Brucella and the host, and it is supplied with mucosa-associated lymphoid tissue (MALT), an immune system mechanism, belongs to the organized lymphoid structures [3].

These bacteria are Gram-negative aerobic, slow in growth, non-motile, non-spore forming coccobacilli and terricolous, that typically cause infection mainly in sheep and goats [4]. They localize inside infected host's cells (intracellular), in particular within the reticuloendothelial system including spleen and liver and other organs of such type. As the causative bacterium is intracellular, recurrence of the infection is frequently observed in cases of brucellosis [1]. Four out of six species of Brucella are known to infect humans. They are *B. melitensis*, in goats and sheep, *Brucella abortus* (*B. abortus*) is found principally in cattle, *Brucella suis* (*B. suis*) in swine and *Brucella canis* (*B. canis*) in kennelraised dogs [5, 6].

The human disease has a prevalence exceeding 10/100 000 population in some regions in the world with endemic nature. Annually around 500 000 new cases of brucellosis are reported worldwide [1]. In Asia, several countries such as China, India, Sri Lanka, and Pakistan are typical examples where the human and animal brucellosis are still widespread. Another different example is in Malaysia where animal brucellosis was reported for the first time in 1950 whereas human Brucellosis was first isolated in 2010 affecting a seven-year boy as a result of drinking an infected raw goat's milk. However, research showed that a large proportion of seropositive patients in Malaysia were veterinarians and farmers who had history of close contact with animals as their occupation request that. Most of the cases (90%) were males with age ranging between 20 and 45 years [6]. In Africa, Brucellosis is an endemic and one of the main zoonotic diseases and its prevalence in animal can be considered as an indicator of the potential existence of infection in human.

Brucellosis in Libya has been reported in individuals, sheep and goats, cattle and camel [7]. Although the availability of significant amount of data concerning clinical manifestations of brucellosis, yet there is shortage in its geographical representation. Absence of data with good quality in the literature from Libya may theoretically represent either a lower burden of disease or a poor surveillance system for brucellosis. Here we report a case of human brucellosis infecting a sixteen-year Libyan girl. **The importance of this case report lies on the following points: firstly, the relatively young age of the patient.** Secondly, the challenging management of such case during the Corona virus (Covid-19) pandemic where access to hospital medical services and facilities in Libya is critical at this time.

Comment [UW2]: Age does not show the particularity of the clinical case because many studies have shown that brucellosis affects all age categories. In my opinion The importance of this case report is the difficult differential diagnosis

2. Case report

A sixteen years old Libyan girl lives in a rural area, presented with seven days history of intermittent fever associated with chills, mild cough, headache, and without history of travelling abroad or animal contact. In the past two months, she was occasionally drinking goat's raw milk. The first complete blood count (CBC) ordered by her general practitioner showed pancytopenia (Table 1) and therefore she was referred to hematology department at National Cancer Institute-Misurata (NCI-M), Libya. On the 15th of June, 2020, she was admitted to the department of hematology with fever 39 °C, no other localizing features. Physical examination revealed unwell general condition, pallor, and tenderness over left hypochondrial area with normotensive; but no palpable lymph nodes, neck stiffness, jaundice or skin rash.

Provisional diagnosis on admission time was acute leukemia or aplastic anemia depending on the acute presentation and first picture of CBC (Table 1). Septic screening was carried out and empirical antibiotic was started with meropenem (1 gm) intravenously (IV) every eight hours for seven days, antipyretic, IV fluid hydration, and one unit of packed red blood cells (PRBC) was transfused. Chest-x ray was normal, abdominal ultrasound scan showed mild hepatosplenomegaly (liver 17 cm and spleen 15.5 cm in size); while echocardiography was normal. Serological viral screen tests by enzyme-linked immunosorbent assay (ELISA) for HCV, HBs Ag, HIV and covid-19 were non-reactive (Table 2). Widal test and Coombs test were negative. C-reactive protein (CRP), Procalcitonin (PCT), Lactate dehydrogenase (LDH) and Aspartate transaminase (AST) were markedly elevated (Table 3). Alanine aminotransferase (ALT) was slightly raised while vitamin B12 (VIT. B12), blood sugar (B.S) and blood urea were normal as shown in Table 3. Hematologically, blood film on the 15th of June (2020) revealed leukopenia, immature myeloid cells and no blasts cells. Bone marrow biopsy showed normal hematopoietic cells with megakaryocytes hyperplasia.

Several blood culture samples/bottles were collected and sent to the laboratory at NCI-M as follows; one bottle was collected in the admission day, and based on the presentation of fever, other two sets of blood culture bottles were collected during three consecutive days. After a period of time (4-6 days), all aerobic blood culture samples showed positive growth; while there was no growth in the anaerobic blood culture bottles.

Positive blood culture bottles were cultivated onto three plates of agar media (MacConkey, blood and chocolate). After three days of aerobically incubation at 35 °C, it was noticed a growth of small tiny colonies on both blood and chocolate; whereas, no growth was detected on the MacConkey agar even after six days (Figure 1). Gram's stain showed faint gram negative coccobacilli cells (Figure 2). Due to biochemical availability in the laboratory, only catalase and oxidase were performed and both of them were positive. Based on that, provisional diagnosis was made as *Haemophilus* spp. However, the bacterium still can grow on blood agar when it was

Comment [UW3]: Author must put the values of the haemogram that allowed him to determine leukemia

Comment [UW4]: CBC?
Author must determine CBC abbreviation

Comment [UW5]: the parameters values of (CRP, Procalcitonin, LDH...) must be put in the paragraphe

Comment [UW6]: not complete sentence

Comment [UW7]: Author have to put the biopsy's photo

repeated several times even on fresh prepared blood agar and it was also able to grow on Mueller-Hinton agar (the colonies appeared after 72 h, see Figure 3). The provisional diagnosis was therefore not convincing. The isolate was sent to Zliten Central Hospital to be identified by phoenix bacterial identification system (Onco2 G-) and the bacterium was identified as *Kingella denitrificans* with confidence (96%); while antimicrobial susceptibility could not be detected. *K. denitrificans* is facultative anaerobic and β -hemolytic coccobacilli. As the isolated bacterium grew only aerobic and was non-haemolytic, *K. denitrificans* can be excluded. After a period of time that was spent to look at literatures, the final diagnosis was *Brucella* spp.

During the treatment at NCI-M, the general condition of the patient was improved with medications and blood count recovered spontaneously over one week. The patient was then discharged from NCI-M.

Recent follow-up was eight weeks later, the patient visited our hematology clinic, and she was asymptomatic with unremarkable physical examination and normal full blood count. As the bacterial isolate was finally diagnosed as *Brucella* spp.; Rose Bengal plate test (RBPT) was done and its titration in the serum was very high (1:640) which was confirming the brucellosis (Tables 2). Some other blood tests were repeated to avoid relapsing the infection and all of them were normal (Tables 1 and 3). Blood culture also was repeated and no growth was detected.

Antibiotic susceptibility test was performed using disc diffusion method according to the Clinical & Laboratory Standards Institute (CLSI). After three days of incubation, the zone of inhibition diameters were measured and they were as follows: meropenem (10 μ g), imipenem (10 μ g), ciprofloxacin (5 μ g), azithromycin (15 μ g), cefotaxime (30 μ g), ceftriaxone (30 μ g), chloramphenicol (30 μ g), augmentin (30 μ g) and doxycycline (30 μ g) the zone of inhibition diameters were >30 mm. The zone of inhibition diameters of 15-20 mm were for cefixime (5 μ g), cefuroxime (30 μ g), ceftazidime (30 μ g), erythromycin (15 μ g) and bactrim (trimethoprim-sulfamethoxazole, 25 μ g); whereas, no zone of inhibition were detected for vancomycin (30 g) and clindamycin (2 μ g) (Figure 4).

Table1: The haemogram results of the patient during the brucellosis.

| Date | RBC $\times 10^6/\mu\text{l}$ | HB g/dl | MCV fl | MCHC g/dl | WBC $\times 10^3/\mu\text{l}$ | NEUT $\times 10^3/\mu\text{l}$ | LYMPH $\times 10^3/\mu\text{l}$ | PLATELETS $\times 10^3/\mu\text{l}$ | ESR 1 hour |
|------------|----------------------------------|------------|-----------|--------------|----------------------------------|-----------------------------------|------------------------------------|--|---------------|
| 13/06/2020 | 3.1 | 9.7 | 92 | 33.9 | 1.6 | 0.6 | 0.9 | 32 | 35 |
| 14/06/2020 | 3.08 | 9.3 | 95.8 | 31.5 | 2.3 | 0.8 | 1.3 | 59 | 6 |
| 15/06/2020 | 2.5 | 7.5 | 96.8 | 30.7 | 2.2 | 0.9 | 1.0 | 37 | - |
| 16/06/2020 | 3.2 | 9.6 | 96.6 | 30.6 | 3.2 | 1.2 | 1.6 | 44 | - |
| 17/06/2020 | 2.9 | 8.8 | 96.6 | 30.9 | 5.0 | 1.9 | 2.7 | 94 | - |

| | | | | | | | | | |
|------------|------|------|-------|------|-----|-----|------|-----|---|
| 20/06/2020 | 2.8 | 8.3 | 98.9 | 29.9 | 4.0 | 1.6 | 2.11 | 256 | - |
| 23/06/2020 | 2.8 | 8.6 | 104.3 | 29.4 | 3.8 | 1.3 | 2.1 | 409 | - |
| 11/08/2020 | 4.30 | 13.3 | 98.6 | 31.8 | 5.9 | 3.5 | 1.9 | 343 | 8 |

RBC: red blood cells, HB: hemoglobin, MCV: mean corpuscular volume, MCH: mean corpuscular hemoglobin, MCHC: mean corpuscular hemoglobin concentration, WBC: white blood cell, NEUT.: neutrophils, Lymph.: lymphocytes, ESR: Erythrocyte sedimentation rate,

Table2: The results serological tests of the patient during the brucellosis.

| Date | HIV | HBV | HCV | Widal test | Covid19 IgG & IgM | RBPT |
|------------|-----|-----|-----|------------|----------------------|-----------|
| 13/06/2020 | - | - | - | -ve | - | - |
| 14/06/2020 | -ve | -ve | -ve | - | - | - |
| 11/08/2020 | - | - | - | - | -ve | +ve 1:640 |

HIV: human immunodeficiency viruses, HBsAg: hepatitis B virus surface antigen, HCV: hepatitis C virus, Covid19: Coronavirus disease 2019, RBPT: Rose-Bengal plate test, -: not performed, -ve: negative, +ve: positive, IgG: immunoglobulin G, IgM: immunoglobulin M.

Table 3: The blood biochemistry results of the patient during the brucellosis.

| Date | LDH IU/l | CRP mg/l | PCT | Urea mg/dl | Creatinine mg/dl | ALT IU/l | AST IU/l | VIT. B12 | B.S mg/dl |
|------------|-------------|-------------|------|---------------|---------------------|-------------|-------------|-------------|--------------|
| 14/06/2020 | 1572 | - | - | 37.1 | 0.4 | 49.1 | 187 | 550 | 96 |
| 17/06/2020 | 720 | 93.3 | - | - | - | - | - | - | - |
| 18/06/2020 | - | - | 12.3 | - | - | - | - | - | - |
| 11/08/2020 | 119 | 1.8 | <0.1 | - | - | 12.3 | 15.6 | - | - |

LDH: Lactate dehydrogenase, CRP: C-reactive protein, PCT: Procalcitonin, ALT: alanine aminotransferase AST: Aspartate transaminase, VIT: vitamin, B.S: blood sugar, -: not performed.



Figure 1: Three days old blood agar plate shows the colonies of *Brucella* strain isolated from the patient's blood sample.

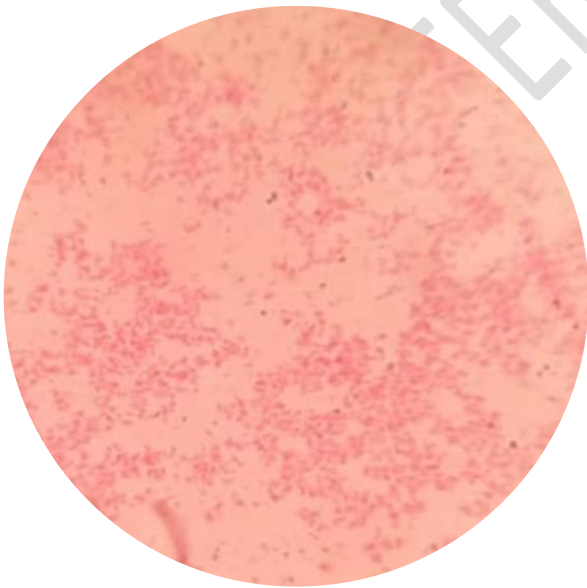


Figure 2: Gram's stain smear of three days old bacterial growth of the isolated *Brucella* spp. on blood agar shows small faint Gram-negative coccobacilli cells.




Figure 3: Three days old Mueller-Hinton agar plate shows a growth of the isolated *Brucella* spp.



Figure 4: Antibiotic susceptibility test for the isolated *Brucella* spp. to meropenem (MEM; zone of inhibition diameter >30 mm) and vancomycin (VA; no zone of inhibition).

3. Discussion

Brucellosis continues to exist as one of zoonotic diseases of greatest significance and is reappearing in some areas all over the world. At present, the highest incidence of human disease is observed in different areas worldwide as in Africa, Asia, the Middle East and Latin America [2]. In Libya, many regions are endemic for brucellosis [7]. Brucellosis is caused by intracellular Gram-negative bacterium called Brucella. Human brucellosis is associated with low-rate of mortality (<5%), largely as a result of endocarditis. Yet, this disease can produce severe chronic consequences with high percentage of mortality.

The acute symptoms that appear on individuals infected with Brucella include intermittent fever, myalgia and several clinical presentations that manifest in form of splenomegaly, hepatomegaly and spondylitis [8]. Formation of abscesses in organs such as spleen, liver and lung can also be seen. Overall, the estimated proportions of 15%, 23% and 26% of cases show lymphadenopathy, hepatomegaly and splenomegaly respectively [8]. Though being uncommon, infective endocarditis is the most destructive result of brucellosis, and may necessitate to be treated surgically. Conditions such as meningitis, nephritis, leukocytoclastic vasculitis, and deep vein

Comment [UW8]: Remove this sentence

thrombosis are also rare results of this disease. The ocular findings associated with brucellosis usually express as optic neuritis, uveitis and papilledema [9]. The hematological manifestations commonly involve thrombocytopenia, leukopenia, and anemia [10]. Thus, brucellosis may manifest in a delicate manner which makes its diagnosis very challenging with cardiac and neurological presentations to be extremely rare. Since brucellosis is classified as a tricky infectious disease, it can imitate many diseases characterized by their ability to affect various systems in the human's body, displaying large clinical multiformity, which often results in misdiagnosis and delays in medical care, thus raising the risk of complications [1].

Mucosa of oral cavity is *Brucella*'s first interaction point with the host and it is supplied with a mechanism of immune system connected with mucosa-associated lymphoid tissue (MALT). As a result, this bacterium should trigger an immune recognition response in this site [3]. The oral cavity is in persistent exposure to variety of pathogens such as food, microbiota, *E. coli*, *Salmonella* spp., *Brucella* spp. or air antigens and is affected mechanically by masticatory damage rendering this place of considerable hostility. Thus, the oral mucosa has mechanisms of defense and tolerance [11, 12]. In the beginning, when *Brucella* reaches the oral cavity, it come across number of defense mechanisms such as saliva, containing elements that suppress or down regulate microbial growth, such as lysozyme, lactoferrin, nystadine, peroxidases and immunoglobulins (Ig), mainly of type A (Ig A). There is also the gingival crevicular fluid which fills the area between the teeth and the gingiva, known as the gingival sulcus. This fluid encompasses complement molecules, antibodies, neutrophils, and plasma cells.

Consequently, the combination of saliva and gingival crevicular fluid acts as a first strong barrier in the face of pathogenic microorganisms [12]. Phagocytic cells also exist in the mucosal tissue which identifies pathogens like *Brucella*. Phagocytic cells as dendritic cells and macrophages (antigen-presenting cells, APCs) are distributed along the specialized tissue of the oral cavity. They are capable of catching antigens and move them to the cervical lymph nodes as they are the closest regional lymph node [3]. After they have captured the oral mucosal antigens, APCs move to the lymph node (LN) to present the antigen to the lymphocytes and send the appropriate activation signal [12, 13]. It has been reported that many cases with brucellosis displaying cervical lymphadenopathy (inflammation in cervical lymph nodes) that had seemingly got the infection through their ingestion of foodstuffs contaminated with the pathogen. Oral cavity, eyes, and nasal mucosa have lymphatic drainage through submandibular maxillary lymph nodes which can function as a source for *Brucella* and stay inert for long periods of time reach up to 50 days [3].

The patient we presented here showed some of the above mentioned manifestations as she presented with history of intermittent fever (seven days) associated with chills, mild cough, headache pallor, and tenderness, mild hepatosplenomegaly and without history of animal contact. However, she had history of infrequent drinking of raw goat's milk. Laboratory investigations revealed that the patient had pancytopenia and a marked increase in LDH, PCT, AST, CRP levels and positive bacterial growth in blood culture. The patient was referred to NCI-M and it

Comment [UW9]: the text starting with "Mucosa of oral cavity " and ending with "up to 50 days " presents the way of bacterium's penetration "mucosa bucale" and explains the immunological mechanism that leads to lymphadenopathy while your patient does not show this clinical sign

Comment [UW10]: remove this paragraph because it is a repetition

Comment [UW11]: Laboratory investigation marked increase in LDH..... Author should discuss the results of the biochemical parameters

Comment [UW12]: Remove repetition

was supposed the patient has hematological disorders (acute leukemia or aplastic anemia). It was suspected that the patient could have microbial infection as secondary diseases due to the fever, markedly increased of infection markers (CRP and PCT) and detection of bacterial growth in the blood culture. However, the bone marrow studies did not approve the hematological disorders. The microbial provisional diagnosis for the isolated bacterium was *Haemophilus* spp. The patient was treated with a broad-spectrum antibacterial agent (Meropenem) and the isolated bacterium was susceptible to meropenem. Interestingly, within ten days the patient completely recovered even CBC parameters was back to normal. Based on this information, the case was manifested in a delicate manner which made its final diagnosis challenging. Thus, it was thought further professional investigations were necessarily required to deeply explain the delicate manner of this case and reveal the final diagnosis. The patient was asked for routine follow up.

Comment [UW13]: Remove repetition

In the microbiology laboratory, the identical bacterial isolates were obtained from all collected blood culture bottles that were aerobically incubated. It was confirmed that it can grow on fresh blood agar and even on Mueller-Hinton agar without addition of blood or V and X factors. It was Gram-negative coccobacilli, oxidase and catalase positive. In our laboratory, it was somewhat a new experience and challenging to fully identify this isolate due to shortage in laboratory facilities. Based on that, the isolate cannot be *Haemophilus* spp; thus the isolates was sent to another Hospital to be fully identified by phoenix bacterial identification system, but the result was inconclusive and molecular identification at that time was unavailable. It was stated that Brucella in the laboratory can be misdiagnosed and confused with other bacteria like Haemophilus, Moraxella and Ochrobactrum [14, 15]. Reviewing literatures revealed that based on the above finding, Brucella cannot be ruled out and that was confirmed by positive result of urease production (Ref. ASM 2016). It was reported that identifications by biochemical testing using automated systems and manual multi-test kit, may not give the correct identification due to Brucella minimal reactivity. This conclusive result of Brucellosis then can clearly explain the first presentation of clinical symptoms in particular pancytopenia, intermittent fever, the marked increase of PCT, CRP and the obtained bacterium in blood culture.

Comment [UW14]: Remove repetition

Comment [UW15]: what does this mean?

Giving the attention to Brucella infection, the brucellosis in our area is usually detected by performing serological tests as they are fast, the most accurate and convenient, particularly in institutions other than reference laboratories [6, 16]. In post Brucella infection, the high levels of Brucella antibodies can stay for several weeks or months to be normalized [6]. As by now, *Brucella* spp. cannot be ruled out, the patient should have increased level of Brucella antibodies. Therefore, in the next follow up (after 40-45 days from hospital discharge) for the patient, RBPT was performed and the detected titration of antibodies was very high (>1:640) as the normal level should be less than 1:8 [16]. Moreover, the patient was not treated as it has been reported in the most of literatures due to misidentification of the isolate in the beginning; nonetheless, the patient was fully recovered. The explanation of that, meropenem could be an effective treatment for Brucellosis or the patient spontaneously recovered. Meropenem was documented to be

Comment [UW16]: replace by: Ultimately

effective treatment on experimental brucellosis[17] and can subside the fever caused by brucellosis[18].

Due to the pandemic of Covid-19 and the associated restrictions applied by the authorities regarding the travel between the cities in order to control spread of the disease, the treating team continued to follow-up the patient from a distance over phone contact. For a period of more than three months no sign or symptoms of relapse was reported by the parents of the patient.

Diagnosis of brucellosis can be made depending on the symptoms, serological tests and blood culture accompanied by other differential diagnosis [19]. While rare, infection with *Brucella* must be addressed as a new cause of cardiac insufficiency, particularly in areas classified as endemic territories while it is treatable with effective antibiotic regimen [20]. Early recognition and diagnosis of Brucellosis necessitates use of several diagnostic elements including a thorough medical history, comprehensive clinical examination, and hematological assays, biochemical assays, imaging studies, microbiological tests as well as specific molecular and serological tests for *Brucella* detection. Several serological tests are available including serum agglutination test, Coombs test, complement fixation test, indirect immunofluorescent antibody test and ELISA. However, RBPT has been proved as an inexpensive, rapid and successful serological test. RBPT can be done with a limited number of tools, and the findings can be interpreted macroscopically with reliable results [15]. Yet, specific tests such as IgG and IgM are required to evaluate the disease activity and determine the actual level of the antibodies.

Variation in the standard treatments has been reported. Factors such as age of the patient and pregnancy status are affecting this difference in selection of standard treatments [21]. No statistical difference has been found with respect to the form of combination therapy on the initial clinical response of human brucellosis. The preferred antibiotic regimen for treatment of infected person with brucellosis is doxycycline 100 mg *p.o.* two times daily in combination with rifampicin 450 mg once daily *p.o.* for 6 weeks [22]. However, several treatments in form of a combination of antibiotics have been also recommended as the following. Below age of 8 years, a combination therapy of trimethoprim-sulfamethoxazole and aminoglycoside [23]. Alternatively, a combination of rifampicin and trimethoprim-sulfamethoxazole for 6 weeks is required [24]. For patients with age of 8 years and older, doxycycline and rifampicin combination could be prescribed or instead a combination of rifampicin and gentamicin [25]. Rifampicin combined with ciprofloxacin has also proven successful for 4 weeks and gives the benefit of shorter treatment time [26].

4. Conclusion

This case report contributes to the comprehension of the human brucellosis, one of the more prevalent and significant zoonotic infections worldwide. Infection with *Brucella* has been described to have an important, disabling and sometimes persistent effect on its patients. Large

Comment [UW17]: remove this paragraph
Author has not conducted a statistical study to say that No statistical difference has been found with respect to the form of combination therapy on the initial clinical response of human brucellosis.

delays in timely diagnosis and treatment are the product of both shortfalls in the health care system and factors related to financial and social status. Epidemiological research from regions known to be endemic with Brucella and devoid of information could enable a clearer understand of the clinical manifestations of this disorder and its acquiring hazards and present more information for developing policies. We emphasize that clinicians and microbiologists should never overlook brucellosis in the differential diagnosis of febrile diseases especially in developing countries. Traditional simple biochemical tests should not be neglected, sometime these tests still very essential in identifying extraordinary bacterium like Brucella as it could be misidentified by most of modern used biochemical identification systems. Very limited attention has been given to the oral cavity as being the first point of interaction between the body and Brucella. Since mucosa of the oral cavity is the primary location of infection, more attention should be given to the position of lymph nodes draining to the head and neck region. It is also probable that the oral route is an upcoming means of vaccination.

Comment [UW18]: Remove it and start the sentence by in perspective, must more attention should be given to the position of lymph nodes draining to the head and neck region. It is also probable that the oral route is an upcoming means of vaccination.

References

1. Buzgan, T., et al., *Clinical manifestations and complications in 1028 cases of brucellosis: a retrospective evaluation and review of the literature*. *Int J Infect Dis*, 2010. **14**(6): p. e469-78.
2. Olsen, S.C. and M.V. Palmer, *Advancement of knowledge of Brucella over the past 50 years*. *Vet Pathol*, 2014. **51**(6): p. 1076-89.
3. López-Santiago, R., et al., *Immune Response to Mucosal Brucella Infection*. *Frontiers in Immunology*, 2019. **10**(1759).
4. Shaqinah N, M.M., Zamri-Saad M, Hazilawati H, Jasni and S., *In vitro penetration and survival of Brucella melitensis in lymphocytic cells of goats*. *Online J Vet Res* 2012. **16**(3): 104-110.
5. Kang, S.I., et al., *Advanced multiplex PCR assay for differentiation of Brucella species*. *Appl Environ Microbiol*, 2011. **77**(18): p. 6726-8.
6. Hartady, T., et al., *Clinical human brucellosis in Malaysia: a case report*. *Asian Pacific Journal of Tropical Disease*, 2014. **4**(2): p. 150-153.
7. Gameel, S.E.A.M., et al., *Prevalence of camel brucellosis in Libya*. *Tropical Animal Health and Production*, 1993. **25**(2): p. 91-93.
8. Dean, A.S., et al., *Clinical manifestations of human brucellosis: a systematic review and meta-analysis*. *PLoS Negl Trop Dis*, 2012. **6**(12): p. e1929.
9. Rolando, I., et al., *Ocular manifestations associated with brucellosis: a 26-year experience in Peru*. *Clin Infect Dis*, 2008. **46**(9): p. 1338-45.
10. Sari, I., et al., *A multicenter retrospective study defining the clinical and hematological manifestations of brucellosis and pancytopenia in a large series: Hematological malignancies, the unusual cause of pancytopenia in patients with brucellosis*. *Am J Hematol*, 2008. **83**(4): p. 334-9.
11. Feller, L., et al., *Oral mucosal immunity*. *Oral Surg Oral Med Oral Pathol Oral Radiol*, 2013. **116**(5): p. 576-83.
12. Meyle, J., et al., *The innate host response in caries and periodontitis*. *J Clin Periodontol*, 2017. **44**(12): p. 1215-1225.

Comment [UW19]: bibliographic references are not written according to the standards of the journal

13. Walker, D.M., *Oral mucosal immunology: an overview*. Ann Acad Med Singap, 2004, **33**(4 Suppl): p. 27-30.
14. Elsaghir, A.A.F. and E.A. James, *Misidentification of Brucella melitensis as Ochrobactrum anthropi by API 20NE*. J Med Microbiol, 2003, **52**(Pt 5): p. 441-442.
15. Batchelor, B.I., et al., *Biochemical mis-identification of Brucella melitensis and subsequent laboratory-acquired infections*. J Hosp Infect, 1992, **22**(2): p. 159-62.
16. Díaz, R., et al., *The Rose Bengal Test in human brucellosis: a neglected test for the diagnosis of a neglected disease*. PLoS Negl Trop Dis, 2011, **5**(4): p. e950.
17. Maletskaiia, O.V., *[Efficacy of some new antibiotics in treating experimental brucellosis]*. Antibiot Khimioter, 2002, **47**(11): p. 13-7.
18. Ertem, M., et al., *Brucellosis transmitted by bone marrow transplantation*. Bone Marrow Transplant, 2000, **26**(2): p. 225-6.
19. Villaverde, M., et al., *[Febrile syndrome: myocarditis and brucellosis]*. Medicina (B Aires), 1995, **55**(2): p. 145-6.
20. Efe, C., et al., *A rare complication of Brucella infection: myocarditis and heart failure*. Intern Med, 2009, **48**(19): p. 1773-4.
21. Figueroa Damian, R., L. Rojas Rodríguez, and E.S. Marcano Tochon, *[Brucellosis in pregnancy: course and perinatal results]*. Ginecol Obstet Mex, 1995, **63**: p. 190-5.
22. Skalsky, K., et al., *Treatment of human brucellosis: systematic review and meta-analysis of randomised controlled trials*. Bmj, 2008, **336**(7646): p. 701-4.
23. Lubani, M.M., et al., *A multicenter therapeutic study of 1100 children with brucellosis*. Pediatr Infect Dis J, 1989, **8**(2): p. 75-8.
24. Solera, J., E. Martínez-Alfaro, and A. Espinosa, *Recognition and optimum treatment of brucellosis*. Drugs, 1997, **53**(2): p. 245-56.
25. *Joint FAO/WHO expert committee on brucellosis*. World Health Organ Tech Rep Ser, 1986, **740**: p. 1-132.
26. Agalar, C., S. Usubatun, and R. Turkyilmaz, *Ciprofloxacin and rifampicin versus doxycycline and rifampicin in the treatment of brucellosis*. Eur J Clin Microbiol Infect Dis, 1999, **18**(8): p. 535-8.