

## Case study

# Bullous Hemorrhagic Dermatitis Induced By Heparin: an Indonesian Case Report

Formatted: English (United States)

### ABSTRACT

**Introduction:** Bullous haemorrhagic dermatosis is a rare clinical disorder which is usually related to a treatment with unfractionated heparin (UFH) or low molecular weight heparin (LMWH), characterized by multiple intra-epidermal haemorrhages distant from the site of injection.

Formatted: English (United States)

**Presentation of case:** A 62-year-old male patient with coronary heart disease who received heparin treatment experienced several tense, haemorrhagic bullae located on the right arm area, close to the injection site, and followed by the formation of several hematomas on his back trunk 2 days after he had received UFH. The lesions ~~were~~ regressed after ~~the~~ discontinuation of heparin and supportive topical treatments.

**Discussion:** The lesions in this patient have similar characteristic with heparin-induced skin necrosis and demonstrate thrombocytopenia probably related to heparin. There are some proposed hypotheses of pathophysiology which ~~have~~ included hypersensitivity reaction and idiosyncratic dose-related reaction ~~with dose-related reaction~~. Given the clinically course, the discontinuation of heparin treatment was essential for lesions regression; ~~despite in addition~~ other supportive ~~care~~ measures.

**Conclusion:** Heparin-induced skin lesions may indicate the presence of life-threatening heparin-induced thrombocytopenia. An early diagnosis is crucial to enable discontinuation of heparin if required.

*Keywords: low molecular weight heparin, UFH, bullous haemorrhagic dermatosis, hypersensitivity, idiosyncrasy, dose-related reaction*

## 1. INTRODUCTION (ARIAL, BOLD, 11 FONT, LEFT ALIGNED, CAPS)

Heparin is a powerful anticoagulants used in the prophylaxis and management of thromboembolic disorders, including patients with Acute Coronary Syndrome (ACS). On the market today, there are two ~~dosage~~ forms available: the unfractionated heparins (UFHs) and the other ~~named~~ called the low-molecular-weight heparins (LMWHs).(1) Previously, several adverse effects of heparin were already reported such as heparin related clotting ~~derangement~~ disturbance that ~~can~~ caused bleeding ~~issue~~, heparin related thrombocytopenia (HIT), and several types of cutaneous reactions. These cutaneous side effects may be localized or generalized, vary in form, from allergic reactions (e.g., erythema, urticaria, dermatitis) to a more severe condition named intradermal micro vascular thrombosis associated with heparin-induced thrombocytopenia (HIT).(2) Rarely, there is a type of cutaneous complication, named bullous haemorrhagic dermatosis. Perrinaud et al., reported

Formatted: English (United States)

a condition of bullous haemorrhagic dermatosis that had developed right after heparin injection and manifested clinically in the form of multiple haemorrhagic intraepidermal bullae that developed in the patient's body location that actually far from the heparin injection sites. (2) The mechanism underlying the pathogenesis of these lesions is still not completely clear; however, some mechanisms are considered such as follows, including delayed type (type IV) hypersensitivity response, type II immune mediated thrombocytopenia, type I allergic reaction, skin necrosis and pustulosis. (3) Epidemiologically, this side effect of heparin is quite rare and not often reported.

Here we reported a case of bullous haemorrhagic dermatosis induced by heparin, and to our knowledge this is the first time case reported in Indonesia. Furthermore, we also want to review the current literature regarding this condition and its underlying mechanism.

## 2. PRESENTATION OF CASE

A 62-year-old man with an acute inferior STEMI was admitted to the emergency department due to primary Percutaneous Coronary Intervention (PCI). After having undergone the intervention, due to because of his renal insufficiency condition, he was administered continuous infusion of UFH. Two days after the heparin administration, the patient underwent developed numerous haemorrhagic bullae that felt painful and tense right on his lower right arm, near the site of heparin injection. He also suffered from several hematomas on his back trunk.

Results of laboratory studies showed a low haemoglobin concentration of 12.2 g/dl. A decrease in his platelet count was noticed during 4 days hospitalization, from 478.000/uL in the first day of hospitalization to 196.000/uL. A biopsy specimen of the bullae revealed intra-epidermal bullae with red blood cells, without thrombotic or vascular lytic changes. Depending on the clinical and histopathology findings, heparin-induced bullous haemorrhagic dermatosis was suspected.

Heparin was discontinued and the patient was given normal saline wound dressing twice a day, mupirocin 2% ointment, emollient soothing lotion, and bullae aspirations. Within one week, the bullous haemorrhagic lesions were dried out and improved. The patient was discharged without any recurrence of haemorrhagic bullous lesions.

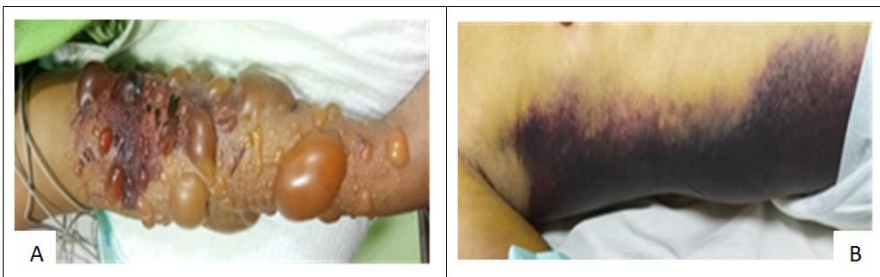


Figure 1: Clinical presentation of a the patient with a major finite bullous hemorrhagic dermatosis due to heparin administration. (A) On the area of lower right arm, there are multiple bullae and vesicles, some filled with blood (hemorrhagic), and in its perimeter developed clear indurated erythema developed in its perimeter. (B) Hematomas developed on the back trunk

Formatted: English (United States)

Formatted: English (United States)

Formatted: English (United States)

Formatted: English (United States)

Formatted: English (United States)

Formatted: English (United States)

Formatted: English (United States)

Formatted: English (United States)

Formatted: Highlight

Formatted: English (United States)

Formatted: English (United States)

Formatted: English (United States)

Formatted: English (United States)

Formatted: English (United States)

### 3. DISCUSSION

Bullous haemorrhagic dermatosis (BHD) is a blistering eruption typically associated with either unfractionated or low-molecular weight heparins.(4) In 2006, Perrinaud et al., reported ~~the incidence of~~ the first 3 cases of BHD ~~subsequently~~ right after heparin injection given subcutaneously.(2) Since then, along with the more widespread use of heparin injection among thromboembolic patients, ~~the more cases of~~ have heparin related side effect been ~~have~~ published from all over the world; and until to date, only ~~a~~ limited number of cases has been made available on the internet.

Our case related to ~~a~~ patient with ~~an~~ acute coronary syndrome who ~~was~~ admitted to hospital to receive primary percutaneous coronary intervention (PCI) and ~~who was~~ given heparin during hospitalization. It is ~~already~~ known from previous reports that there was ~~a~~ ~~consistently~~ ~~an~~ immediate chronological relationship between the initiation of heparin products to susceptible individual until the onset of definite bullae formation; the duration is between 5 to 21 days though there were cases with very rapid onset, occurring ~~within~~ 2-3 days.(5) ~~In our case, the patient developed~~ numerous painful, ~~numerous~~ tense haemorrhagic bullae that ~~varied~~ in size, at his right arm 2 days after heparin administration. The most severe lesions were on the cubital fossa, near the injection site of the heparin. The severity of the lesions is inconsistent with other haemorrhagic bullae which have ~~already~~ been ~~previously~~ reported, because it ~~was~~ ~~had~~ only begun as a clinically benign course with no ~~involvement of~~ pain or even pruritus.(6) Therefore, we also suspect other heparin-induced cutaneous reaction including ~~Heparin~~ heparin-induced skin necrosis (HISN). HISN typically develops with painful erythematous lesion on the injection site within days to weeks of heparin treatment.(7)

Heparin rarely causes diffuse necrosis, and it may signify the life-threatening cutaneous manifestation of heparin-induced thrombocytopenia (HIT), a serious paradoxical hypercoagulable state, as it may cause arterial and venous thromboembolic complications.(8) The incidence of thrombocytopenia ~~was~~ ~~reported~~ ten times higher with UFH than with LMWH.(7) The pathogenesis of this condition is not clear.(9) Since our patient ~~was~~ ~~had~~ received ~~a~~ weight-based protocol continuous intravenous UFH, we hypothesize ~~that~~ it ~~was~~ related to ~~a~~ dose-related reaction. In some studies, the underlying mechanism ~~may~~ ~~was~~ ~~assumed to~~ be due to a condition of idiosyncratic reaction ~~that~~ triggered by heparin or its metabolite(2), in this patient, heparin was the only new drug temporarily associated with the skin eruption. Furthermore, the laboratory test results in our patient showed a 59% decreased platelet count from baseline followed by spontaneous platelet ~~re~~convalescence occurring ~~in~~ the next 2 days after discontinuation of UFH. The condition of thrombocytopenia occurs in at least 85–90% of patients with HIT and ~~is~~ marked by a decrease in platelet count ~~of that can~~ be found in 50% patients, and skin lesions occurred in 10-20% of patients with HIT.(7) In our patient, HIT occurred within 3 days after start of heparin treatment and it is intriguing that this finding is inconsistent with the characteristic of HIT that occurs between 5-14 days after start of heparin.(7) In our case, we did not include further assessment, such as platelet count monitoring.(10) Repetitive platelet monitoring between days 4 and 14 is highly encouraged, as a pre-emptive option, in all patients who have a risk for heparin-induced thrombocytopenia.(7,11) Specific underlying conditions of the patients must also be considered as a potential risk.(12,13)

Even though management of BHD remains unclear, discontinuation of heparin or other possible causes is mandatory and supportive care of the lesions ~~are~~ ~~is~~ important in the treatment of this disease.(5,14,15) ~~Although~~ ~~However~~, in some severe cases, high dose steroid should be considered.(5) Some clinicians reported similar cases, but even when

Formatted: English (United States)

Formatted: English (United States)

Formatted: English (United States)

Formatted: English (United States)

Formatted: English (United States)

Formatted: English (United States)

Formatted: English (United States)

Formatted: English (United States)

Formatted: English (United States)

Formatted: English (United States)

Formatted: English (United States)

Formatted: English (United States)

Formatted: English (United States)

Formatted: English (United States)

Formatted: English (United States)

Formatted: English (United States)

Formatted: English (United States)

Formatted: English (United States)

Formatted: English (United States)

Formatted: English (United States)

Formatted: English (United States)

Formatted: English (United States)

Formatted: English (United States)

Formatted: English (United States)

Formatted: English (United States)

Formatted: English (United States)

Formatted: English (United States)

Formatted: English (United States)

Formatted: English (United States)

Formatted: English (United States)

Formatted: English (United States)

Formatted: English (United States)

Formatted: English (United States)

Formatted: English (United States)

Formatted: English (United States)

heparin was kept administered for some time and fortunately, the lesions improved. This improvement maybe due to the natural origin of this disease that it is typically self-limiting.(3)

The weakness of this report lies on not performing ~~ingee~~ direct immunofluorescence, therefore the involvement of complement and immunoglobulin in this haemorrhagic blister formation could not be determined.(16-18)

Formatted: English (United States)

#### 4. CONCLUSION

Bullous haemorrhagic dermatosis secondary to heparin treatment has been reported in the literature but is under-recognized in clinical practice. Hence, knowledge of the characteristic clinical features of heparin-induced BHD ~~are-is~~ important for clinicians, especially if HIT is suspected, as it may lead to serious morbidity and mortality.

Formatted: English (United States)

Formatted: English (United States)

#### CONSENT (WHERE EVER APPLICABLE)

"All authors declare that 'written informed consent was obtained from the patient (or other approved parties) for publication of this case report and accompanying images. A copy of the written consent is available for review by the Editorial office/Chief Editor/Editorial Board members of this journal."

Formatted: English (United States)

#### REFERENCES

1. Rodríguez-Fernández A, Sánchez-Domínguez M, Torrado-Español I, Noguero-Mellado B, Rojas-Pérez-Ezquerro P. Clinical Patterns of Heparin Allergy: Cross-reactivity Between Low-Molecular-Weight Heparins and Unfractionated Heparins. *Journal of investigational allergology & clinical immunology*. 2019;29(2):132-4.
2. Perrinaud A, Jacobi D, Machet MC, Grodet C, Gruel Y, Machet L. Bullous hemorrhagic dermatosis occurring at sites distant from subcutaneous injections of heparin: three cases. *Journal of the American Academy of Dermatology*. 2006;54:S5-S7.
3. Gouveia AI, Lopes L, Soares-Almeida L, Filipe P. Bullous hemorrhagic dermatosis induced by enoxaparin. *Cutaneous and ocular toxicology*. 2016;35(2):160-2.
4. Frizzell MR, Nguyen NM, Goldberg LH, Parikh SA, Sinai MJ. Heparin-induced bullous hemorrhagic dermatosis: A report of 3 cases. *JAAD case reports*. 2020;6(10):1065-8.
5. Shim JS, Chung SJ, Kim BK, Kim SH, Lee KS, Yoon YE, et al. Bullous hemorrhagic dermatosis due to enoxaparin use in a bullous pemphigoid patient. *Asia Pacific allergy*. 2017;7(2):97-101.
6. Govind B, Gnass E, Merli G, Eraso L. Hemorrhagic bullous dermatosis: a rare heparin-induced cutaneous manifestation. *Hospital practice*. 2016;44(2):103-7.
7. Schindewolf M, Lindhoff-Last E, Ludwig RJ, Boehncke WH. Heparin-induced skin lesions. *Lancet*. 2012;380(9856):1867-79.
8. Jabira S, Mitwally H, Saad M, Karic E, Gazwi K, Elzeer H, Elshafei M. Unfractionated heparin as a safe alternative in a case of low molecular weight heparin-induced thrombocytosis: A case report. *Ann Med Surg (Lond)*. 2021 Apr 30;65:102370. doi: 10.1016/j.amsu.2021.102370.
9. Patriarreas V, Pikoulas A, Kostis M, Charpidou A, Dimakakos E. Heparin-induced Thrombocytopenia: Pathophysiology, Diagnosis and Management. *Cureus*. 2020 ;12(3):e7385. doi: 10.7759/cureus.7385.

Formatted: English (United States)

10. Tardy B, Lecompte T, Mullier F, Vayne C, Pouplard C. Detection of Platelet-Activating Antibodies Associated with Heparin-Induced Thrombocytopenia. *Journal of Clinical Medicine*. 2020; 9(4):1226. <https://doi.org/10.3390/jcm9041226>
11. Cuker A, Arepally GM, Chong BH, et al. American Society of Hematology 2018 guidelines for management of venous thromboembolism: heparin-induced thrombocytopenia. *Blood Adv*. 2018;2(22):3360-3392. doi:10.1182/bloodadvances.2018024489
12. Van der Linden, T., Souweine, B., Dupic, L. et al. Management of thrombocytopenia in the ICU (pregnancy excluded). *Ann. Intensive Care* 2, 42 (2012). <https://doi.org/10.1186/2110-5820-2-42>
13. Cines DB, Bussel JB. SARS-CoV-2 Vaccine-Induced Immune Thrombotic Thrombocytopenia. *N Engl J Med*. 2021 Jun 10;384(23):2254-2256. doi: 10.1056/NEJMe2106315. Epub 2021 Apr 16. Erratum in: *N Engl J Med*. 2021 Jun 10;384(23):e92. PMID: 33861524; PMCID: PMC8063912.
14. Lovatt CA, WQW Ye, Yousuf H. Probable fondaparinux-associated bullous hemorrhagic dermatosis. *CMAJ*. 2021; 193 (22): E801-E804.](metajour.nl/34059496)
15. Russo, A., Curtis, S., Balbuena-Merle, R. et al. Bullous hemorrhagic dermatosis is an under-recognized side effect of full dose low-molecular weight heparin: a case report and review of the literature. *Exp Hematol Oncol* 7, 15 (2018). <https://doi.org/10.1186/s40164-018-0108-7>
16. Kushner CJ, Payne AS. Increasing the Complement of Therapeutic Options in Bullous Pemphigoid. *The Journal of Investigative Dermatology*. 2018;138(2):246-248. DOI: 10.1016/j.jid.2017.09.026. PMID: 29389324.
17. Chiorean RM, Baican A, Mustafa MB, et al. Complement-Activating Capacity of Autoantibodies Correlates With Disease Activity in Bullous Pemphigoid Patients. *Front Immunol*. 2018;9:2687. doi:10.3389/fimmu.2018.02687
18. Hoffmann JHO, Enk AH. High-Dose Intravenous Immunoglobulin in Skin Autoimmune Disease. *Front Immunol*. 2019 Jun 11;10:1090. doi: 10.3389/fimmu.2019.01090. PMID: 31244821; PMCID: PMC6579842.

Formatted: English (United States)

Formatted: English (United States)

Formatted: English (United States)

Formatted: English (United States)

UNDER PENDING