

Original Research Article

ASPARTAME ADMINISTRATION CUM *MORINGA OLEIFERA* SEED EXTRACT: BLOOD GLUCOSE INDICES AND RENAL TOXICITY PERSPECTIVES

ABSTRACT:

Haematological parameters have been implicated in health indices. Aspartame is associated with elevated blood glucose level and toxicity in some body organs by alteration of their tissue histology. This study investigated the ameliorative potential of *Moringa oleifera* seed extract on adult male albino Wistar rats following aspartame consumption. The rats were separated into nine groups and left to acclimatize for two weeks. The experiment lasted for 28 days during which various administration and measurements were carried out. On the 29th day the rats were anaesthetized; the blood and the kidney harvested for blood glucose analysis and routine histological procedures, respectively. Raw data obtained were expressed as mean \pm standard error of mean ($M \pm SEM$) and subjected to one way analysis of variance (ANOVA) using primer software (version 3.01) and post-hoc analysis using the Newman-Kuel test. $P < 0.05$ was regarded as being significant. It is observed that administration of ethanolic extract of *Moringa oleifera* seed immediately after aspartame consumption, adequately checkmated rise in blood glucose level and maintain it at the optimum level along the normal reference range. Weight gain is observed within groups and across the groups of rats, suggesting that aspartame plays no useful role in weight loss. N-hexane extract of *Moringa oleifera* seed has the capacity to curtail the destruction of tissue architecture induced by aspartame, unlike ethanolic extract of *Moringa oleifera* seed. Hence, this study provides new insight on being cautious in consuming aspartame.

Key words : Adult male albino Wistar rats. Aspartame. Blood. Ethanolic extract of *Moringa oleifera* seed. Kidney. N-Hexane extract of *Moringa oleifera* seed.

Comment [AF1]: Review keywords.

1.1. INTRODUCTION

The kidney: is a bean shaped organ with a convex lateral margin and a concave medial side which houses the hilum, from which the renal artery enters and the renal vein and pelvis exits the kidney. The hilum leads into a space called the renal sinus. The renal sinus is occupied by the upper expanded part of the ureter that is mis-called the renal pelvis. The hilum serves as a passage for the ureter to exit, and blood and lymph vessels enters and exits. Inside the hilum, the upper end of the ureter extends as the renal pelvis and divides into two or three major calyces. The kidney has three major regions: the renal cortex, renal medulla and renal pelvis. The smaller branches, the minor calyces come from each major calyx. The kidney has an outer cortex, a dark region with many corpuscles and cross section of tubules and an inner cortex, a lightly stained region. The part of the cortex shows light and dark striations. The light lines are called medullary

Comment [AF2]: I suggest not breaking the introduction into topics.

Comment [AF3]: Reduce information on renal anatomy and physiology and include information on possible causes of renal toxicity.

rays (Singh, 2016). Each kidney contains about 1 million functional units called the nephron that consists of simple, single layered epithelium along their entire length. The kidney has some major divisions as follows: Renal corpuscle, an initial dilated part enclosing a tuft of capillary loops and the sight at which filtration of blood takes place. Nephron, is the basic structural and functional unit of the kidney that regulates water and soluble substances in the blood. Glomerulus, a capillary tuft that receives its blood supply from an afferent arteriole of the renal circulation, where fluid and solutes are filtered out of the blood and into the bowman's space. The bowman's capsules also called the glomerular capsule surround the glomerulus. It is composed of visceral and parietal (simple squamous epithelial) cells. Proximal convoluted tubules, is the first site of water reabsorption into the blood stream. Loop of Henle, a U shaped tube that consists of descending and ascending limbs. It transfers fluid from the proximal to the distal tubule. Distal convoluted tubules and collecting ducts, is the final site for reabsorption in the nephron. It is permeable to water and ion (Singh, 2012).

Moringa oleifera: is one of the world's most useful trees, with almost every part of the tree used for food, medications and industrial purposes (Khalafalla *et al.*, 2010). *Moringa oleifera* pod is reported to contain large amount of potassium, vitamins A and C (Fuglie, 1999; Jed and Fahey, 2005). This is the reason the leaf consumption is recommended for infants and nursing mothers, especially those in developing countries or areas prone to cases of malnutrition. *Moringa oleifera* is also utilized to increase lactating mother's milk production (Estrella *et al.*, 2000; Anwar *et al.*, 2007; Siddhuraji and Becker, 2003). The leaves are the most nutritious parts of the plant being a significant source of Vitamin B, K and C, pro Vitamin A as beta-carotene, manganese and protein among other essential nutrients (Leone *et al.*, 2015).

Aspartame: is a popular dietetic sweetener, which may provoke headache in some susceptible individuals. Aspartame breaks down in part into phenylalanine, which interferes with the action of an enzyme intestinal alkaline phosphatase (IAP) previously shown to prevent metabolic syndrome (a group of symptoms associated with type 2 diabetes and cardiovascular disease) (Gul *et al.*, 2017). People who regularly consume artificial sweeteners are at increased risk of "excessive weight gain, metabolic syndrome, type 2 diabetes, and cardiovascular disease," (Swithers, 2013). Several studies link aspartame to weight gain, increased appetite, diabetes, metabolic derangement and obesity-related diseases. This notion implicating aspartame to weight gain and obesity-related diseases raises some doubt as regards the legality of marketing aspartame-containing products as "diet" or weight loss aids. The aim of the study is to investigate and further determine the effect of *Moringa oleifera* seed extract on aspartame-induced renal toxicity. The specific objectives are: To determine the effect of ethanolic and n-Hexane extracts of *Moringa oleifera* seed on the body weight of adult male albino Wistar rats following aspartame administration. To verify the blood glucose levels of adult male albino Wistar rats following administration of aspartame, ethanolic extract and n-Hexane extract of *Moringa oleifera* seed.

Comment [AF4]: Include potential therapeutic actions of this product and reduce too much information.

1.2. METHODOLOGY

Experimental Animal Handling: Twenty seven adult male albino Wistar rats weighing between 150-215g were used. The animals were weighed, labeled and kept in wooden cages and allowed to acclimatized under optimum environmental conditions of temperature for 2 weeks prior to the commencement of the research work. They were fed pelletized growers and water adlibitum. The ethics of animal care was fully adopted following the guidelines for the care and use of laboratory animals.

Preparation of *Moringa oleifera* seed extract: Fresh *Moringa oleifera* pods were harvested from the *Moringa oleifera* tree in the botanical garden. The pods were carefully opened and the seeds collected and powdered using mortar and pestol. The sample was put into the thimble section and both end covered with a cotton wool. A condenser is fixed above with a water inlet and outlet and solvent in the distillation flask below. The flask is kept on a heating mantle and the solvent is heated under reflux. Solute are transferred from the extraction chamber into the reservoir. There was continuous repetition of the process till ethanolic extraction is completed, and the solid residue is subjected further to n-Hexane extraction.

Termination of experiment and tissue processing: The rats were anaesthetized with chloroform and dissected from the superficial layer of the abdomen and directed craniomedially to the thorax. The blood was gotten directly from the heart and preserved in an anti coagulant bottle, 10% buffered formalin was transcidentally perfused to preserve the tissues. The kidney was carefully harvested and fixed in 10% buffer formalin for 48 hour, to maintain the tissues morphology as faithfully as possible compared to the living state. The tissue processing involved the following stages: dehydration, clearing, infiltration, embedding, sectioning, and staining. Haematoxylin and Eosin staining method for routine histological studies were employed.

Statistical analysis: One way analysis of variance (ANOVA) using primer software (version 3.01); post-hoc analysis using the Newman-Kuel test was applied to test the significant levels. Data with probability $p < 0.05$ were regarded as significant.

Ethical approval was given and there was no conflict of interest among the authors.

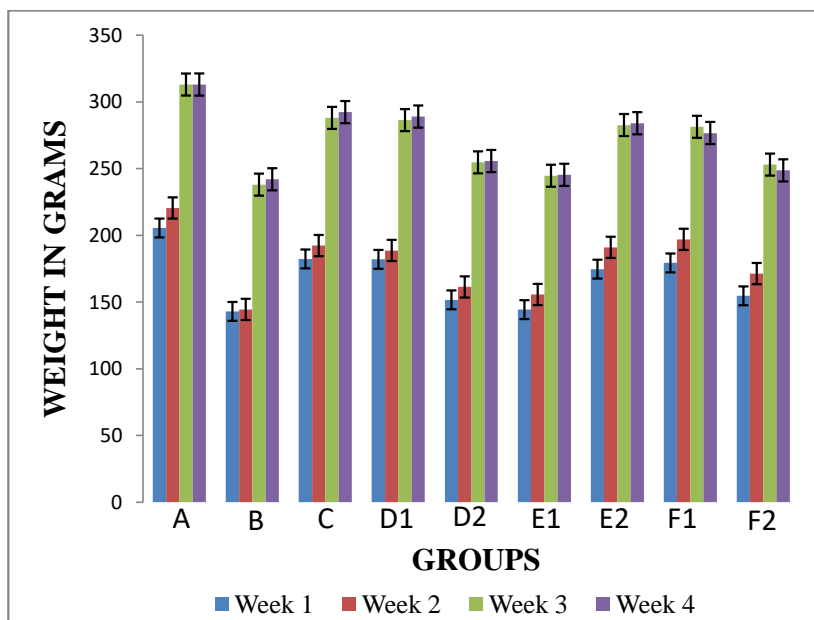
Comment [AF5]: Include data from substance administration protocols (sweet, time, etc.) to which the nine groups of animals were submitted.

Comment [AF6]: Include univariate analysis data.

Comment [AF7]: More details.

1.3. RESULTS

1.3.1. Comparison of Changes in Body Weight of Adult Male Albino Wister Rats.



Graph 1. Comparison of changes in body weight of albino rats. (data are expressed in mean and standard error of mean, $M \pm SEM$)

Key:

A = rats given distilled water Group A (Control).

B = rats given 0.4 ml (low dose) aspartame for 4 weeks (28 days)

C = rats given 1.5 ml (high dose) aspartame for 4 weeks (28 days)

D1 = rats given 0.6 ml (low dose) aspartame for the first 3 weeks and on the fourth week, 1.5 ml (low dose) ethanolic seed extract of *Moringa Oleifera* only.

D2 = rats given 0.5 ml (low dose) aspartame for the first 3 weeks and on the fourth week, 1.3 ml (low dose) n-Hexane seed extract of *Moringa Oleifera* only.

E1 = rats given 1.30 ml (high dose) aspartame for the first 3 weeks and on the fourth week, 2.5 ml (high dose) ethanolic seed extract of *Moringa Oleifera* only.

E2 = rats given 1.5 ml (high dose) aspartame for the first 3 weeks and on the fourth week, 3.0 ml (high dose) n-Hexane seed extract of *Moringa Oleifera* only.

F1 = rats given 1.4 ml (high dose) aspartame followed by 2.8 ml (high dose) ethanolic seed extract *Moringa Oleifera* for four weeks.

F2 = rats given 1.3 ml (high dose) aspartame followed by 2.5 ml (high dose) n-Hexane seed extract *Moringa Oleifera* for four weeks.

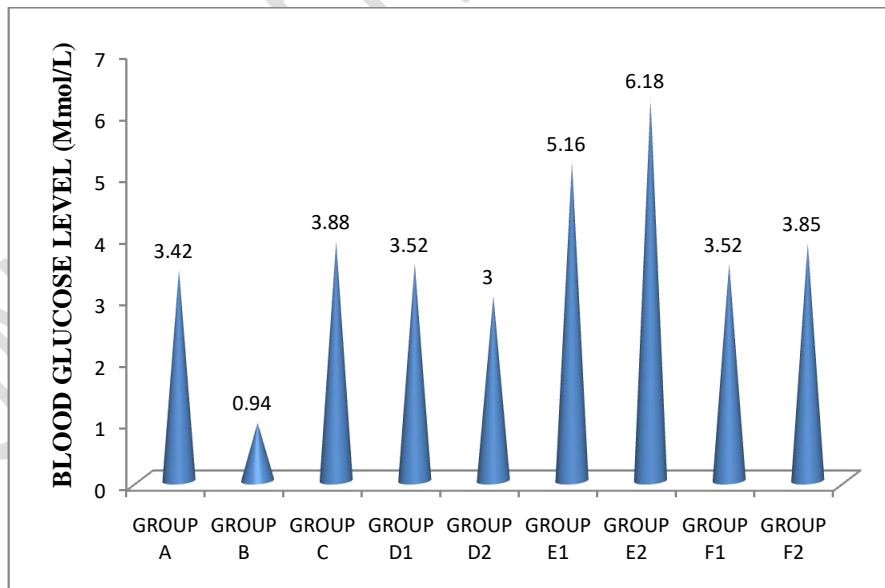
Comment [AF8]: The title of the Figure is not self explanatory. Include data of statistical significance in the graph. Put information about the method of data analysis.

1.3.2. Table 1. Blood Glucose Count for Adult Male Albino Wistar Rats Administered Aspartame.

GROUP	M±SEM (Mmol/l)	SD
A	3.42±0.28	0.48
B	0.94±0.01	0.02
C	3.88±0.48	0.83
D1	3.52±1.16	2.01
D2	3.00±2.51	4.35
E1	5.16±0.53	0.92
E2	6.18±2.11	3.65
F1	3.52±0.89	1.54
F2	3.85±0.56	0.97

$F = 1.45$ $P = 0.243$ $P < 0.5$

Values are expressed as mean ± standard error of mean (S±SEM); and as standard deviation (SD)



1.3.3. Graph 2. Blood Glucose Count for Adult Male Albino Wistar Rats Administered Aspartame.

Comment [AF9]: Information regarding the protocols that are mentioned in the Figure above must be included in the footnote of the table. The p value must be written in lowercase. The p-value data is confusingly described. Put information about the method of data analysis.

Comment [AF10]: Information regarding the protocols that are mentioned in Figure 1 should be included in Figure 2. Describe information regarding statistical significance. Put information about the method of data analysis.

When it comes to blood glucose measurement, the standard and criteria used for rats are slightly comparable and close to that used for human. The normal range of fasting sample is 3.0 to 5.5 mmol/l. Figures below 3.0 mmol/l predisposes to hypoglycemia. Figures above 7.0 mmol/l indicate hyperglycemia, while figures above 10.0 mmol/l point to diabetic condition. Based on data above, Control group A, has blood glucose level within the normal reference range. Experimental group B, is an exception in that it points to hypoglycemic state following low dose aspartame administration. In experimental group C, high dose of aspartame administration brought about a slight increase in blood glucose level compared to the control, however, the stated value is still within the normal reference range. In group D1, though there was a slight increase above the control, but still below the value obtained following administration of low dose of aspartame; thus, suggesting that ethanolic extract of *Moringa oleifera* seed may play a role in lowering blood glucose level, when the aspartame is administered in low doses. In D2, there was a notable decrease in the blood glucose level, also suggesting that n-Hexane extract of *Moringa oleifera* seed may play a greater role than the ethanolic extract of *Moringa oleifera* seed in lowering blood glucose level, when the aspartame is administered in low doses. In E1, the value obtained suggested that ethanolic extract of *Moringa oleifera* seed, lack the capacity to checkmate the rise in the blood glucose level following aspartame administration in large doses; irrespective of the fact that it maintained it within the normal reference range. The same is applicable to E2, in which n-hexane extract of *Moringa oleifera* seed is administered. However, the n-Hexane extract of *Moringa oleifera* seed is behind the ethanolic extract of *Moringa oleifera* seed in efficacy. In F1, It is observed that administration of ethanolic extract of *Moringa oleifera* seed immediately after aspartame consumption, adequately checkmated rise in blood glucose level and maintain it at the optimum level along the normal reference range. In F2, it also observed that administration of n-Hexane extract of *Moringa oleifera* seed, following aspartame consumption equally checkmated rise in blood glucose level but not as effectively done by the ethanolic extract of *Moringa oleifera* seed.

Comment [AF11]: This information must be included in the methodology.

Comment [AF12]: When describing the results, put which Figure/Table the information is referring to.

Comment [AF13]: Statistical significance is not described here or in Figure. Summarize this information and include brief information from the others Figures and Table.

1.3.4. Hematoxylin and Eosin (H&E) Method for General Demonstration of kidney

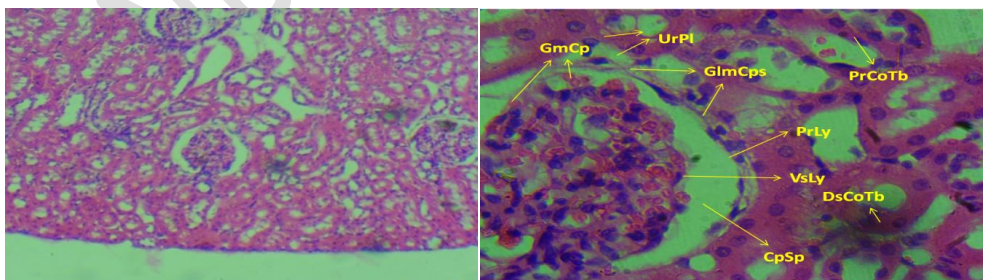


Figure I. (H&E method, X100).

Figure II. (H&E method, X400).

Cross section of the Kidney Cortex of adult male albino Wistar rat given distilled water. **Group A (Control). (H&E method, X400).** Section revealed features typical of normal kidney cortex:

Comment [AF14]: Describe as "Image" or just letters (A, B, C...) and not as "Figure".

Glomerular (Bowman's) capsule **GlmCps**. Glomerular capillary **GmCp**. Proximal Convoluted tubule **PrCoTb**. Parietal Layer **PrLy**. Visceral layer **VsLy**. Distal convoluted tubule **DsCoTb**. Capsular Space **CpSp**. Urinary pole **UrPI**.

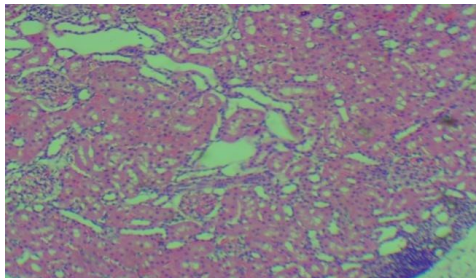


Figure III. (H&E method, X100).

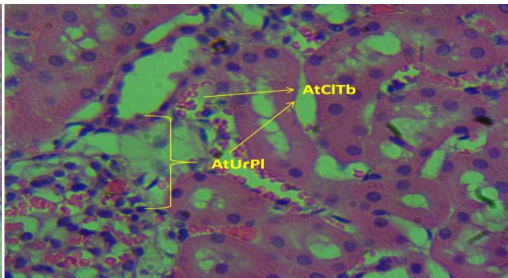


Figure IV. (H&E method, X400).

Cross section of the Kidney Cortex of adult male albino Wistar rat given 0.40 ml (low dose) aspartame for 4 weeks **Group B. (H&E method, X400)**. Section revealed: Atrophy of collecting tubule **AtCITb**. Atrophy of urinary pole **AtUrPI**. **Inference:** Severely affected.

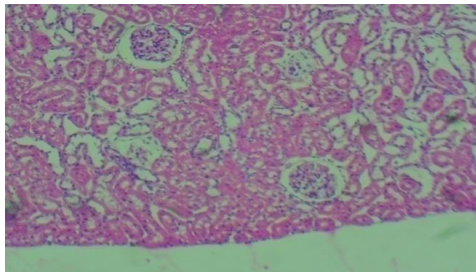


Figure V. (H&E method, X100).

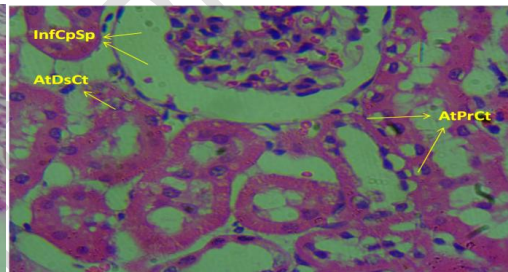


Figure VI. (H&E method, X400).

Cross section of the Kidney Cortex of adult male albino Wistar rat given 1.50 ml (high dose) aspartame for 4 weeks. **Group C. (H&E method, X400)**. Section revealed: Inflammation of capsular space **InfCpSp**. Atrophy of distal convoluted tubule **AtDsCt**. Atrophy of proximal convoluted tubule **AtPrCt**. **Inference:** Severely affected.

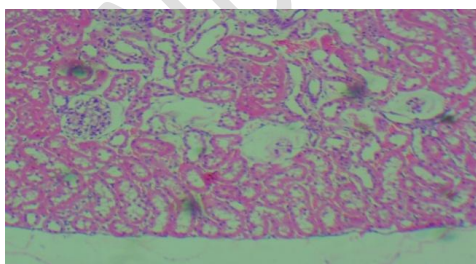


Figure VII. (H&E method, X100).

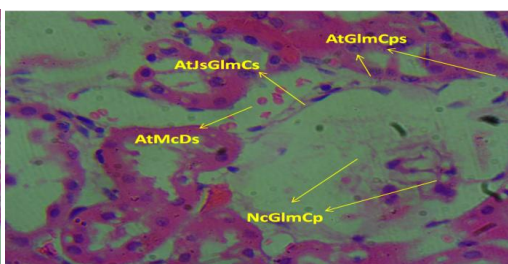


Figure VIII. (H&E method, X400).

Cross section of the Kidney Cortex of adult male albino Wistar rat given 0.60 ml (low dose) aspartame for the first 3 weeks and on the fourth week, 1.50 ml (low dose) ethanolic extract of *Moringa oleifera* seed only. **Group D1. (H&E method, X400)**. Section revealed: Atrophy of

Juxtaglomerular cells AtJsGlmCs. Atrophy of Macula densa **AtMcDs.** Atrophy of glomerular capsule **AtGlmCp.** Necrosis of glomerular capillaries **NcGlmCp.** **Inference:** Severely affected.

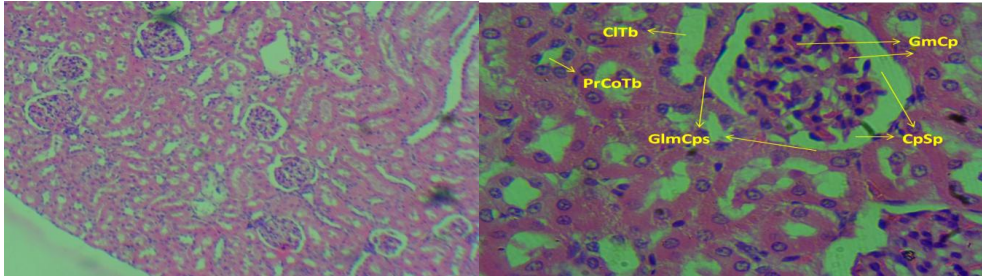


Figure IX. (H&E method, X100).

Figure X. (H&E method, X400).

Cross section of the Kidney Cortex of adult male albino Wistar rat given 0.50 ml (low dose) aspartame for the first 3 weeks and on the fourth week, 1.30 ml (low dose) N – Hexane extract of *Moringa oleifera* seed only. **Group D2. (H&E method, X400).** Section revealed intact: : Glomerular (Bowman's) capsule **GlmCps.** **Glomerular capillary GmCp.** Proximal Convoluted tubule **PrCoTb.** Capsular Space **CpSp.** Collecting tubule **CITb.** **Inference:** Unaffected.

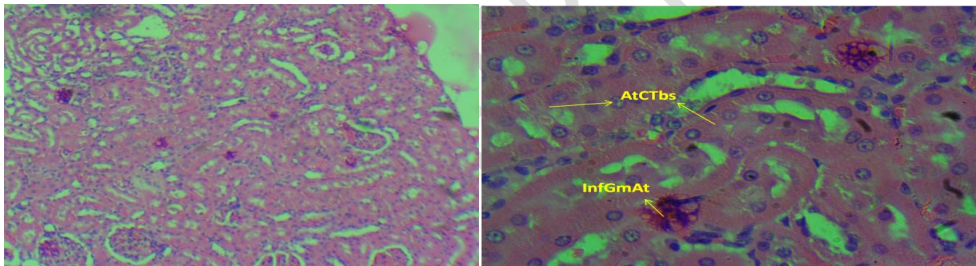


Figure XI. (H&E method, X100).

Figure XII. (H&E method, X400).

Cross section of the Kidney Cortex of adult male albino Wistar rat given 1.30ml (high dose) aspartame for the first 3 weeks and on the fourth week, 2.50 ml (high dose) ethanolic extract of *Moringa oleifera* seed only. **Group E1. (H&E method, X400).** Section revealed: Atrophy of both proximal and distal convoluted tubules **AtCoTb.** Inflammation of glomerular arterioles **InfGmAt.** **Inference:** Severely affected.

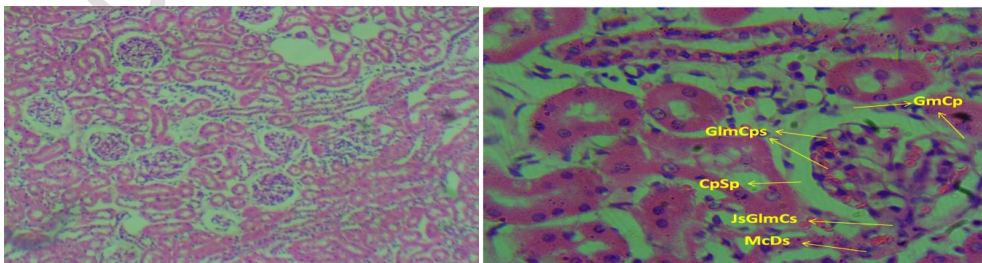
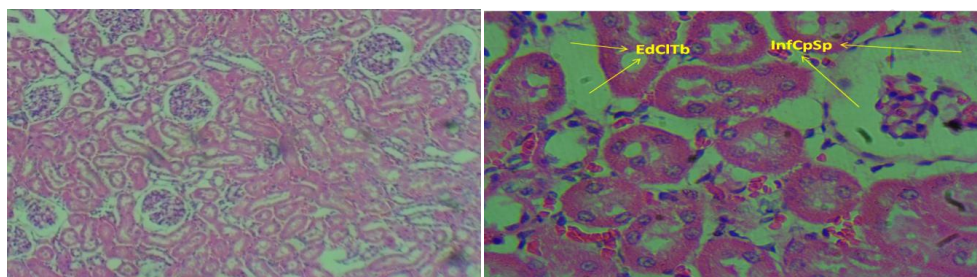
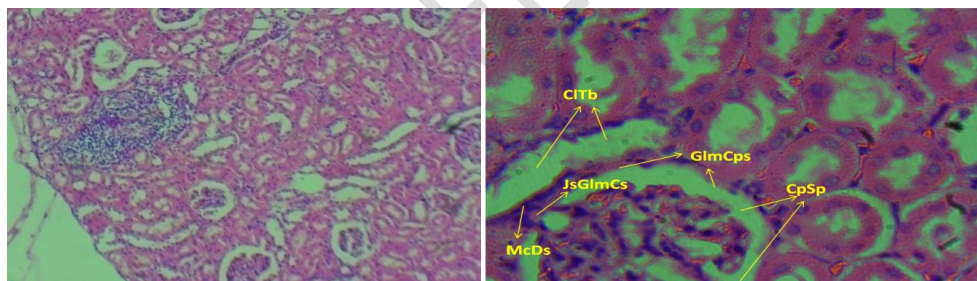


Figure XIII. (H&E method, X100).

Cross section of the Kidney Cortex of adult male albino Wistar rat given 1.50 ml (high dose) aspartame for the first 3 weeks and on the fourth week, 3.00 ml (high dose) N – Hexane extract of *Moringa oleifera* seed only. **Group E2. (H&E method, X400).** Section reveal intact: Glomerular (Bowman's) capsule **GlmCps**. Glomerular capillary **GmCp**. Capsular Space **CpSp**. Juxta - glomerular cells **JsGlmCs**. **Inference:** Unaffected.

Figure XIV. (H&E method, X400).**Figure XV. (H&E method, X100).**

Cross section of the Kidney Cortex of adult male albino Wistar rat given 1.40 ml (high Dose) aspartame followed by 2.80 ml (high dose) ethanolic extract of *Moringa oleifera* seed for four weeks. **Group F1. (H&E method, X400).** Section revealed: Edema of collecting tubul **EdCoTb**. Inflammation of Capsularspace **InfCpSp**. **Inference:** Slightly affected.

Figure XVI. (H&E method, X400).**Figure XVII. (H&E method, X100).**

Cross section of the Kidney Cortex of adult male albino Wistar rat given 1.30 ml (high Dose) aspartame followed by 2.50 ml (high dose) N – Hexane extract of *Moringa oleifera* seed for four weeks. **Group F2. (H&E method, X400).** Section reveal: Glomerular (Bowman's) capsule **GlmCps**. Glomerularcapillary **GmCp**. **Inference:** Unaffected.

Figure XVIII. (H&E method, X400).

1.4. DISCUSSION OF FINDINGS

There was observed increase in weight within and across groups of rats used for the research; these findings of ours are corroborated by the work of Daniel and colleagues, 2019; in which they stated that “even acceptable daily dose of aspartame, as regulated by the United States Food and Drug Administration (FDA), might make you hungrier and lead to weight gain”.

Comment [AF15]: I suggest reviewing the way the discussion is written. Start as a short paragraph with all the results found and then start the discussion of the most important results.

The average fasting blood glucose (FBG) of normal Wistar rats was (3.95 +/- 1.31) mmol/L, and the 95% upper limit was 6.2 mmol/L. (Johnson-Delaney, 1996; Wei Sheng, 2010). In our research, the control group A, has blood glucose level within the normal reference range, as stated above. Same figures were obtained from other experimental groups, namely: C, d1, E1, F1 and F2, with slight discrepancies based on the substance administered, with the exceptions of F2, that tilted toward hyperglycemic state and B toward hypoglycemic condition. Besides, Palmnäs *et al.*, 2014; in their work opined that “Aspartame consumption increased the fasting glucose concentrations in both the standard feed pellet diet and high-fat groups independent of body composition”. Their research result had given credence to the outcome of our own work in which there was gradual increase in blood glucose values across the groups as the experiment progressed; though none exceeded the normal reference range, except in group B, in which the mechanism underlying it is not well understood. The spike in glucose level seen in E2 being as a result of large doses of aspartame administered; and it also worthy to note that irrespective of the types of substances and feed administered, there was consistency in the rise in blood glucose level within and across groups

According to Isabela *et al.*, 2021; “via p53 activation, aspartame inhibited a transcriptional coactivator, the peroxisome proliferator-activated receptor gamma coactivator 1 alpha, a master regulator of glucose and lipid metabolism, probably leading to changes in lipid profile in serum, total lipid accumulation, as well as an impairment in the gluconeogenesis in mouse liver, thus causing hypoglycemia”. The outcome of the work of Isabela and colleagues might be the plausible and possible mechanism and explanation that underlies the hypoglycemic state observed in group B, in our own experiment.

All the stated facts above notwithstanding, the US Food and Drug Administration (FDA), has concluded that it is safe to use aspartame as a general purpose sweetener. The FDA went on to indicate that aspartame is yet to be conclusively implicated in any specific health problems; rare exceptions, being found only in people with phenylketonuria (PKU). Besides, the European Food Safety Authority (EFSA), has stated that people with conditions such as: brain tumours, leukemia, lymphatic and haematopoietic cancers as well as a variety of cancers, are not at increased risk following aspartame consumption.

There was an observed dose dependent alteration of histology of renal tissues and this has a link in cases where there were increases in blood glucose level, thus giving credence to the fact that of diagnostic significance in routine clinical evaluation as regards health condition is hematological parameters. In the experimental group E2, there was increased blood glucose level that predisposed to hyperglycemia; this in fact, introduced a gap in the evidence that hematologic parameters are of diagnostic significance in routine clinical evaluation; however, in same experimental group E2, the N-Hexane extract of *Moringa oleifera* seed, effectively checkmated the disruptive effect of aspartame on the kidney cells, thus, substantiating the suggestion by Mutasim, *et al.*, 2010, that *Moringa oleifera* may have potential for use as source of natural treatment for diseases such as cancer, hepatocarcinoma cells in vitro. Our research finding is further supported by the work of Julie and Gary, 2011; from which they concluded that the Consumption of ≥ 2 servings per day of artificially sweetened soda is associated with a 2-fold increased odds for kidney function decline in women. Moreover, Arbind, *et al.*, 2014, in their study concluded that over a long time duration, the administration of about 40 mg/kg. bw/day, of

aspartame orally may result to oxidative stress, caused by methanol, which itself is an aspartame metabolite and can be injurious to the liver and kidney.

Comment [AF16]: Include limitations and conclusions.

REFERENCES

- Anwar, F., Latif, S., Ashraf, M. and Gilani, A. H. (2007). *Moringa oleifera* a food plant with multiple medicinal value, *Phytotherapy Research*. 21:17-25.
- Arbind, K.C., Saravanan, S., Sheela, D. (2014). Aspartame Induce Modification in Membrane Bound and Antioxidant Enzymes in Liver and Kidney of Wistar Albino Rats. *Current Nutrition & Food Science*, 10(4). DOI:10.2174/1573401310666141024215431
- Daniel, S.C., and Aminah, J., (2019). A hunger for hunger: A review of palliative therapies for cancer-associated anorexia. *Ann Palliat Med*. 8(1): 50–58. doi: 10.21037/apm.2018.05.08
- Estrella, M.C.P., Mantaring, J.B.V. and David, G.Z. (2000). Adouble blind, randomized controlled trial on the use of mallunggay (*Moringa oleifera*) for augmentation of the volume of breast milk among non-nursing mothers of pretern infants. *Philippine journal of pediatric*. 49:306
- Gul, S.S., Hamilton, A.R., Munoz, A.R., Phupitakphol, T., Liu, W., Hyoju, S.K., Economopoulos, K.P., Morrison, S., Hu, D., Zhang, W., Gharedaghi, M.H., Huo, H., Hamarneh, S.R., Hodin, R.A.. (2017). “Inhibition of the gut enzyme intestinal alkaline phosphatase may explain how aspartame promotes glucose intolerance and obesity in mice.” *Appl Physiol Nutr Metab*.
- European Food Safety Authority (EFSA). www.efsa.europa.eu/en/topics/topic/aspartame
- Fuglie, L. J. (1999). The miracle tree: *Moringa oleifera*: natural nutrition for the tropics. Dakar. 68pp revised in 2001 and published as the miracle tree: the multiple attribute of *Moringa*. 172pp.
- Isabela, A.F., Caroline, A.B., Isabel T-C., Sergio, R-P., Marcelo, da Veiga, Maria I. Rocha, Maria, A., Pavanato, and Salvador P. (2021). *Biology*, 10(2), 82; <https://doi.org/10.3390/biology10020082>
- Jed, W. and Fahey, S.D. (2005). *Moringa oleifera* a Review of the medicinal evidence for its nutritional, therapeutic and prophylactic properties. Part 1- *Trees for life journal*.
- Johnson-Delaney, C., (1996). *Exotic Animal Companion Medicine Handbook for Veterinarians*, Zoological Education Network.

Julie, L., and Gary, C.C. (2011). Associations of sugar and artificially sweetened soda with albuminuria and kidney function decline in women. *Clin J Am Soc Nephrol*;6(1):160-6. doi: 10.2215/CJN.03260410. Epub 2010 Sep 30.

Khalafalla, M. M., Abdellatef, F.D., Nasarralah, A.A., Aboul-Enein, (2010). Light foot DA, El-El Deeb FE, El-Shemy, H. A. Active principle from *Moringa oleifera* lam leaves effective against two leukemas and a hepatocarcinoma. *African journal biotechnology* 9(49): 8467-8471.

Alessandro, L., Alberto, S., Alberto, B., Alberto, S., Junior, A., and Simona, B. (2015). Cultivation, Genetic, Ethnopharmacology, Phytochemistry and Pharmacology of *Moringa oleifera* Leaves: An Overview *Int. J. Mol. Sci.* 2015, 16(6), 12791-2835; <https://doi.org/10.3390/ijms160612791>

Mohammad Reza Ardalan, Hadi Tabibi, Vahideh Ebrahimzadeh-Attary, Aida Malek Mahdavi. (2017). Nephrotoxic Effect of Aspartame as an Artificial Sweetener: a Brief Review.

Iranian Journal of Kidney Diseases 11(5):339-343

Mutasim, M.K., Eltayb, A., Hussain, M.D., Amr, A.N., Khalid, M.A., David, A.L., Fadl, E.E., Deeb, H.A., and El-Shemy. (2010). Active principle from *Moringa oleifera* Lam leaves effective against two leukemias and a hepatocarcinoma. *African Journal of Biotechnology*. Volume9 Issue49P.8467-8471

Palrnäs, M.S., Cowan, T.E., Bomhof, M.R., Su, J., Reimer, R.A., Vogel, H.J., Hittel, D.S., Shearer, J.. (2014). Low-dose aspartame consumption differentially affects gut microbiota-host metabolic interactions in the diet-induced obese rat. *PLoS One*;9:e109841.

Siddhuraji and Becker, 2003

Singh, G.P., and Sharma, S.K. (2012). Antimicrobial evaluation of leaf Extract of *Moringa oleifera* Lam. *International Research Journal of Pharmacology*, 3, 1-4.

US Food and Drug Administration (FDA).

www.fda.gov/food/ingredientspackaginglabeling/foodadditivesingredients/ucm397725.htm

Wei Sheng Yan Jiu. 2010 Mar;39(2):133-7, 142.