

## **Case study**

### **Three-way complex variant translocation involving long arm of chromosome 1 in a chronic myeloid leukemia patient**

#### **Abstract:**

Clinical presentation of chronic myeloid leukemia (CML) with classic translocation is similar to those with variant **translocations**. However, the disease course, outcome and prognosis differs to a large extent. Therefore, it is important to identify and report variant cytogenetic findings. The case is being reported to improve awareness regarding such cases.

**Comment [U1]:** translocations

#### **Case Presentation:**

Herein we present a case study of 55-year-old male who presented with abdominal pain and fever. The initial complete blood count showed hyperleukocytosis with features suggestive of chronic myeloproliferative leukemia (CML). Bone marrow biopsy and cytogenetic studies were performed for confirmation. Cytogenetic analysis showed presence of complex, three-way (1;9;22)(q12;q34;q11) translocation involving chromosomes 1, 9 and 22. The Fluorescence **in situ** hybridization (FISH) studies further confirmed BCR-ABL fusion gene and its atypical pattern was in concordance with aberrations observed in karyotype. The variant translocation we reported herein is unique and rarely reported in literature.

**Comment [U2]:** *in situ*

**Comment [U3]:** The word *in situ* should always be written in italics: *in situ*. It is suggested to use italics

#### **Discussion:**

We presented a complex variant case of three-way translocation with characteristic hematological and immunophenotypic findings of CML in chronic phase. To the best of our knowledge, only few cases have been documented so far involving such complex translocation. The initial response to cytoreduction was encouraging while imatinib response has to be followed in present case.

#### **Conclusion:**

It is important to highlight the variant translocations since such findings may influence the disease course hence play a significant role to predict outcome.

**Key Words:** Three-way variant translocation, CML, FISH, Cytogenetics

### **Introduction:**

Chronic myeloid leukemia (CML) is a neoplasm of hematopoietic stem cells. It is characterized by the presence of Philadelphia (Ph) chromosome resulting from the reciprocal translocation between chromosome 9 and 22 [1]. Presence of Philadelphia chromosome is a hallmark of CML and its correlation with FISH signal patterns is crucial to identify variant translocations or additional chromosome aberrations. This translocation event triggers the formation of BCR-ABL1 fusion gene [2]. The resultant proteins possess a constitutive tyrosine kinase activity, thus playing a pivotal role in phosphorylation. Thereby, it affects multitude of the intracellular signaling events regulating the cell processes for instance NF-Kb, Jak-Stat, Ras, PI3K/AKT, consequently malignant transformation [3]. Besides classical CML translocation i.e. t(9;22)(q34;q11), variant translocation involving other chromosomes have been reported in 5-10% of the CML patients [4]. These variant translocations have a significant impact on outcome and are known to be associated with adverse prognosis.

### **Case Presentation:**

A 55 years' male presented with complaints of abdominal pain, facial and pedal swelling associated with fever for last two months. There is also history of undocumented weight loss (>15 kg) in last 3-4 months. On examination, he has cervical lymphadenopathy and splenomegaly. Ultrasound abdomen showed enlarged spleen. Initial CBC revealed Hb: 5.8gm/dl, TLC:  $158 \times 10^9/L$  and platelet:  $168 \times 10^9/L$ . Blood film showed hyperleukocytosis, leukoerythroblastic blood picture, occasional blasts and absolute basophilia. Bone marrow biopsy is performed to ascertain the phase of disease. Spicular and cellular bone marrow aspirate exhibit trilineage hematopoiesis along with myeloid hyperplasia. Immunohistochemistry performed on bone marrow biopsy showed sprinkling positivity for CD34 and CD117 thus excluding any foci of blasts. Reticulin stain showed grade I fibrosis. Hence the case was concluded as CML in chronic phase. At the same time, patient's sample was received for

cytogenetic workup including conventional karyotyping and fluorescence *in situ* hybridization (FISH).

**Comment [U4]:** The word *in situ* should always be written in italics: *in situ*. It is suggested to use italics

For Conventional cytogenetic analysis bone marrow culture (24 hours) was setup. After unstimulated culturing metaphase was arrested by colcemid, then treated with hypotonic solution and followed by fixation using preformed fixative (Methanol:Glacial acetic acid). After fixation slides were made and GTG banding was performed. By using Cytovision software for analysis, total 20 GTG banded metaphase cells were analyzed. The karyotype revealed an abnormal male chromosome complement with a complex, three-way (1;9;22) between long arms of chromosomes 1, 9 and 22 resulting in Ph chromosome in all cells. [Figure 1] FISH dual color dual fusion probe was used to detect the presence of BCR-ABL fusion in 200 interphase nuclei cells. FISH revealed that 98% of the cells analyzed were positive for the BCR-ABL fusion however the pattern was atypical i.e. showing single fusion instead of dual fusion which was concordant with the findings identified in karyotype. [Figure 2]

**Comment [U5]:** Remove the point, and place it after [Figure 1].

**Comment [U6]:** Remove the point, and place it after [Figure 2].

#### Discussion:

A positive balanced translocation for Philadelphia (Ph) chromosome is well established in majority i.e. ~95% of the CML patients. Nevertheless, complex and variant translocations have been shown by a small fraction 5–8% of all CML patients, due to the involvement of one or more chromosome, along with 9 and 22. The most common underlying molecular event in classical variant translocations is the production of the BCR-ABL fusion gene possessing kinase activity. BCR-ABL leads to auto-phosphorylation and uncontrolled signaling to oncoproteins resulting in myeloid proliferation [2, 5].

The pathogenesis underlying the complex karyotypic translocations is poorly understood however, the random aberrations in general are thought to result from the genome instability. In particular, two sustainable mechanisms are proposed by Mkrтчyan and coworkers; the single event rearrangement resulting from the instantaneous breaks in chromosome followed by mismatched joining, or it may involve multiple translocation events following a multi-step mechanism involving more chromosomes in addition to standard 9 and 22 chromosomes [6, 7].

**Comment [U7]:** Mkrтчyan et al. (years?). It's a date (cita).

**Comment [U8]:** If we put Mkrтчyan et al. (years) there is no need to put the number [6]. Then if it is placed in the bibliography.

Three-way Ph chromosome variant in CML has been described in past, derived from the participation of a third chromosome with the classical translocation. A large study pertaining to

additional cytogenetic aberrations in CML revealed three way translocations at the time of diagnosis. Of the 1151 patients studied by Fabarius and coworkers, variant translocation t(v;22) was identified in 69 (6.0%) cases, where 60 (87.0%) of the patients harbored three-way variant translocation i.e. the involvement of one additional chromosome [8]. In particular, ~14 variant translocations involving chromosome 4 [t(4;9;22)] have been reported so far with 4p16 and 4q25 being the major breakpoints. Tori and colleague recently reported unique three-way variant t(4;9;22)(q21;q34;q11.2). According to published literature, these complex variants along with additional cytogenetic aberrations have negative impact on clinical outcome of CML patients [9].

Similarly, translocation involving chromosome 3 has also been reported in some cases. Li and colleagues reported three-way translocation t(3;9;22)(p21;q34;q11) in a 42-year-old male. They suggested identified translocation to be associated with poor prognosis in CML patients if treated with imatinib [10]. Involvement of chromosomes 7 and 17 is also documented in literature in cases of three way translocations [11, 12].

Herein, we presented a complex variant case of Ph chromosome 46,XX,t(1;9;22)(q12;q34;q11.2) with characteristic hematological and immunophenotypic findings of CML in chronic phase. To the best of our knowledge, only few cases have been documented so far involving such complex translocation. In past an unusual translocation involving chromosomes 1, 9, and 22 with the breakpoints at bands 1p22, 9q34, and 22q11, respectively has been reported by Adhvaryu and coworkers [13]. Further, a balanced three-way translocation t(1;9;22)(q25;q34;q11.2) associated with poor prognosis has also been documented elsewhere [14]. Similar three-way translocation though with different breakpoints, (1;9;22)(p36;q34;q11) has been reported in a 24-year-old female in the chronic phase of CML. Whereas, when monitored suboptimal response indicative of poor prognosis towards imatinib mesylate (BCR-ABL) protein tyrosine kinase inhibitor) was observed. Whereas, in present case it is too early to comment on outcome as the initial response to cytoreduction was encouraging while imatinib response has to be followed.

### Conclusion:

In conclusion, it is important to highlight the variant translocations as these findings may influence the disease course. Moreover, early identification of additional cytogenetic aberrations

**Comment [U9]:** Fabarius et al. (years?). It's a date (cita).

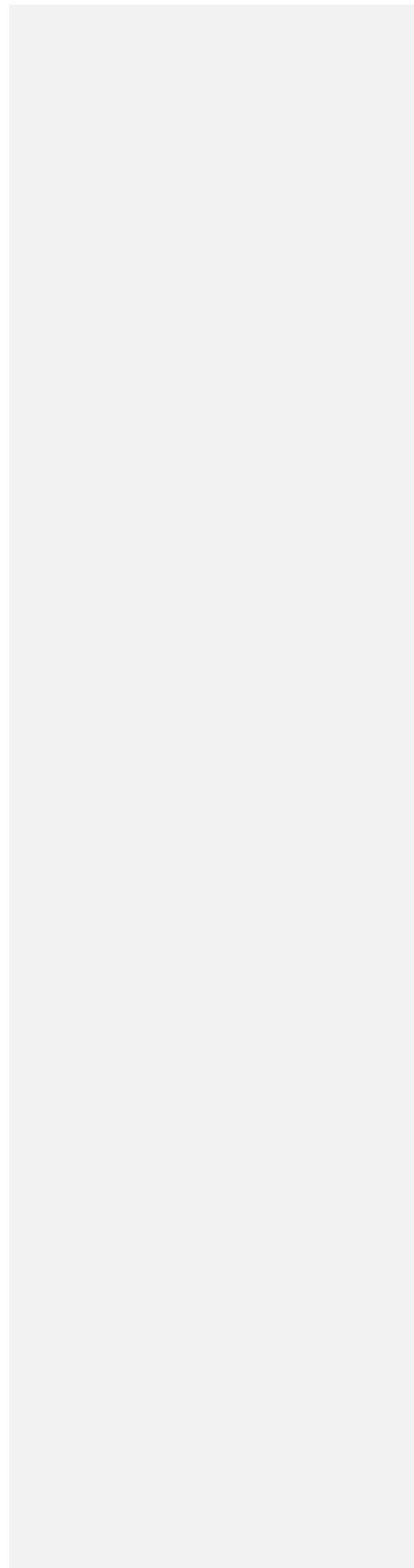
**Comment [U10]:** If we put Fabarius et al. (years) there is no need to put the number [8]. Then if it is placed in the bibliography.

**Comment [U11]:** Adhvaryu et al. (years?). It's a date (cita).

**Comment [U12]:** If we put Adhvaryu et al. (years) there is no need to put the number [13]. Then if it is placed in the bibliography.

are decisive in terms of management and consequently play a significant role in prediction of prognosis.

UNDER PEER REVIEW



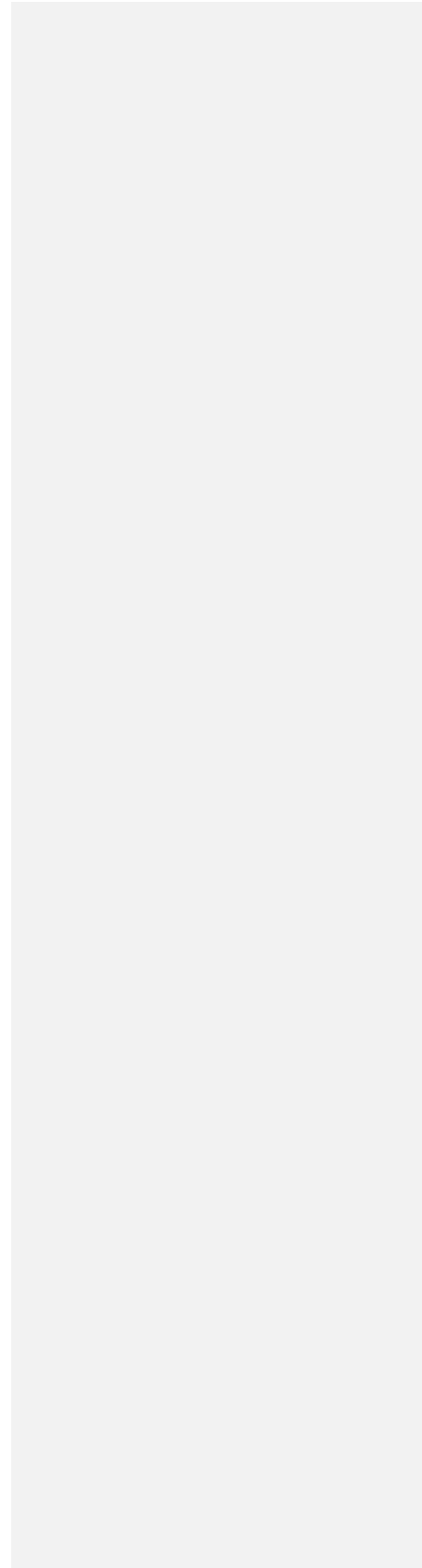
**Consent:**

Not applicable

**Ethical Approval:**

As per our institute's ethics committee, approval is not required for a case report.

UNDER PEER REVIEW



## References

1. Millot F, Dupraz C, Guilhot J, Suttorp M, Brizard F, Leblanc T, et al. Additional cytogenetic abnormalities and variant t (9; 22) at the diagnosis of childhood chronic myeloid leukemia: The experience of the International Registry for Chronic Myeloid Leukemia in Children and Adolescents. *Cancer*. 2017;123(18):3609-3616. doi.org/10.1007/s00277-016-2892-7.
2. Mishra S, Lee Y, Park JW. Direct quantification of trace amounts of a chronic myeloid leukemia biomarker using locked nucleic acid capture probes. *Anal Chem*. 2018;90(21):12824-31. doi.org/10.1021/acs.analchem.8b03350.
3. Karlíková R, Šíroková J, Friedecký D, Faber E, Hrdá M, Mičová K, et al. Metabolite profiling of the plasma and leukocytes of chronic myeloid leukemia patients. *J Proteome Res*. 2016;15(9):3158-66. doi.org/10.1021/acs.jproteome.6b00356.
4. Gong Z, Zheng L, Tang Z, Chen Z, Wang W, Bai S, et al. Role of complexity of variant Philadelphia chromosome in chronic myeloid leukemia in the era of tyrosine kinase inhibitor therapy. *Ann Hematol*. 2017;96(3):501-4. doi.org/10.1002/cncl.30767.
5. Asif, M., Hussain, A., Malik, A., & Rasool, M. (2015). Three-way complex variant translocation involving short arm chromosome (1; 9; 22)(p36; q34; q11) in a chronic myeloid leukemia patient. *Oncol Let*. 10(3), 1728-1730.
6. Mkrtchyan H, Ghazaryan S, Avetisyan G, Hovhannisyan A, Muradyan L, Daghbashyan S, et al. Novel complex t (V; 9; 22) rearrangements in three cases with chronic myeloid leukemia and a rare translocation in a case with classical Philadelphia chromosome. *Oncol Rep*. 2008;20(1):99-104. doi.org/10.3892/or.20.1.99.
7. Asif M, Jamal MS, Khan AR, Naseer MI, Hussain A, Choudhry H, et al. A novel four-way complex variant translocation involving chromosome 46, XY, t (4; 9; 19; 22)(q25: q34; p13. 3; q11. 2) in a chronic myeloid leukemia patient. *Front Oncol* 2016;30;6:124. doi.org/10.3389/fonc.2016.00124.
8. Fabarius A, Leitner A, Hochhaus A, Müller MC, Hanfstein B, Haferlach C, et al. Impact of additional cytogenetic aberrations at diagnosis on prognosis of CML: long-term observation of 1151 patients from the randomized CML Study IV. *Blood*. 118(26):6760-6768. doi.org/10.1182/blood-2011-08-373902.

9. Torii Y, Nanjo K, Toubai T, Hosokawa M, Sato R, Yamada A, et al. A unique three-way Philadelphia chromosome variant t (4; 9; 22)(q21; q34; q11. 2) in a newly diagnosed patient with chronic phase chronic myeloid leukemia: a case report and review of the literature. *J Med Case Rep.* 2021;15(1):1-6. doi.org/10.1186/s13256-021-02885-4.
10. Li Q, Lin XJ, Chen H, Gong J, Li Z, Chen XN. Co-existence of isodicentric Ph chromosomes and the three-way Ph chromosome variant t (3; 9; 22)(p21; q34; q11) in a rare case of chronic myeloid leukemia. *Oncol Lett.* 2018;15(4):4599-603. doi.org/10.3892/ol.2018.7866.
11. Tirro E, Massimino M, Stella S, Zammit V, Consoli ML, Pennisi MS, et al. Efficacy of nilotinib in a cml patient expressing the three-way complex variant translocation t (2;9;22). *Anticancer Res.* 2019;39(7):3893-9. doi.org/10.21873/anticancer.13540.
12. Asif M, Hussain A, Wali A, Ahmad N, Sajjad N, Amir M, et al. A rare case of three-way complex variant translocation in chronic myeloid leukemia t (6; 9; 22)(p21; q34; q11): a case report. *Biomed Rep.* 2017;7(4):377-9. doi.org/10.3892/br.2017.967.
13. Adhvaryu SG, Vyas RC, Jani KH, Balar DB. Complex translocation involving chromosomes# 1# 9, and# 22 in a patient with chronic myelogenous leukemia. *Cancer genet cytogenet.* 1988;32(2):277-80. doi.org/10.1016/0165-4608(88)90291-9.
14. Fan YS, Rizkalla K, Barr RM. A new complex variant Philadelphia chromosome, t (1; 9; 22) ins (17; 22), characterized by fluorescence in situ hybridization in an adult ALL. *Leukemia research.* 1999;23(11):1001-6. doi.org/10.1016/S0145-2126(99)00130-7.

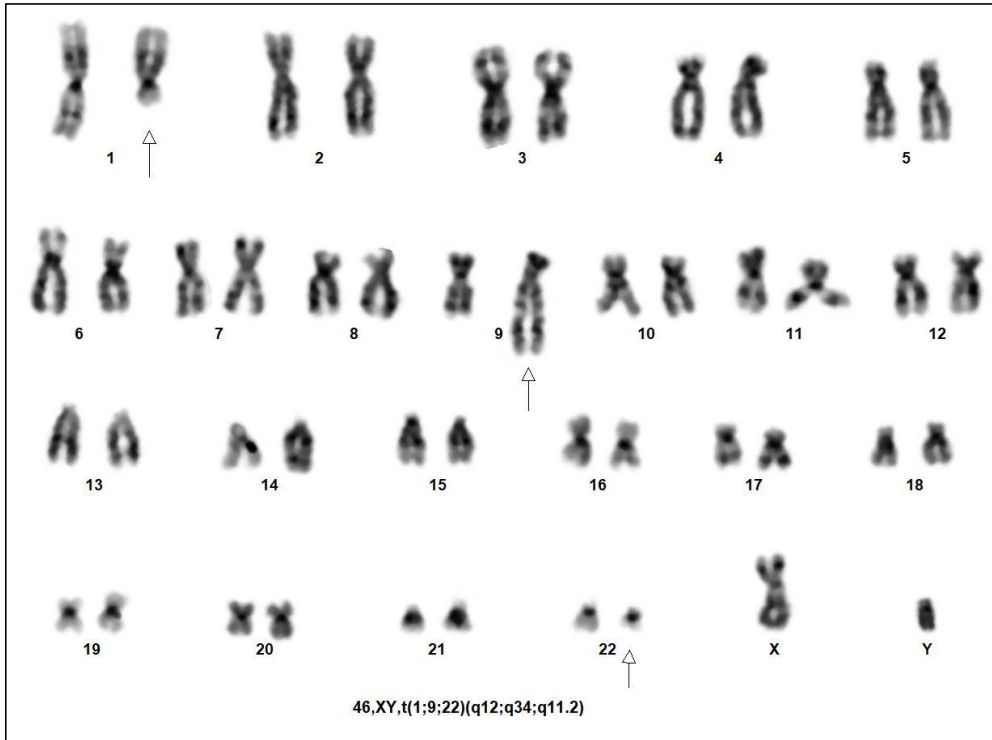


Figure 1: Cytogenetic analysis revealing a variant three-way translocation 46,XX,t(1;9;22)(p21;q34;q11). Arrowheads highlight the derivative chromosomes.

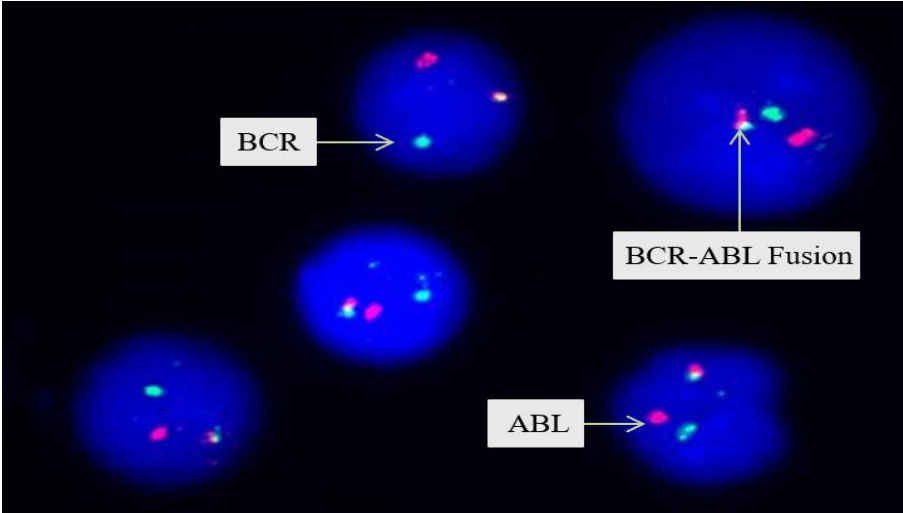


Figure 2: Dual color dual fusion probe depicting atypical pattern (1Green 1Red 1Fusion) of BCR-ABL1 fusion by interphase FISH (Green=BCR on chromosome 9, Red=ABL on chromosome 22)