

### **Diabetic Retinopathy: Causes, Investigations and Treatment**

#### **Abstract**

Background: Diabetic retinopathy and diabetic macular edema are caused by chronic damage to the neurovascular structure of the retina. The pathophysiology of retinal damage remains uncertain, but includes abnormalities in metabolism and neuroinflammation. These mechanisms are considered for deep metabolic regulation of systemic diseases and the use of ocular anti-inflammatory agents such as vascular endothelium inhibitors and corticosteroids. A better understanding of the underlying eye and systemic processes of diabetic retinopathy will improve the way we diagnose and treat retinopathy and maintain better vision.

Conclusion: Diabetic retinopathy progresses with the duration of the disease and often leads to an increase in retinopathy in early adolescent patients and macular edema in the elderly patient.

*Keywords: Diabetic retinopathy; Diabetes mellitus; Hypoglycemia; Vitrectomy; Proliferative diabetic retinopathy; Vitreous hemorrhage*

#### **Introduction**

Patients with diabetes often have eye problems, such as corneal abnormalities, glaucoma, iris neovascularization, cataracts, and neuropathy. However, the most common and likely cause of blindness from these problems is diabetic retinopathy, which is actually the leading cause of new blindness in people aged 25-74 in the United States. About 700,000 people in the United States have reproductive diabetes retinopathy, with 65,000 cases annually. The prevalence of diabetic retinopathy in the United States has increased by 28.5% in people aged 40 years and over. Diabetes mellitus (DM) is a major health problem worldwide. Diabetes causes a series of long-term systemic problems that have a profound effect on the patient and the community, as the disease often affects people in their most productive years. Diabetes is on the rise worldwide. Moreover, this increase is noticeable in developing countries. These additional etiologies include dietary changes, high fat diets, lifestyle changes, and decreased physical activity. Key contributory features related to diabetic retinopathy include high glucose and hemoglobin A1c (HbA1c), fluorescein angiography, optical coherence tomography, and B-scan ultrasonography. Controlling diabetes and keeping HbA1c levels at 6-7% are the goals of proper management of diabetes and diabetic retinopathy. The exact cause of diabetic retinopathy is not yet clear, but several theories have been put forward to explain the general course and history of the disease (1).

#### **Causes and Risk Factors**

Duration of diabetes: Patients with type I diabetes cannot detect significant clinical retinopathy during the first 5 years after the initial diagnosis of diabetes. After 10-15 years, 25-50% of patients show signs of retinopathy. Usually this increases to 75-95% after 15 years and almost 100% after 30 years of diabetes. Proliferative diabetic retinopathy (PDR), which is rare in the first 10 years after diabetes diagnosis, increases to 14-17% in 15 years and then increases gradually. In patients with type II diabetes, the incidence of diabetic retinopathy increases with the duration of the disease. In patients with type II diabetes, 23% develop nonproliferative diabetic retinopathy (NPDR) after 11 to 13 years, 41% develop NPDR after 14 to 16 years, and 60% develop NPDR after 16 years. Hypertension and hyperlipidemia: In diabetic nephropathy, hypertension is closely associated with the presence of retinopathy. Regardless, hypertension can also make diabetes more difficult because it can cause changes in the retinal arteries of the upper extremities in pre-existing diabetic retinopathy, jeopardizing retinal blood flow. Proper treatment of hyperlipidemia (high serum lipids) can lead to mild retinal detachment and the formation of strong exudates, for unknown reasons (2).

Pregnancy: Pregnant women with proliferative diabetic retinopathy get worse without treatment, but those who have undergone parenteral photocoagulation remain stable during pregnancy. Pregnant women who do not have diabetic retinopathy are 10% more likely to develop NPDR during pregnancy. Of those with current NPDR, 4% growth in the growing category. A study by Toda et al found that pregnant women with diabetic retinopathy are more likely to develop long-term diabetes, pre-pregnancy retinopathy, and secondary hypertension in people with progressive eye disease (3).

### **Pathophysiology of Diabetic Retinopathy**

The exact cause of diabetic retinopathy is unclear, but several theories have been developed to explain the general course and history of the disease. Growth Hormone: Growth hormone appears to play a major role in the development and progression of diabetic retinopathy. Diabetic retinopathy has been shown to be reversible in women with postpartum hemorrhagic necrosis of the pituitary gland (Sheehan syndrome). This led to the controversial practice of removing the pituitary gland in the 1950s to treat or prevent diabetic retinopathy. This procedure has been abandoned due to several systemic problems and the discovery of successful laser treatments. It should be noted that diabetic retinopathy has also been reported in parents with a pituitary gland. Platelets and blood viscosity: various hematological abnormalities manifested in glucose, such as increased erythrocyte aggregation, decreased red blood cell count, increased platelet aggregation and adhesion, sluggish circulation to the patient, endothelial and endothelial damage, in focal capillary occlusion to put. This leads to retinal ischemia, which in turn contributes to the formation of diabetic retinopathy (4).

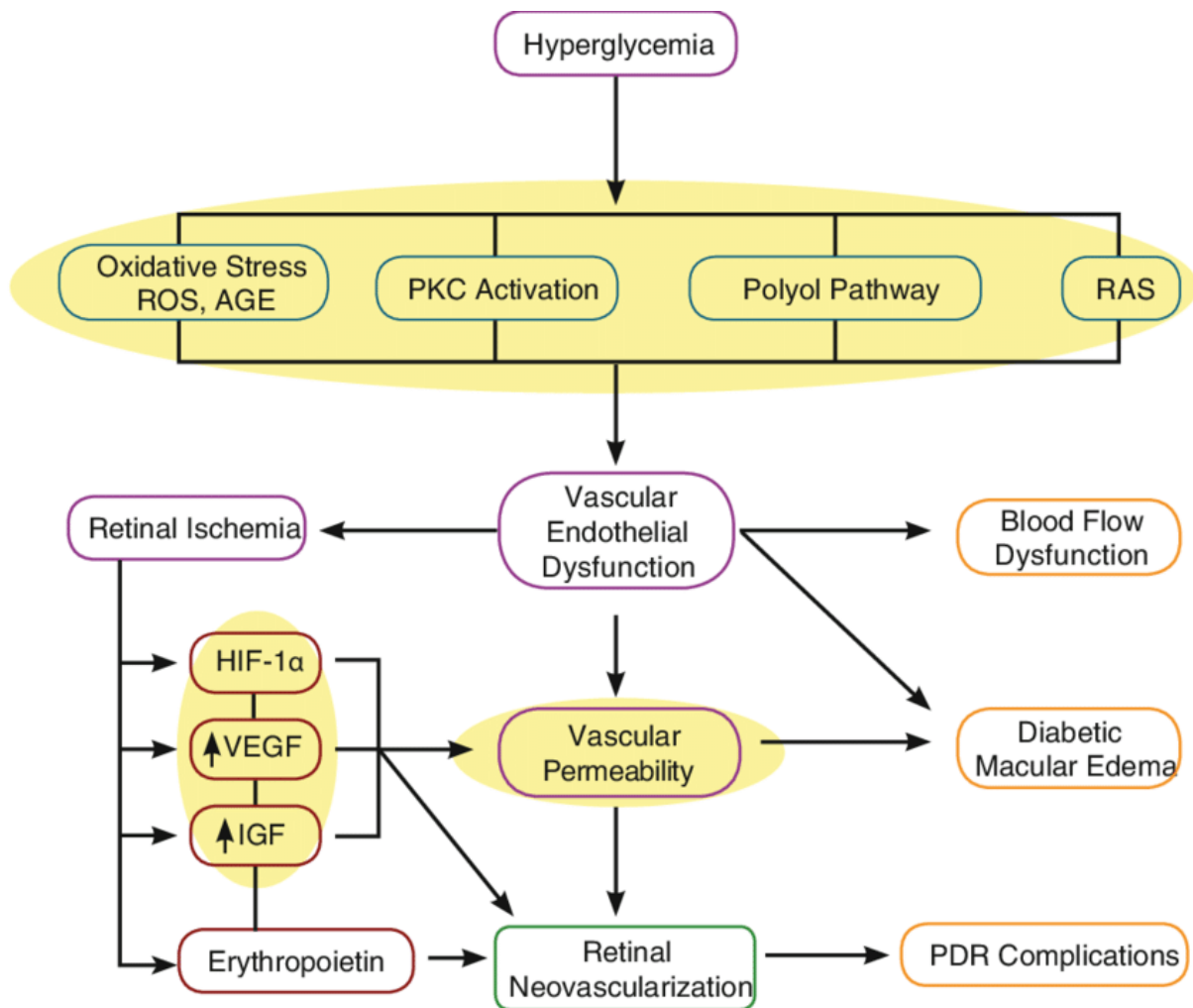
Aldose reductase and vasoproliferative properties: Basically, diabetes mellitus (DM) causes a disruption of glucose metabolism due to decreased levels or insulin activity. Increased blood sugar levels are thought to have a structural and physiological effect on the retinal capillaries making them physically and physiologically inactive. Persistent increase in blood glucose levels inhibits excess glucose in the aldose reductase pathway in certain tissues, which converts sugar into alcohol (e.g., glucose into sorbitol, galactose into dulcitol). Intramural pericyte

retinal capillaries appear to be affected by this increased level of sorbitol, ultimately leading to loss of its primary function (i.e., regulation of autoregulation of retinal capillaries). This causes weakness and ultimately the saccular rupture of the capillary walls. These microaneurysms are the first symptoms of DM retinopathy. Using capillaroscopy video wrapped around the nails, a significant increase in capillary changes was observed in patients with diabetes, especially those with retina damage. This indicates the normal involvement of microvessels in both type 1 and type 2 diabetes. Broken microaneurysms result in retinal bleeding or more (flamable hemorrhage) or deeper layers of the retina (bleeding of dots and dots). Increased access to these vessels causes leakage of fluid and proteins, which are clinically seen as retinal detachment and exudates. If inflammation and discharge include macula, a decrease in central vision may occur (5).

**Macular edema:** Macular edema is the most common cause of vision loss in patients with nonproliferative diabetic retinopathy (NPDR). However, it is not only seen in patients with NPDR; may also complicate cases of proliferative diabetic retinopathy. Another theory to explain the development of macular edema focuses on increased levels of diacylglycerol from excessive glucose inhibition. This is thought to activate protein kinase C, which, in turn, affects the strength of retinal blood, especially inflow and flow, leading to fluid retention and retinal detachment. **Hypoxia:** As the disease progresses, it eventually closes the capillaries of the retina, leading to hypoxia. Infarction of the nerve fiber layer leads to the formation of cotton-wool spots, with associated stasis in axoplasmic flow. Extreme retinal hypoxia triggers compensation in the eye to provide adequate oxygen to the muscles. Abnormal venous caliber, such as venous bumps, bumps, and stretch marks, indicate an increase in hypoxia and is almost always seen in the boundary areas of capillary insufficiency. Intraretinal microvascular abnormalities represent the growth of new vessel or reorganization of existing vessels by increasing endothelial cells within the retinal tissue to act as shunts in unmixed areas (6).

**Angiogenesis:** A progressive increase in retinal ischemia induces the production of angiogenic substances that stimulate new angioplasty. The extracellular matrix is first degraded by proteases, with new blood vessels, primarily derived from the retinal venules, entering the inner narrow membrane, forming a capillary network between the inner retinal region and the posterior surface of the vitreous. Patients with proliferative diabetic retinopathy (PDR) may be at increased risk of iris and / or keratoangiogenesis due to night sweats due to hypoxia / dyspnea. Angiogenesis is usually found at the border of the perfused, untreated retina and usually occurs near the vascular arcade and the head of the optic nerve. New blood vessels break and grow on the retina and behind the posterior surface of the vitreous. These blood vessels, by themselves, usually do not cause visual impairment, but are delicate and easily accessible. These sensitive blood vessels are easily occluded by the traction of the vitreous, causing bleeding into the vitreous or preretinal space. These new blood vessels are initially associated with a small number of fibrous tissue formations. However, as the density of neovascular fronts increases, so does the rate of fibrous tissue formation. At a later stage, the blood vessels may constrict, leaving only a network of avascular fibrous tissue that attaches to both the retina and the posterior surface of the vitreous. As a vitreous contractor, it can exert a

pulling force on the retina through this fibrous connection. Retinal edema, retinal dystrophy due to extension, and split retinal detachment and subsequent retinal tear formation (figure 1) (7).



**Figure 1 Pathophysiology of Diabetic Retinopathy (7)**

### Signs and Symptoms

In the early stages of diabetic retinopathy, patients are often undiagnosed. However, in the more advanced stages of the disease, patients may experience symptoms including swimming, blurred vision, blurred vision and increased vision. Symptoms of diabetic retinopathy include: Microaneurysms: the first clinical symptom of diabetic retinopathy; This is the second time the capillary wall has erupted due to pericyte damage; On the upper part of the retina are small, red spots, dots and spot hemorrhages: when they are small, they look like micro aneurysms. Outbreaks appear to be exacerbated by microenvironment in the deeper layers of the retina, such as the plexiform layer of the inner and outer nuclei. Blood retinal obstruction, which allows the excretion of proteins from serum proteins, lipids, and vessels, Microaneurysms and vascular hyperpermeability are usually limited by venous lesions and venous beds: they are usually found in waterlogged areas. They show an increase in retinal ischemia and their presence is an important sign of progression in diffuse diabetic retinopathy (PDR). Intra-

retinal microvascular abnormalities: Capillary beds are reconstructed without modification. Can be found in the range of retinal and macular edema: a major cause of vision loss in diabetics (8).

Nonproliferative diabetic retinopathy: Mild: indicated by the presence of at least one microaneurysm, moderate: includes bleeding, microaneurysms and the presence of strong exudate, severe: bleeding in 4 quadrants with veins And microaneurysms appear. Beads in at least two quadrants and at least one intraretinal microvessel in at least one quadrant, proliferative diabetic retinopathy: angiogenesis: PDR features, preretinal bleeding: background; like a puddle of blood in this space, Bleeding may look like shaped blood vessels, bleeding may be vitreous: may appear as a veil or clot of blood in the gel, hypertrophy of fibrovascular tissue: it is usually associated It seems to be angiogenic complex; if the blood vessels are already retracted, they may appear avascular. Retinal traction detachment: These are usually superficial, immobile, and appear concave with macular edema (8).

### **Complications**

Diabetic retinopathy involves abnormal blood vessels in the retina. Problems can cause serious vision problems: Vitreous hemorrhage - A clear, jelly-like substance that fills the center of the eye can cause new blood vessels to bleed. If the amount of bleeding is small, you may see some dark (temporary) areas. In severe cases, blood can fill the vitreous cavity and completely block your vision. Vitreous hemorrhage itself does not usually cause permanent vision loss. Bleeding usually occurs within a few weeks or months. Unless your retina is damaged, your vision will likely return to normal. Retinal detachment: The abnormal blood vessels associated with diabetic retinopathy promote the growth of red tissue, which can pull the retina away from the eye. This can cause floating spots in your vision, glare from light, or loss of visual acuity. Glaucoma: New blood vessels can grow in the front of the eye (iris) and block the flow of normal fluid to the eye, causing pressure in the eye. This pressure can damage the sensor that carries images from your eyes to your brain (optic nerve). Blindness - Diabetic retinopathy, macular edema, glaucoma, or a combination of these conditions can lead to complete loss of vision, especially if the conditions are not adequately controlled (9).

### **Prevention**

You can't always prevent diabetic retinopathy. However, regular eye examinations, better control of your blood sugar and blood pressure, and early intervention if you have vision problems can help prevent major vision loss. If you have diabetes, you can reduce your risk of developing diabetic retinopathy by doing the following: Control your diabetes. Make healthy eating and exercise a part of your daily routine. Try to get at least 150 minutes of moderate physical activity each week. Take diabetes medication or insulin as directed. Monitor your blood sugar levels. When you are sick or depressed you may need to check and record your blood sugar several times a day or several times a day. Ask your doctor how long it will take to get your blood sugar checked (10).

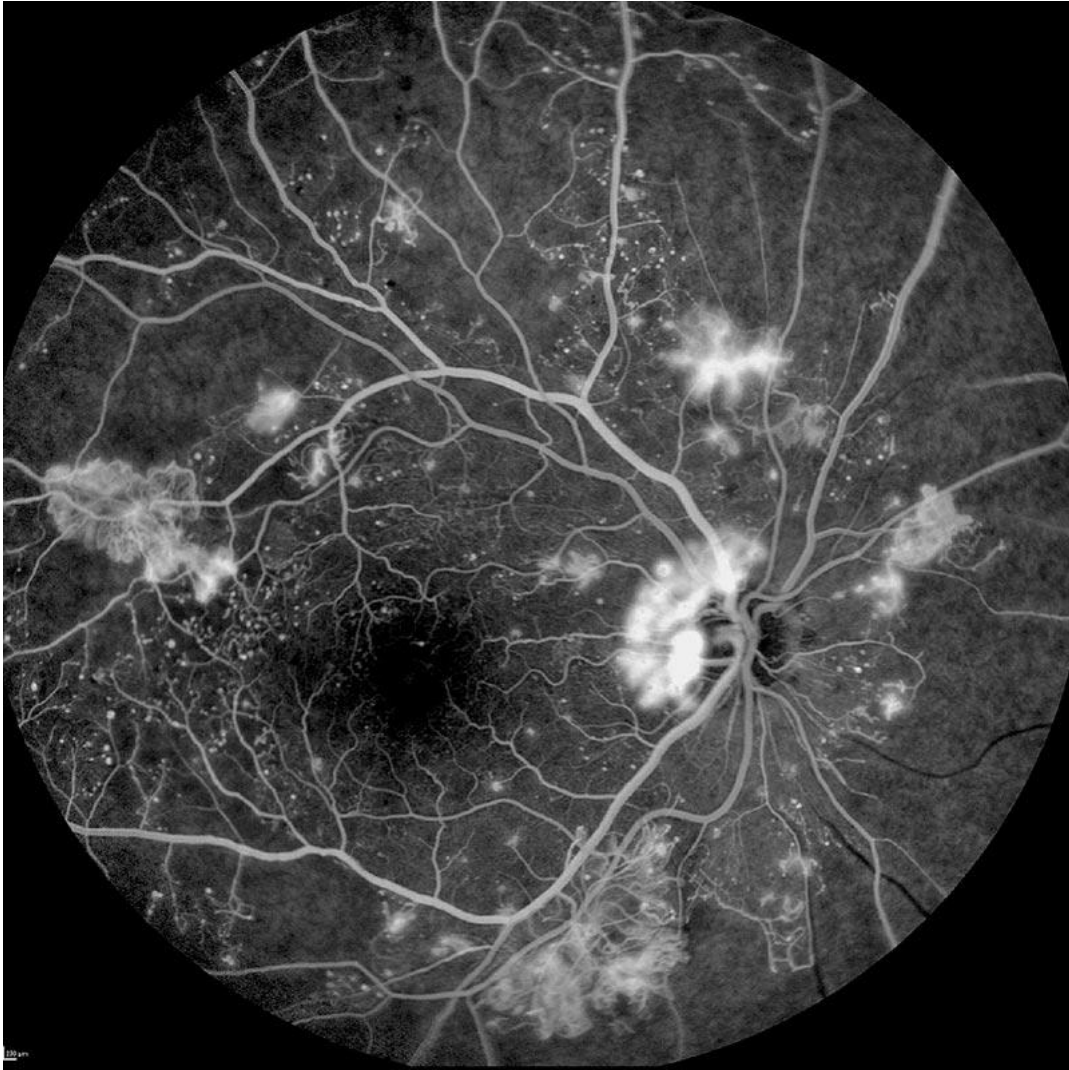
Talk to your doctor about a glyated hemoglobin test. The glyated hemoglobin test, or hemoglobin A1C test, shows your blood glucose level 2-3 months before the test. For most people with diabetes, the A1C goal is less than 7%. Controls blood pressure and cholesterol. Eating a healthy diet, exercising regularly, and gaining weight can help. Sometimes I also need medicine. If you smoke or use other forms of tobacco, ask your doctor to help you quit smoking. Smoking increases the risk of several types of diabetes, including diabetic retinopathy. Notice the change in perspective. Contact your ophthalmologist immediately if your eyesight changes suddenly, blur, stains, or blurs. Remember that diabetes does not cause vision loss. Active participation in the treatment of diabetes can greatly help prevent complications (11).

### **Investigations**

Diagnosis: Diabetic retinopathy is best diagnosed by a comprehensive eye examination. In this test, the drops in your eyes widen (open) your readers so that your doctor can see better inside your eyes. After a few hours the drops can blur your vision as you age. During the exam, your dentist will look for abnormalities inside and outside of your eyes (12).

### **Fluorescein angiography**

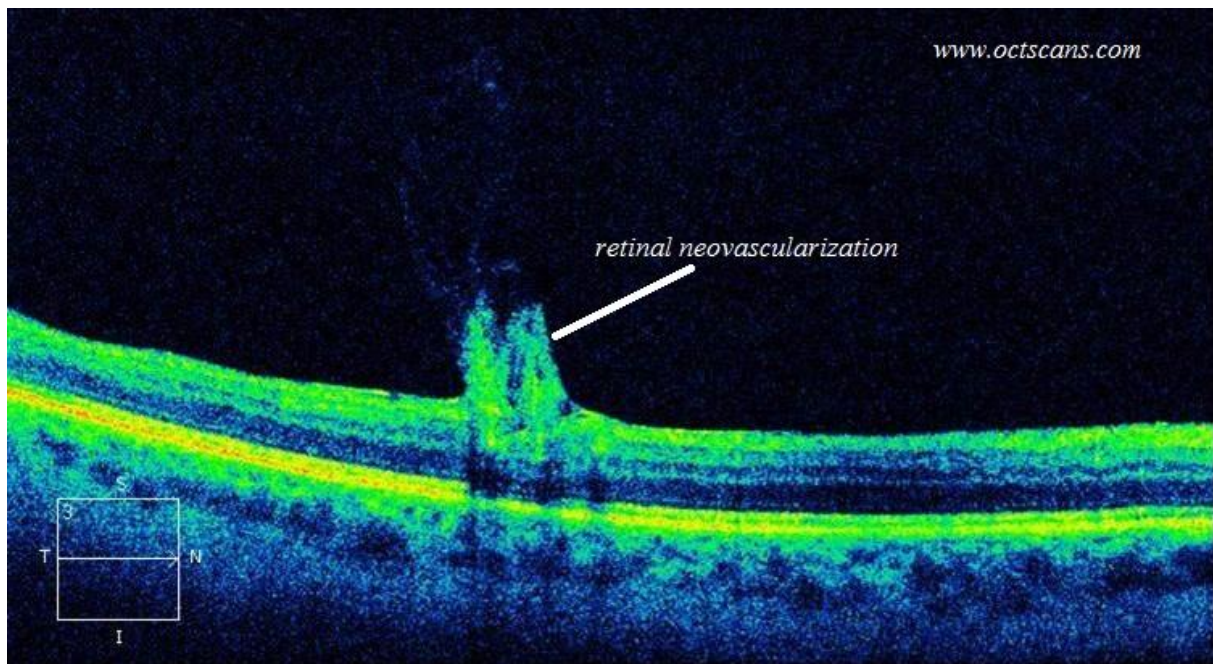
After you open your eyes, the dye is injected into a vein in your arm. These are then photographed in the blood vessels of your eyes. Images may indicate blocked, ruptured, or leaking blood vessels (figure 2) (13).



**Figure 2 Fluorescein angiography for Diabetic Retinopathy (14)**

### **Optical coherence tomography (OCT)**

With this test, the images provide different images of the retina that show retinal density. This will help determine how much fluid, if any, is seeping into the retinal tissue. Afterwards, OCT tests may be used to monitor how well the treatment is working (figure 3) (15).



**Figure 3 Optical Coherence Tomography (OCT) for Diabetic Retinopathy (15)**

### **Treatment**

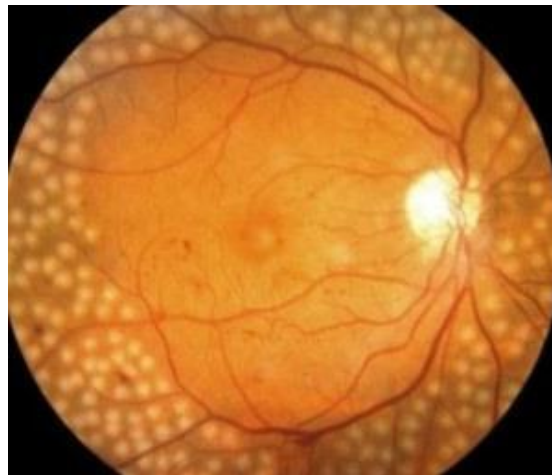Treatment, which largely depends on the type of diabetes retinopathy and its severity, is designed to reduce or stop the progression. Pre-diabetic retinopathy: If you have mild to moderate diabetic retinopathy, you may not need immediate treatment. However, your ophthalmologist will closely monitor your eyes to determine when you may need treatment. Check with your diabetes specialist (endocrinologist) to see if there are any ways to improve your diabetes care. If diabetic retinopathy is mild to moderate, proper control of blood sugar can often slow growth (16).

Advanced Diabetic Retinopathy: If you have diabetic retinopathy or macular edema, you will need immediate treatment. Depending on the specific problems in your retina, your options may include: Eye treatment injection: These drugs, called vascular endothelial growth factor inhibitors, are injected into the eye glass. They help stop the growth of new blood vessels and reduce fluid buildup. The United States Food and Drug Administration (FDA) has approved two drugs for the treatment of diabetic macular edema ranibizumab (Lucentis) and aflibercept (Eylea). A third drug, bevacizumab (Avastin), can be used to treat macular edema of diabetes without a label. These drugs are administered under topical anesthesia. Mild discomfort, such as fever, sadness or pain, may occur within 24 hours after the injection. Possible side effects include increased eye pressure and infection. These injections will need to be repeated. In some cases, the drug is used for photocoagulation (16).

### **Photocoagulation**

This laser treatment, also known as focal laser treatment, can stop or slow blood flow and fluid from the eye. During the procedure, vascular abnormalities are usually treated with laser burns. Targeted laser treatments are usually done at the same time in a doctor's office or

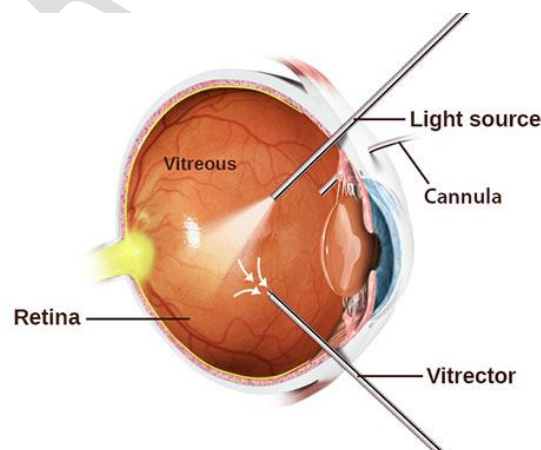
ophthalmology clinic. If you had blurred vision due to macular edema before surgery, treatment may not normalize your vision, but it can reduce your chances of developing macular edema. Panretinal photocoagulation: This laser treatment, also known as diffuse laser treatment, can shrink abnormal blood vessels. During the procedure, areas of the retina away from the macula are treated with diffuse laser burns. Burns cause new, abnormal blood vessels to constrict and scar. This is usually done twice or more often in your doctor's office or ophthalmology clinic. About a day after your procedure, your vision will be blurry. Other loss of peripheral vision or night vision may occur after the procedure (figure 4) (17).



**Figure 4 Photocoagulation for Diabetic Retinopathy (18)**

### **Vitrectomy**

This procedure uses a small incision in the eye to remove blood between the eye (vitreous) and the red tissue that drains the retina. It is performed in a surgical or hospital setting using local or general anesthesia (figure 5) (19).



**Figure 5 Vitrectomy (20)**

### **Discussion**

In the early stages of diabetic retinopathy, patients usually do not look good, but in the more advanced stages of the disease, patients may experience symptoms such as floating, distorted,

and / or blurred vision. Microaneurysms are the first clinical sign of diabetic retinopathy. Kidney disease is an excellent predictor of retinopathy, as indicated by elevated proteinuria and blood urea nitrogen (BUN) / creatinine levels. Both conditions are caused by DM-related microangiopathy, the presence and intensity of one reflecting that of the other. Intensive care of nephropathy can slow the progression of diabetic retinopathy and neovascular glaucoma. A study by Ito et al. Showed that the presence of decreased peripheral nerve conduction velocity was associated with the presence of early diabetic retinopathy in patients with type 2 diabetes. The report included 42 patients (42 eyes) with type 2 diabetes who were likely not to have diabetic or non-diabetic retinopathy. Researchers found that the latter group had significantly lower peritoneal sensory and tibial motor conduction rates than patients without diabetic retinopathy, and retrospective logistic analysis showed that these veins were disease-independent. It has been shown to be a risk factor. Chronic eye. According to diabetes management and complication studies, managing diabetes and maintaining HbA1c levels at 6-7% can significantly reduce the progression of diabetic retinopathy. Patient education is one of the most important factors in the management of diabetic retinopathy. Inform patients that they play an important role in eye care (21).

## **Conclusion**

Diabetic retinopathy persists for a long time and often leads to the development of retinopathy in patients of early adolescence and macular edema in older patients. Occasional ophthalmoscopic examination is essential to detect the progression of retinopathy and the development of symptoms that indicate the need for treatment. Clinical and laboratory experience underscores the importance of rigorous blood sugar control in the prevention of diabetic retinopathy. Ischemia of the medial retina promotes the development of very dangerous substances where panretinal photocoagulation occurs despite adverse effects such as decreased dark circulation. Pars plana vitrectomy results in significant visual acuity with vitreous hemorrhage that does not clear and / or retinal traction covering the macula. Future advances in our understanding of diabetic retinopathy should be based on the National Eye Institute Collaborative Diabetic Retinopathy Vitrectomy Study and prediabetic therapy research, as well as an analysis of vasoformative factors.

## **References**

- 1) Arevalo JF, Garcia-Amaris RA. Intravitreal bevacizumab for diabetic retinopathy. *Curr Diabetes Rev.* 2009 Feb. 5(1):39-46.
- 2) Baker CW, Jiang Y, Stone T. Recent advancements in diabetic retinopathy treatment from the Diabetic Retinopathy Clinical Research Network. *Curr Opin Ophthalmol.* 2016 May. 27 (3):210-6.
- 3) Barchetta I, Riccieri V, Vasile M, et al. High prevalence of capillary abnormalities in patients with diabetes and association with retinopathy. *Diabet Med.* 2011 Sep. 28(9):1039-44.
- 4) Bhavsar AR, Grillone LR, McNamara TR, Gow JA, Hochberg AM, Pearson RK. Predicting response of vitreous hemorrhage after intravitreal injection of highly

purified ovine hyaluronidase (Vitrase) in patients with diabetes. *Invest Ophthalmol Vis Sci.* 2008 Oct. 49(10):4219-25.

- 5) Bragge P, Gruen RL, Chau M, Forbes A, Taylor HR. Screening for Presence or Absence of Diabetic Retinopathy: A Meta-analysis. *Arch Ophthalmol.* 2011 Apr. 129(4):435-44.
- 6) Brown DM, Nguyen QD, Marcus DM, Boyer DS, Patel S, Feiner L, et al. Long-term outcomes of ranibizumab therapy for diabetic macular edema: the 36-month results from two phase III trials: RISE and RIDE. *Ophthalmology.* 2013 Oct. 120(10):2013-22.
- 7) Crawford TN, Alfaro DV 3rd, Kerrison JB, Jablon EP. Diabetic retinopathy and angiogenesis. *Curr Diabetes Rev.* 2009 Feb. 5(1):8-13.
- 8) Diabetic Retinopathy Clinical Research Network. A randomized trial comparing intravitreal triamcinolone acetonide and focal/grid photocoagulation for diabetic macular edema. *Ophthalmology.* 2008 Sep. 115(9):1447-9, 1449.
- 9) Elman MJ, Aiello LP, Beck RW, Bressler NM, Bressler SB, Edwards AR, et al. Randomized trial evaluating ranibizumab plus prompt or deferred laser or triamcinolone plus prompt laser for diabetic macular edema. *Ophthalmology.* 2010 Jun. 117(6):1064-1077.
- 10) Klein R, Knudtson MD, Lee KE, Gangnon R, Klein BE. The Wisconsin Epidemiologic Study of Diabetic Retinopathy XXIII: the twenty-five-year incidence of macular edema in persons with type 1 diabetes. *Ophthalmology.* 2009 Mar. 116(3):497-503.
- 11) Massin P, Lange C, Tichet J, Vol S, Erginay A, Cailleau M, et al. Hemoglobin A1c and fasting plasma glucose levels as predictors of retinopathy at 10 years: the French DESIR study. *Arch Ophthalmol.* 2011 Feb. 129(2):188-95.
- 12) Morrison JL, Hodgson LA, Lim LL, Al-Qureshi S. Diabetic retinopathy in pregnancy: a review. *Clin Exp Ophthalmol.* 2016 May. 44 (4):321-34.
- 13) Rodriguez-Fontal M, Alfaro V, Kerrison JB, Jablon EP. Ranibizumab for diabetic retinopathy. *Curr Diabetes Rev.* 2009 Feb. 5(1):47-51.
- 14) Rodriguez-Fontal M, Kerrison JB, Alfaro DV, Jablon EP. Metabolic control and diabetic retinopathy. *Curr Diabetes Rev.* 2009 Feb. 5(1):3-7.
- 15) Sabanayagam C, Yip W, Ting DS, Tan G, Wong TY. Ten Emerging Trends in the Epidemiology of Diabetic Retinopathy. *Ophthalmic Epidemiol.* 2016 Aug. 23 (4):209-22.
- 16) Shiba T, Takahashi M, Hori Y, Saishin Y, Sato Y, Maeno T. Relationship between sleep-disordered breathing and iris and/or angle neovascularization in proliferative diabetic retinopathy cases. *Am J Ophthalmol.* 2011 Apr. 151(4):604-9.
- 17) Wells JA, Glassman AR, Ayala AR, et al. Aflibercept, bevacizumab, or ranibizumab for diabetic macular edema. *N Engl J Med.* 2015 Mar 26. 372(13):1193-203.
- 18) Williams R, Airey M, Baxter H, Forrester J, Kennedy-Martin T, Girach A. Epidemiology of diabetic retinopathy and macular oedema: a systematic review. *Eye (Lond).* 2004 Oct. 18(10):963-83.
- 19) Writing Committee for the Diabetic Retinopathy Clinical Research Network, Gross JG, Glassman AR, et al. Panretinal Photocoagulation vs Intravitreal Ranibizumab for

Proliferative Diabetic Retinopathy: A Randomized Clinical Trial. *JAMA*. 2015 Nov 24. 314 (20):2137-46.

20) Zhang X, Saaddine JB, Chou CF, Cotch MF, Cheng YJ, Geiss LS, et al. Prevalence of diabetic retinopathy in the United States, 2005-2008. *JAMA*. 2010 Aug 11. 304(6):649-56.

21) Korobelnik JF, Do DV, Schmidt-Erfurth U, Boyer DS, Holz FG, Heier JS, et al. Intravitreal aflibercept for diabetic macular edema. *Ophthalmology*. 2014 Nov. 121(11):2247-54.

UNDER PEER REVIEW