

# Review Article

## Uveitis: Classification, Diagnosis and Treatment

### Abstract

Background: Uveitis is a common disease that mainly affects young people. This leads to significant material losses. Acute anterior uveitis is the most common form and is often associated with spondyloarthritis, in which uveitis may be the first manifestation of the disease. Specific specimens of uveitis are often associated with systemic disease. Thus, close collaboration between ophthalmologists and orthopedic surgeons avoids unnecessary diagnostic tests and is essential for accurate diagnosis and treatment of such patients. Acute anterior uveitis usually has a better diagnosis than other forms of uveitis. However, it causes paralysis when inflammation is common. Expected small studies with sulfasalazine have shown a decrease in growth. In some forms of uveitis, diagnosis is difficult, and systemic corticosteroids and / or drugs that suppress the immune system are often needed. Infliximab is a promising treatment for selected patients.

Comment [H1]: the accurate

Comment [H2]: and/or

Conclusion: Uveitis in childhood is a serious disease associated with vision-threatening problems. Uveitis associated with juvenile rheumatoid arthritis remains the leading cause of eye disease in patients with childhood uveitis.

**Keywords:** *Iritis; pars planitis; choroiditis; retinitis; chorioretinitis; anterior uveitis; posterior uveitis; sarcoid uveitis.*

### Introduction

Uveitis is a type of eye inflammation. It affects the middle layer of tissue of the eye wall. The warning signs of uveitis often appear suddenly and worsen quickly. These include redness of the eyes, pain, and blurred vision. This condition can affect one or both eyes, and can affect people of all ages, even children. Possible causes of uveitis infection, injury or autoimmune disease, or inflammatory disease. Often the cause cannot be identified. Uveitis can be dangerous, causing permanent loss of vision. Early diagnosis and treatment are needed to prevent complications and maintain your vision (1).

Comment [H3]: eyewall

Comment [H4]: remove ,

### Causes and Risk Factors

Although uveitis is often associated with a primary systemic disease, about 50 percent of patients with idiopathic uveitis may not be associated with any other clinical disease. Acute granulomatous uveitis is associated with human leukocyte antigen B27 (HLA B27) diseases, including ankylosing spondylitis, inflammatory bowel disease, functional arthritis, psoriatic

Comment [H5]: remove a

arthritis, and Behcet's disease. Herpes simplex, herpes zoster, Lyme disease, and trauma are also associated with acute non-granulomatous uveitis. Chronic non-granulomatous uveitis is associated with childhood rheumatoid arthritis, chronic childhood iridocyclitis, and Fuchs heterochromic iridocyclitis. Chronic granulomatous uveitis is characterized by sarcoid, syphilis, and tuberculosis. Posterior uveitis is found in diseases such as toxoplasmosis, ocular histoplasmosis, syphilis, sarcoid, and in immunocompromised hosts with CMV or Candida or herpes infection. Embolic retinitis can also cause uveitis in the back (2).

Comment [H6]: plagiarized rephrase it

Comment [H7]: correct spelling

### Mechanism of Uveitis

The etiology of uveitis is usually idiopathic; However, genetic, destructive or infectious mechanisms are known to promote or exacerbate uveitis. Diseases that cause uveitis in the patient and who may be admitted to the emergency department include inflammatory bowel disease, rheumatoid arthritis, systemic lupus erythematosus (SLE), sarcoidosis, tuberculosis, syphilis, and AIDS. It is believed that the traumatic approach is a combination of microbial contamination and accumulation of necrosis products at the site of injury, prompting the body to stimulate an inflammatory response at the front of the eye. It has been reported that with uveitis of an infectious etiology, the immune response directed to foreign molecules or antigens can damage the vessels of the uveal tract and cells. If uveitis is diagnosed with an autoimmune disorder, the immune system may have a hypersensitivity reaction that involves the injection of an immune complex into the uveal tract. The prevalence of etiology among all anatomical forms of uveitis, anterior, intermediate and posterior, was as follows: idiopathic (34%), seronegative spondyloarthropathies (10.4%), sarcoidosis. (9.6%), juvenile rheumatoid arthritis (JRA) (5.6%), SLE (4.8%), Behcet's disease (2.5%) and AIDS (2.4%) (3).

Comment [H8]: , or

Comment [H9]: Plagiarized rephrase it

Comment [H10]: ,and

Seronegative arthropathies include nonspecific ankylosing spondylitis, Reiter's syndrome, psoriatic arthropathy, and inflammatory bowel disease. In a similar study by Rodríguez et al. Anterior uveitis was the most common form with 51.6% and the etiological distribution was as follows: idiopathic (37.8%), seronegative arthropathy (21.6%), JRA (10.8%), i-herpesvirus (9.7%), Sarcoidosis (5.8%), SLE (3.3%), rheumatoid arthritis (0.9%), posterior uveitis were the most frequent, in 19.4% the most frequent etiologies Toxoplasma (24.6%), idiopathic (13.3%), cytomegalovirus (CMV) (11.6%), SLE (7.9%) and sarcoid (7.5%) (4).

Comment [H11]: Plagiarized rephrase it

Pathological examination of eye samples has provided invaluable information about cellular mediators, tissue damage and treatment options found in patients with uveitis. Immune cells identified in pathological specimens include T and B cell lymphocytes, macrophages, and epithelioid cells. For example, in uveitis associated with sarcoidosis, CD4 + T cells are elevated, although CD8 + T and B cells have also been found. Granulomas, including large multinucleated cells (aggregates of macrophages) and epithelioid cells, have also been identified; However, granulomas have been identified in other uveitic conditions, including eye diseases and micro ophthalmology. After infiltration of the eye tissue with inflammatory cells, the release of cytokines and recruitment of additional leukocytes leads to further tissue damage and the outcome of injury and fibrosis. These processes have been described by the late stage of Vogt-Koyanagi-Harada Disease (VKH), including subretinal fibrosis and

Comment [H12]: ,and

Comment [H13]: Correct spell

choroidal neovascularization in a significant percentage of patients with chronic VKH disease (figure 1) (5).

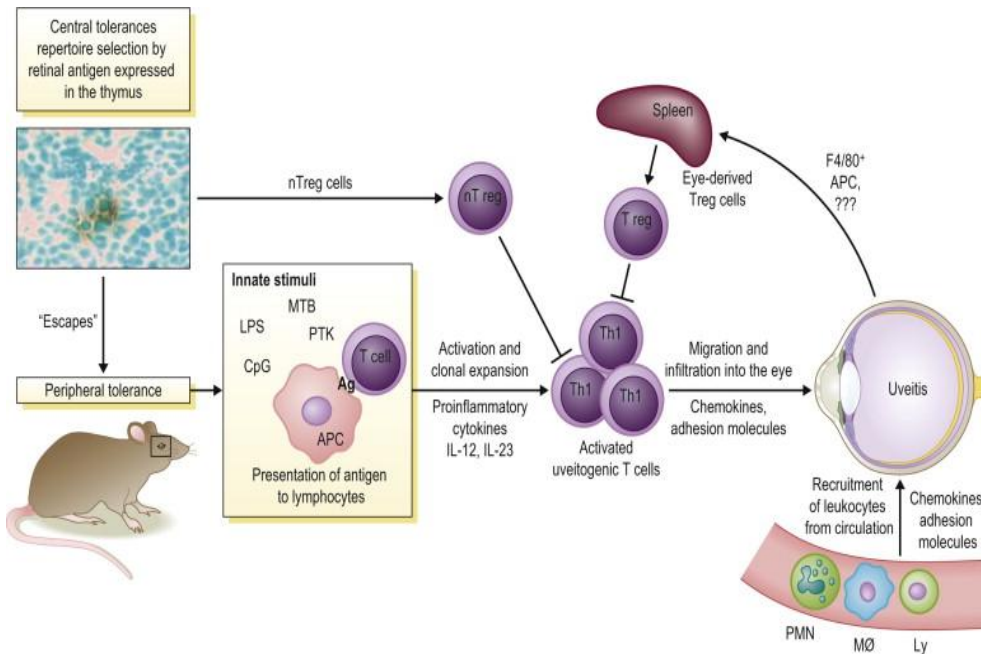


Figure 1 Mechanism of Uveitis (5)

### Classification of Uveitis

Anterior: The most common type of anterior uveitis causes inflammation in the front of the eye. Symptoms may appear suddenly and, in mild cases, may resolve spontaneously. Some people have chronic recurrent eye inflammation that disappears with treatment and then relapses. If you have, you are likely to have anterior uveitis: rheumatoid arthritis, including ankylosing spondylitis (AS). Independent diseases such as sarcoidosis and juvenile idiopathic arthritis. Enteropathy such as inflammatory bowel disease (IBD), Pre-infection with herpesvirus (cold or genital herpes) or chickenpox (6).

Comment [H14]: Plagiarized rephrase it

Intermediate: Young adults are more susceptible to moderate uveitis. This condition causes swelling in the middle part of the eye. Also called cyclitis or vitritis, it usually affects the fluid-filled space inside the eye. Symptoms can get better, go away, come back, and get worse. About one in three people with moderate uveitis also have: multiple sclerosis (MS) and sarcoidosis (6).

Comment [H15]: Herpes virus

Comment [H16]: Remove colon

Posterior: A very rare form, posterior uveitis affects the inner part of the eye. It is often also very difficult. It can affect the retina, optic nerve and choroid. Choroid contains blood vessels that carry blood to the retina. It is sometimes called choroiditis or chorioretinitis. This type can cause recurrent symptoms that last for months or years. Possible causes include: birdshot

Comment [H17]: , and

Comment [H18]: Plagiarized rephrase it

Comment [H19]: The choroid

Comment [H20]: Remove colon

chorioretinopathy, Viral etiologies such as the herpes virus or chicken pox virus. Lupus, Sarcoidosis, Syphilis and Tuberculosis (6)

Comment [H21]: ,and

Panuveitis: Rarely, uveitis affects all three layers of the eye. This type is very difficult and raises the risk of permanent vision loss. Possible causes include: Bacterial or fungal retinitis. Viral retinitis, Toxoplasmosis, Lupus, Sarcoidosis, Syphilis and Tuberculosis (TB) (figure 2) (6).

Comment [H22]: Plagiarized rephrase it

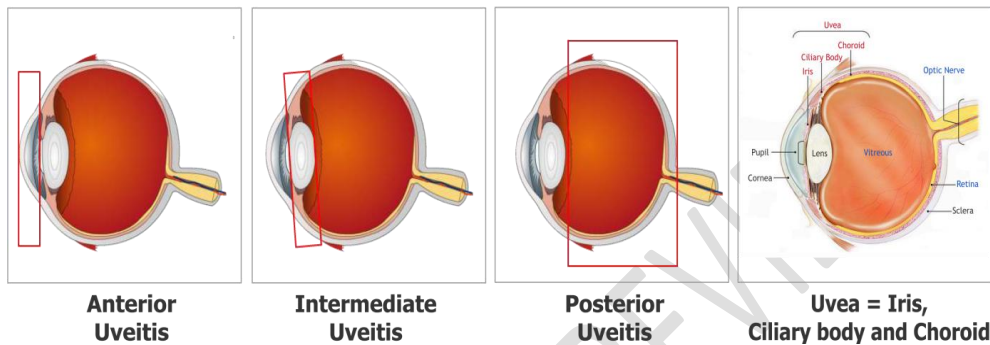


Figure 2 Classification of Uveitis (7)

### Signs and Symptoms

signs and symptoms of uveitis may include the following: redness, eye pain, tenderness, blurred vision, darkness, floating areas (floating) in your field of vision, loss of vision, symptoms may appear suddenly and worsen rapidly, although some In cases they progress slowly. They can affect one or both eyes. Sometimes symptoms do not appear, and the symptoms of uveitis are diagnosed by regular eye tests. Uvea is the middle layer of tissue in the eye wall. Contains iris, ciliary body and choroid. When you look in the mirror, you can see the white part of the eye (sclera) and the colored part of the eye (iris). The iris is located at the front of the eye. The ciliary body is the posterior structure of the iris. The choroid is a layer of blood vessels between the retina and the skin. Puts like retina wallpaper inside the fundus. The back is filled with a jelly-like fluid called vitreous humor (8).

Comment [H23]: eyewall

Comment [H24]: the iris

Comment [H25]: ,and

The type of uveitis you get depends on which part or parts of the eye are inflamed. Anterior uveitis affects the front of your eye (between the cornea and iris) and the ciliary body. It is also called iritis and is the most common type of uveitis. Moderate uveitis affects the retina and blood vessels just behind the lens (pars plana) and in the center of the eye (vitreous humour). Posterior uveitis affects the inner lining of the back of your eye, the retina or choroid. Panuveitis occurs when all layers of uvea from the front to the back of the eye are burned (9).

Comment [H26]: Plagiarized rephrase it

Comment [H27]: Correct spell

Comment [H28]: Plagiarized rephrase it

Comment [H29]: the uvea

### Complications

Uvitis can cause additional complications if left untreated. Problems are more likely to occur if: 60 years of age or older, chronic (chronic) chronic uveitis, rare forms of middle or

Comment [H30]: correct spell

posterior uveitis (middle or posterior uveitis), most common problems with uveitis include: glaucoma : When the optic nerve that connects the eyes. The brain is damaged. Cataracts can lead to vision loss if not detected and treated in time: Cystic luteal edema: Inflammation of the retina, if the change in the crystal line lens of the eye causes blurred vision and cloudy or Fog causes blindness (yes) can affect people with chronic illness. Or posterior venous inflammation, retinal displacement: When the retina begins to leak blood vessels that provide oxygen and nutrients and later adhesive: Inflammation that attaches to the iris lens. Iso: Uveitis is more likely to occur if not treated immediately (10).

Comment [H31]: correct spell

It is important to establish an accurate diagnosis and establish a follow-up plan before starting treatment. Topical corticosteroids are a common treatment for early uveitis; However, they can increase intraocular pressure (IOP). Therefore, the patient must observe ophthalmology to be careful to resolve and control the IOP. Long- or short-term intraocular inflammation can lead to pathological changes in the eye that can lead to permanent loss of vision. These complications include cataracts, posterior synechiae, epiretinal membrane (ERM), cystoid macular edema (CME), band keratopathy, hypotonia, glaucoma, and optic nerve edema. Although waiting room inflammation can be treated with topical steroids, some types of inflammation should never be treated with intraocular, periocular, or oral steroids unless detailed due to the risk of serious disease and obvious prognosis. Infectious etiology is not excluded by laboratory tests and analysis. Central and posterior panuveitis and panuveitis should be referred to ophthalmologists, especially specialists in uveitis, if possible, for diagnosis and treatment (11).

### Investigations and Diagnosis

Laboratory tests: This activity should be related to the patient's medical history, or signs or symptoms that indicate a particular etiology. In some cases, you may not need to work in the laboratory. In the case of trauma, known systemic disease, or unilaterally fused soft tissue uveitis with a history, laboratory tests may not be useful if the body does not indicate systemic disease. Indirect efficacy is indicated when the history and results of physical examination are not significant in the presence of bilateral uveitis, granulomatous uveitis or recurrent uveitis. Subsequent tests do not have to be done in the emergency department and can be ordered by the doctor as an inpatient. CBC, Erythrocyte sedimentation rate (ESR), Antinuclear antibody (ANA), Rapid Plasma Reagin (RPR), Venereal Disease Research Laboratory (VDRL), Purified Protein Derivative (PPD), Lyme Titer, HLA-B27, Analytical urine and HIV test . If you meet an ophthalmologist, you will be able to examine your eyes and get a complete medical history. Visual acuity tests typically include: Visual examination (usually using spectacles if wearing spectacles) and student response to light (12).

Comment [H32]: correct punctuate

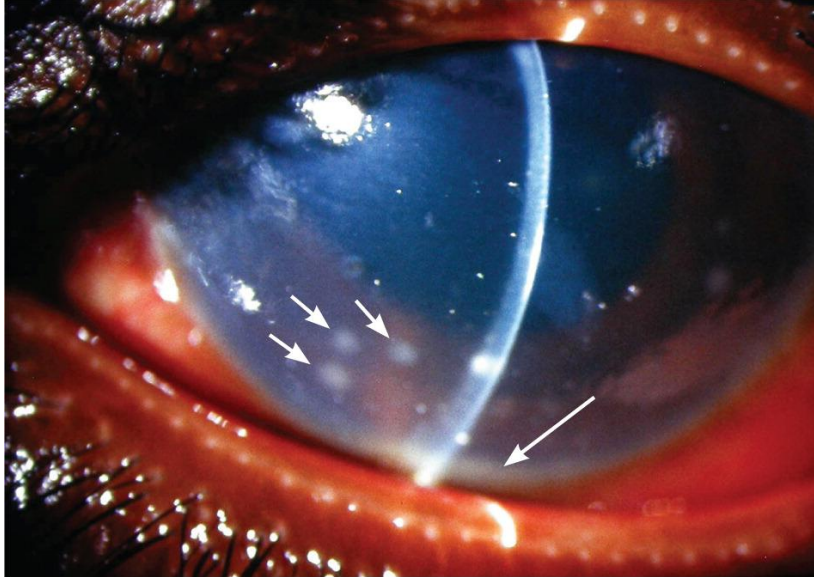
Comment [H33]: remove colon

### Tonometry

Tonometry measures the pressure inside the eye (intraocular pressure). Anesthetic eye drops can be used for this test (12).

### A slit-lamp examination

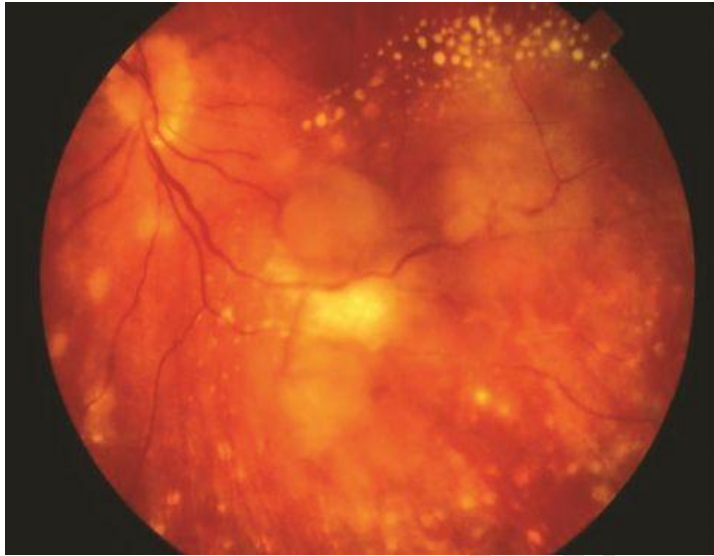A slit lamp is a microscope that magnifies the area in front of you and illuminates it with a strong line of light. This assessment is necessary to identify the microscopic inflammatory cells in the front of the eye (figure 3) (12).



**Figure 3 Acute anterior uveitis caused by sarcoidosis. The eye is intensely red and the cornea is shaded. Large groups of inflammatory cells are seen on the posterior surface of the cornea (small arrows); there is a 1 mm hypopyon (long arrow) (12).**

#### **Ophthalmoscopy**

Also known as funduscopy, this test involves widening the pupil with eye drops and bright light in the eye to examine the back of the eye (figure 4) (13).



**Figure 4 Severe sarcoid panuveitis with multiple choroidal granulomas and peripheral chorioretinal scarring in the posterior pole (13).**

#### **Color photography of the inside of the eye (retina)**

**Comment [H34]:** plagiarized

The Retina Funds Color Image uses the Funds Camera to record color images of the condition of the inner surface of the eye to document the presence of abnormalities and track their changes over time. This allows technicians to take pictures of a very large area and get a clear picture of the back of the eye (14).

#### **Optical coherence tomography (OCT) imaging**

This test measures retinal and choroid thickness to detect inflammation in these layers (14).

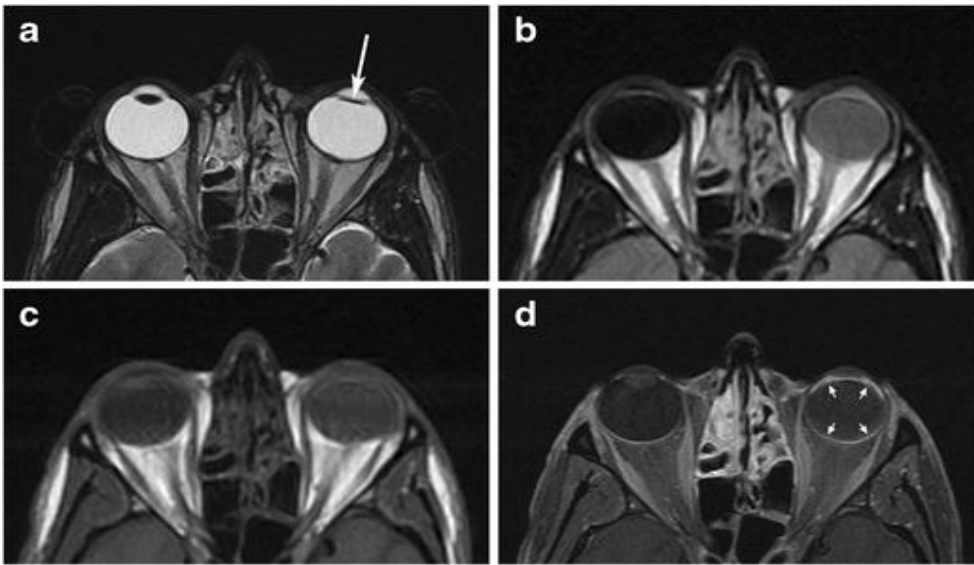
#### **Fluorescein angiography or indocyanine green angiography**

An intravenous (IV) catheter must be inserted into a vein in the arm to color these tests. This color reaches the blood vessels of the eye and allows you to take pictures of inflammation of the blood vessels in the eye (14).

#### **Analysis of aqueous or vitreous fluid from the eye, Radiography and CT**

##### **MRI scans**

If the ophthalmologist thinks that an underlying condition may be the cause of your uveitis, you may be referred to another doctor for regular checkups and laboratory tests. Sometimes it is difficult to pinpoint a single cause of uveitis. Even if no specific cause has been identified, uveitis can be successfully treated. In most cases, identifying the cause of uveitis is not a cure. It is still important to use some form of treatment to control the inflammation (figure 5) (14).



**Figure 5** Panuveitis in patients with a - d ankylosing spondylitis. Improved axial T2WI (a), axial (a), FLAIR (b), T1WI (c), and T1WI images in which luma and saturation (d) show a balance between water and glass, and increase the light of gadolinium - Left eye calf groove. The jokes of the left globe are much more dynamic than those of the right in the images with unchanged T1 weight and are surprisingly more intense in the unrevealed FLAIR. There is no significant difference in T2 weight images. The increased brightness of the left ventricular line (arrow) is commendable compared to the normal right eye and the front brightness (c) and post contrast axial (d) images with T1-weighted images. Also noted the formation of cataracts in the left eye (arrow) (14).

### Treatment

If uveitis is caused by a low-grade condition, treatment may focus on that specific condition. Treatment of uveitis is usually the same regardless of the underlying cause, unless it is contagious. The goal of treatment is to reduce the inflammation in your eyes and other parts of the body, if it occurs. In some cases, treatment may be needed for months or even years. There are many treatments available. Medications: Medications that reduce inflammation. Your doctor may prescribe oral contraceptives, such as corticosteroids. Eye drops are not sufficient to treat inflammation outside the eye, so corticosteroid injections or corticosteroid tablets (taken orally) may be needed in or near the eyes. Medications that control cramps. Eye drops that enlarge (expose) the pupil may be indicated to control iris and ciliary body spasms, which may help relieve eye pain. Antibiotics or antimicrobial drugs. If uveitis is caused by an infection, your doctor may prescribe other medications to control the infection, with or without antibiotics, antibiotics or corticosteroids. Drugs that affect the immune system or destroy cells. If your uveitis affects both eyes, does not respond well to corticosteroids, or is severe enough to threaten your vision, you may need immunosuppressive medications. Some of these medications can cause serious eye-related side effects, such as glaucoma and

Comment [H35]: remove ,

Comment [H36]: remove ,

Comment [H37]: ,or

Comment [H38]: plagiarized rephrase it

cataracts. Oral or injectable medications can cause side effects in other parts of the body besides the eyes. You may need to see your doctor for follow-up and blood tests every one to three months (15).

### Surgical or other procedures

#### Vitrectomy

Surgery to remove another vitreous from your eye is rarely used to diagnose or control the condition (figure 6) (16).

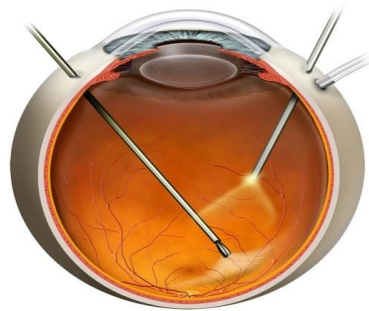

Figure 6 Vitrectomy (16)

#### A medication-releasing implant

Ophthalmic tools may be an option for people with posterior uveitis that are difficult to treat. This device gently removes corticosteroids from the eye for 2-3 years. Cataracts are common in people who have not yet developed cataracts. Up to 30% of patients require high-pressure eye treatment to prevent the development of glaucoma. The rate of recovery depends partly on the type of uveitis and the severity of the symptoms. Uveitis (retinal uveitis or panuveitis, including retinitis or choroiditis) that affects the back of the eye is usually greater than anterior uveitis (anterior uveitis or iritis). Acute inflammation takes longer to resolve than mild inflammation. Uveitis may recur. If your symptoms recur or worsen, take time to see your doctor (17).

Comment [H39]: correct spelling

#### Discussion

For many years, uveitis was considered a unique disease; Therefore, the method of treatment was very different. With increasing knowledge about the course of the disease and increasing complexity of immunological and microbiological tests, it became clear that uveitis covers a broad spectrum of diseases. Although some disorders are local immune system disorders, most are systemic disorders with ocular manifestations. Since the spectrum of disease pathogenesis ranges from autoimmunity to neoplasia and viruses, a uveitis doctor should understand internal medicine, infectious diseases, rheumatology and immunology. Patients with uveitis can experience some of the most difficult diagnostic problems in ophthalmology. Since the treatment and prognosis of different uveitic organizations vary widely, an accurate diagnosis is required. Many diseases including Fuchs uveitis syndrome (also known as Fuchs

Comment [H40]: the

Comment [H41]: ,and

Comment [H42]: Include

heterochromic iridocyclitis), Behçet's disease, toxoplasmosis, cytomegalovirus (CMV) retinitis, ocular histoplasmosis, and Vogt-Koyanagi-Harada (VKH) disease, less common clinical conditions, if available. , Laboratory analysis. Likewise, a patient with the first episode of acute non-granulomatous anterior uveitis with a surprise examination of the systems and a physical exam will not require laboratory testing (18).

Laboratory tests are rarely as useful as diagnostic tools. When deciding which tests to perform, it is useful to use historical and physical indicators, as well as knowledge of pre-existing diagnostic abilities of the disease. This diagnostic procedure is important to avoid false results and costly and unnecessary tests. Therefore, there is no standard laboratory test available for a patient with uveitis other than the diagnosis of syphilis and sarcoidosis, both of which can occur in different ways. The key to a focused and effective patient assessment is a complete history, physical examination, and systemic examinations. With this information, the doctor can make a different diagnosis and perform further laboratory tests (18).

### Conclusion

Uveitis is a condition that can occur in emergency departments or primary care settings. It is important to recognize the symptoms and make an accurate diagnosis. It is important that primary care providers refer the patient to an ophthalmologist if uveitis is suspected. If the patient is taken to a center with symptoms associated with uveitis and the center does not have the capacity to adequately diagnose the complaint (ie, tonometer and cutting technology); the patient should be referred to a facility that can perform these tests. It is important to initiate treatment with topical corticosteroids and cycloplegic drugs when a diagnosis of uveitis is made. Since this can be a visually impaired condition, providers must ensure that patients can afford the prescribed treatment prior to discharge. If the patient cannot pay for the drugs, social services can provide patient care. Uveitis causes about 10% of blindness in the United States, so proper treatment and management is important. Uveitis treatment should be managed as a professional team of ophthalmologists, retina and uveitis specialists, nurses, and specially trained pharmacists, all working together to support the treatment of the uveitis patient and achieve the best possible outcome.

Comment [H43]: by

### References

- 1) Abad S, Seve P, Dhote R, Brezin AP. [Guidelines for the management of uveitis in internal medicine]. *Rev Med Interne*. 2009 Jun. 30(6):492-500.
- 2) Acharya NR, Tham VM, Esterberg E, Borkar DS, Parker JV, Vinoya AC, et al. Incidence and prevalence of uveitis: results from the Pacific Ocular Inflammation Study. *JAMA Ophthalmol*. 2013 Nov. 131 (11):1405-12.
- 3) Al-Dhibi HA, Al-Mahmood AM, Arevalo JF. A systematic approach to emergencies in uveitis. *Middle East Afr J Ophthalmol*. 2014 Jul-Sep. 21 (3):251-8.
- 4) Dunn JP. Uveitis. *Prim Care*. 2015 Sep. 42 (3):305-23.
- 5) Dunne JA, Travers JP. Topical steroids in anterior uveitis. *Trans Ophthalmol soc UK*. 1979. 99(4):481-4.

- 6) Foster CS, Alter G, DeBarge LR, Raizman MB, Crabb JL, Santos CI, et al. Efficacy and safety of rimexolone 1% ophthalmic suspension vs 1% prednisolone acetate in the treatment of uveitis. *Am J Ophthalmol*. 1996 Aug. 122(2):171-82.
- 7) Gritz DC, Wong IG. Incidence and prevalence of uveitis in Northern California; the Northern California Epidemiology of Uveitis Study. *Ophthalmology*. 2004 Mar. 111(3):491-500; discussion 500.
- 8) Lim LL, Smith JR, Rosenbaum JT. Retisert (Bausch & Lomb/Control Delivery Systems). *Curr Opin Investig Drugs*. 2005 Nov. 6(11):1159-67.
- 9) Logothetis HD, Leikin SM, Patrianakos T. Management of anterior segment trauma. *Dis Mon*. 2014 Jun. 60(6):247-53.
- 10) Lyon F, Gale RP, Lightman S. Recent developments in the treatment of uveitis: an update. *Expert Opin Investig Drugs*. 2009 May. 18(5):609-16.
- 11) McCannel CA, Holland GN, Helm CJ, Cornell PJ, Winston JV, Rimmer TG. Causes of uveitis in the general practice of ophthalmology. UCLA Community-Based Uveitis Study Group. *Am J Ophthalmol*. 1996 Jan. 121(1):35-46.
- 12) Mohammad DA, Sweet BV, Elnor SG. Retisert: is the new advance in treatment of uveitis a good one?. *Ann Pharmacother*. 2007 Mar. 41(3):449-54.
- 13) Mozayan A, Farah S. Acute anterior uveitis following intravitreal injection of bevacizumab. *Ophthalmic Surg Lasers Imaging Retina*. 2013 Jan-Feb. 44(1):25-7.
- 14) Nishimoto JY. Iritis. How to recognize and manage a potentially sight-threatening disease. *Postgrad Med*. 1996 Feb. 99(2):255-7, 261-2.
- 15) Rodriguez A, Calonge M, Pedroza-Seres M, Akova YA, Messmer EM, D'Amico DJ, et al. Referral patterns of uveitis in a tertiary eye care center. *Arch Ophthalmol*. 1996 May. 114(5):593-9.
- 16) Syed BA, Kumar S, Bielory L. Current options and emerging therapies for anterior ocular inflammatory disease. *Curr Opin Allergy Clin Immunol*. 2014 Oct. 14(5):485-9.
- 17) Wirbelauer C. Management of the red eye for the primary care physician. *Am J Med*. 2006 Apr. 119(4):302-6.
- 18) Yawn BP, Wollan PC, St Sauver JL, Butterfield LC. Herpes zoster eye complications: rates and trends. *Mayo Clin Proc*. 2013 Jun. 88(6):562-70.