

ASSESSMENT OF WEIGHT REDUCTION POTENTIAL AND EFFECT OF ETHANOLIC LEAF EXTRACT OF LEMON GRASS (*CYMBOPOGON CITRATUS*) ON LUNG HISTOLOGY OF TREATED WISTAR RATS

Abstract

The aim of this study was to evaluate the effect of ethanolic leaf lemongrass on body weight and lung histology of treated wistar rats. Freshly harvested leaves of lemongrass were dried at room temperature and afterwards ground into fine powder. 250 g of powdered plant sample was suspended in 1000 mL of 95% ethanol for 72 hours and agitated thrice daily. The resulting extract was concentrated. Twenty adult male wistar rats were divided into four groups of five rats and their initial weights taken. **Group I** was the Normal Control, **Group II** was administered with 100 mg/kg b.w of ethanolic extract of lemongrass, **Group III** was administered with 300 mg/kg b.w of ethanolic extract of lemongrass, and **Group IV** was administered with 600 mg/kg b.w of ethanolic extract of lemongrass. Treatment lasted for 14 days after which the final weight of animals was taken and subsequently sacrificed. The lungs were harvested for histological examination which was carried out using standard procedures. Oral administration of ethanolic leaf extract of lemongrass significantly ($P < 0.05$) decreased body weight of treated rats compared to their untreated counterpart. The histopathological report showed a mild to moderate congestion of blood vessels and inflammatory cells around the bronchioles in the treated groups when compared to control. In conclusion, although extract of lemongrass had demonstrated its potential to reduce body weight, it also showed the capacity to inflict harm to the lungs.

Keywords: Lemongrass; Lung; Histology; Body weight

Introduction

The lungs are the main organs of the respiratory system. It is saddled with the responsibility of transferring oxygen from the environment to bloodstream. The lungs wield the power to take over 6 million breaths per year. The lungs are situated in the chest, behind the ribcage on either sides of the heart. They are roughly conical in shape characterized by a rounded point at the apex and a flatter base where they meet the diaphragm. The lungs are susceptible to microbial infection primarily owing to its exposure to air drawn from the environment with its

characteristic plethora of microorganisms many of which are pathogenic and account for lung infections which is responsible for over 6% of the global burden of diseases (Mizgerd, 2006). It is worthy to note that microbes associated with lung infection are increasingly resistant to conventional antibiotics which in turn justifies the need for trials on medicinal plants with broad spectrum antimicrobial potential (Cunha, 2001).

Lemon grass botanically known as *Cymbopogon citratus* is an aromatic perennial tall grass. It is characterized by stunted underground stems with ringed segments, coarse green slightly leathery leaves (Carlin et al., 1986). It is widely distributed in the tropical and sub-tropical countries. It reportedly originates from Asia, Africa and Americas (Francisco *et al.*, 2011). The plant is a repository of assorted bioactive compounds which are critical in the management of diverse human ailments. It has demonstrated impressive activity against many pathogenic microbes known to inhabit the gastrointestinal tract (Figueirinha et al., 2008). Traditionally, tea from lemon grass is a popular antiseptic, antifever, antidyspeptic, diuretic, tranquilizer and anti-inflammatory agent (Viana et al., 2000). Thus, it is imperative to investigate its safety on the lungs.

Comment [L1]: citations are not listed in the bibliography

MATERIALS AND METHODS

Collection and Processing of Plant Material

Leaves of *Cymbopogon citratus* were harvested from a local farm, and washed in running tap water to remove dirt, they were subsequently authenticated in the herbarium unit of the Department of Botany, Chukwuemeka Odumegwu Ojukwu University, Uli Campus, Anambra State. The leaves were shade dried, ground and the resulting powder sieved and stored in an air tight container.

Preparation of Extract

Exactly 250 g of powdered plant sample was suspended in 1000 mL of 95% ethanol for 72 hours and agitated thrice daily. It was then filtered using a muslin cloth and further filtration with Whatman No 1 filter paper. The filtrate was concentrated (Attar and Abu, 2013).

Animal

Twenty (20) adult male wistar rats weighing 120-180 g were obtained from the animal house of the Department of Anatomy, Chukwuemeka Odumegwu Ojukwu University and were allowed to acclimatize for two weeks, after which they were randomly divided into four groups of five animals each.

Comment [L2]: describe the determination of acclimatization for 2 weeks!

Comment [L3]: Please explain, how long the treatment takes.

Acute Toxicity Test

Acute toxicity test was carried out in according to the method of Lorke [16]. At the initial phase, Nine adult male wistar rats were divided into three rats per group and were orally administered with 10 mg, 100 mg and 1000 mg of the extract per kg body weight respectively in separate experiment. They were observed for 24 hours for signs of toxicity in the absence of which the second phase was commenced and constituted of 3 rats which were divided into 3 groups of 1 rat per group and was administered with 1600, 2,900 and 5,000 mg/kg bw of the extract. The LD₅₀ was determined using the results obtained from the final phase as the square root of the product of the lowest lethal dose and the highest non-lethal dose.

Comment [L4]: Citation more clearly by adding the year!

Comment [L5]: what is this mean?

Comment [L6]: State clearly the dose of LD₅₀!

Animal Grouping

Group I was administered with 2 mL of distilled water rat chow.

Group II received 100mg/kg of ethanolic leaf extract of *Cymbopogon citratus*

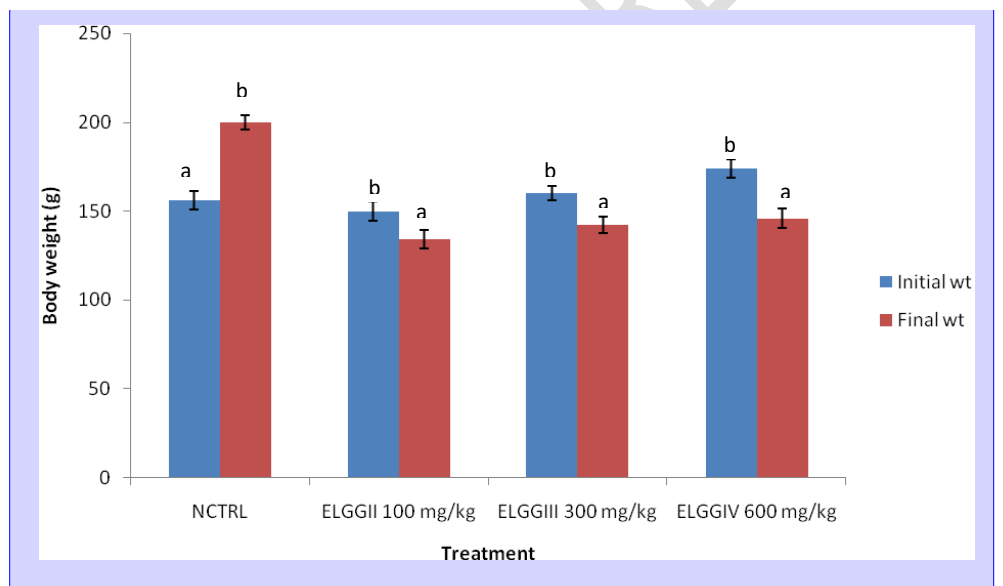
Group III received 300mg/kg of ethanolic leaf extract of *Cymbopogon citratus*

Group IV received 600mg/kg of ethanolic leaf extract of *Cymbopogon citratus*

Histological Studies

The liver tissue was dissected out and fixed in 10% formalin, dehydrated in gradual ethanol 80%, cleared in xylene and embedded in paraffin. Sections were prepared and then stained with hematoxylin and eosin (H and E) dye for photomicroscopic observation, including cell necrosis and fatty change.

RESULT AND DISCUSSION



Comment [L7]: Describe the meaning of a and b. Add statistical tests used on materials and methods

Figure 1: Effect of ethanolic leaf extract of *Cymbopogon citratus* on the body weight

Hint: NCTRL [Normal control], ELG [Extract of Lemon Grass], GI-IV [Group I-IV]

Comment [L8]: How to measure body weight? add in materials and methods!

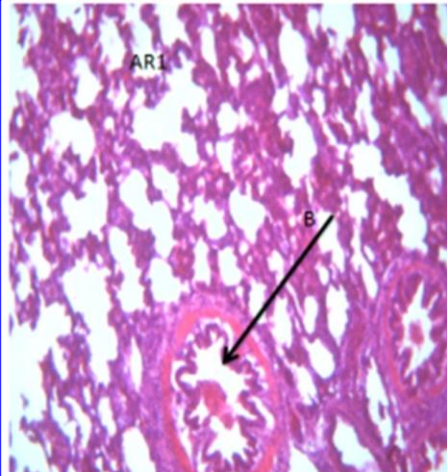


Plate I: Normal control (×100)

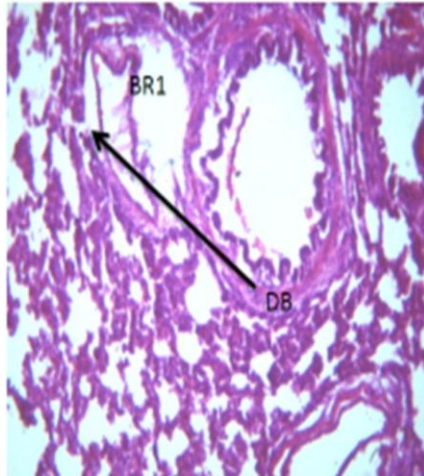


Plate II: 100 mg/kg of *C. citratus* extract (×100)

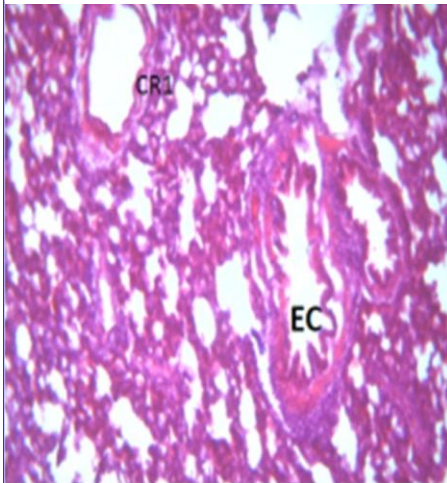


Plate III: 300 mg/kg of *C. citratus* extract (×100)

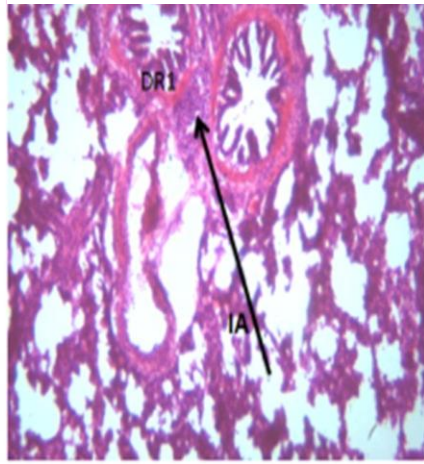


Plate IV: 600 mg/kg of *C. citratus* extract (×100)

Plate I: Photomicrograph of lung of untreated rats (control group) showing normal lung tissue with a well circumscribed alveoli, endothelial cells and bronchioles. **Plate II:** Photomicrograph of lung of rats administered with 100 mg/kg of ethanolic leaf extract of *C. citratus* showing moderate inflammatory aggregate, congestion of blood vessel. **Plate III:** Photomicrograph of rats administered with 300 mg/kg of extract of *C. citratus* showing non-distended appearance of the endothelial cells. **Plate IV:** Photomicrograph of lungs of rats administered with 600 mg/kg of extract of *C. citratus* showing moderate inflammatory aggregate around the bronchioles and mild congestion of the blood vessels.

Comment [L9]: Describe the meaning of AR1, B, BR1, DB, CR1, EC, DR1, IA, and arrows!

The lung is an essential anatomical-physiological organ known for its respiratory and surfactant functions (Deepak and Hari, 2013). The use of plants in the management and prevention of diseases has been a practice among people living in Africa. *C. citratus* (lemongrass) is a medicinal plant known for its numerous medical applications. Findings from this study revealed that oral administration of ethanolic extract of *C. citratus* ($p < 0.05$) decreased body weight compared to the control. The reduction in weight of rats administered with extract could be attributed to inhibition of the satiety centers in the hypothalamus resulting in alterations of metabolic balance and energy homeostasis. The outcome of this study is consistent with the finding of Rojas-Armas *et al.*, (2020) who reported a significant reduction in the bodyweight following administration of essential oil of lemongrass on DMBA-induced breast cancer. Similarly, findings Tiwari *et al.*, (2018) also reported a significant increase in the bodyweight following lemongrass oil on broiler chicks. The histopathological report showed a mild to moderate congestion of blood vessels and inflammatory cells around the bronchioles in the treated groups when compared to control. This could be attributed to the presence of some toxic phytoconstituents in the lemongrass. This study contradicts the report of Costa *et al.*, (2011) who reported no changes in the lungs histology following administration of the lemongrass oil.

REFERENCES

Ahmed, K. (2016). Assessment of metals in cosmetic commonly used in Saudi Arabia. *Environmental Monitoring Assessment*, 18 (8): 553.

Al-Attar, A.M. Abu I.M. (2013). Effect of tea (*Camellia sinensis*) and olive (*Olea europaea* L.) leaves extracts on male mice exposed to diazinon. *BioMedical Research Institute*, 1-6.

Carlin, E, Contar, J and Silva-Filho, D.P.(1986). Pharmacology of Lemon grass (*Cymbopogon citratus* leaves, stapf) effects of teas prepared from leaves on laboratory animals *Journal of Ethnopharmacology*, 17:37-64

Costa, C. A. R. A, Bidinotto, L. T, Takahira, R.K, Salvadori, D. M. F, Barbisan, L. F, and Costa, M. (2011). Cholesterol reduction and lack of genotoxic or toxic effects in mice after repeated 21-day oral intake of lemongrass (*Cymbopogon citratus*) essential oil. *Food and Chemical Toxicology*, 49(9), 2268–2272.

Cunha, B.A. (2001). Effective antibiotic resistance control strategies. *Lancet*, 357:1307-1308.

Deepak, J, Raju, K.P and Hari K. (2013). Non-respiratory functions of the lung. *Continuing Education in Anaesthesia Critical Care & Pain*, 13(3):98–102.

Francisco, V, Costa, G, Figueirinha, G, Marques, C.X, Pereira, P, Miguel, B, Teresa, M. (2013). Anti-inflammatory activity of *Cymbopogon citratus* leaves infusion via proteasome and nuclear factor- κ B pathway inhibition: contribution of chlorogenic acid. *Journal of Ethnopharmacology*, 148, 126-134.

Lorke, D. (1983). A new approach to practical acute toxicity testing. *Archives of Toxicology*, 54:275–87.

Mizgerd, J.P. (2006). Lung infection--a public health priority. *PLoS medicine*, 3(2):76.

Rojas-Armas, J. P, Arroyo-Acevedo, J. L, Palomino-Pacheco, M, Herrera-Calderón, O, Ortiz-Sánchez, J.M, Rojas-Armas, A, Calva, J, Castro-Luna, A, and Hilario-Vargas, J.(2020). The essential oil of *Cymbopogon citratus* stapt and carvacrol: An approach of the antitumor effect on 7, 12-dimethylbenz-[α]-anthracene (DMBA) induced breast cancers in female rats. *Molecules*, 25(14):3284.

Tiwari, M, Jha, P, Sah, B, Kunwar, G, and Jha, A. (2018). Performance of lemongrass (*Cymbopogon citrates*) oil as growth promoter in broiler. *Bangladesh Journal of Animal Science*, 47(2): 85–91.

Viana, G, Vale T, and Matos, F. (2000). Antinociceptive effect of the essential oil from *Cymbopogon citratus* in mice. *Journal of Ethnopharmacology*, 70 (3):323-327.

Comment [L10]: Some references used, the year is too old, replace it with a newer one!

Comment [L11]: This reference is not in the citation.