

# Article

*by* Sandy Ardiansyah

---

**Submission date:** 24-Jan-2022 03:26PM (UTC+0800)

**Submission ID:** 1683358107

**File name:** Ms\_AJRDES\_82947.docx (841.32K)

**Word count:** 1707

**Character count:** 9801

## Case study

### Scrotal Buschke-Löwenstein tumor in a teenager: A case Report.

#### Abstract:

Buschke-Löwenstein tumor is an uncommon pathology, transmitted mainly by sexual route. It is more encountered in young adult males. Its occurrence in children and adolescents should eliminate a notion of sexual abuse. We report a case of Buschke-Löwenstein tumor of scrotal localization in a 13-year-old teenager. He presented with a scrotal confluent nodules. Clinical examination showed a large oozing cauliflower painful mass invading the entire scrotum. Inguinal lymphadenopathy was also found. The analysis of the oozing fluid shows the presence of numerous gram negative bacilli. The microscopic examination revealed an acanthotic papillomatous epidermis with koilocytosis, associated with a dense, fibrous and inflammatory dermis. The patient underwent complete excision of the tumour and the postoperative course was simple. Buschke-Löwenstein tumor is uncommon in teenagers. Nevertheless its clinical and histological presentation is typical.

#### Introduction

Buschke-Löwenstein tumor or giant condyloma acuminata is a rare nosological entity first described in 1896 by Buschke and clearly defined in 1926 by Löwenstein(1,2). It is frequently classified as a well-differentiated variant of squamous cell carcinoma(3). Others consider it as an intermediate form between the banal condyloma acuminata and squamous cell carcinoma (4,5). It is a disease almost exclusively caused by the Human papillomavirus (HPV), in particular serotypes 6 and 11(4,6). It is characterized histologically by pseudoepitheliomatous acanthosis, papillomatosis and koilocytosis (3,5-7). It is an aggressive tumor that infiltrates and pushes back adjacent tissues (8). In men, it is mainly found in the penis and the anoperineal region, while the scrotal location is less frequent(3,4,9-11). It is also rarer in children and adolescents, and in these cases the notion of sexual abuse must always be eliminated (12,13). We report a case of giant condyloma acuminata in a teenager.

#### Presentation of the case

A 13-year-old male patient, presented with a scrotal mass that has been evolving for several months. The onset of the disease is said to be one year ago, with the appearance of isolated little itchy papules in the scrotum, for which the patient received antibiotic therapy which had no effect on these lesions. The course was marked by the proliferation of these papules, then the formation of nodules, then their confluence until the formation of the mass which motivated the consultation.

Clinical examination revealed a large, budding cauliflower mass made up of numerous confluent nodules of varying size, oozing, invading the entire scrotum, without involvement of the penis. It measures 20 cm long axis (figure 1). It was very painful on palpation and has a fairly firm consistency. Palpation of the inguinal lymph node areas revealed lymphadenopathy. The remainder of the physical examination is unremarkable.

Cytobacteriological examination of the oozing fluid revealed the presence of a few polymorphonuclear cells and a few gram-negative bacilli. Culture showed *Pseudomonas fluorescens* sensitive to, inter alia, aztreonam. The HIV serology was negative.

Testicular ultrasound showed a heterogeneous, hypervascularized budding tissue mass with necrotic components, infiltrating the bursae with extension into the soft pubic tissues, enveloping the

hypotrophic and invaded testes. It also showed a bilateral multi-septal hydrocele as well as multiple superficial inguinal and femoral lymphadenopathy.

The biopsy performed showed an acanthotic, papillomatous epidermis (Figure 2a) with extensive koilocytosis (Figure 2b). The dermis is dense fibrous, richly infiltrated with plasma cells, lymphocytes and eosinophils (Figure 2c). There are many congestive blood vessels there.

All these elements allowed us to make the diagnosis of a giant Buscke-Löwenstein tumor. The patient was transferred to a urology department for adequate surgical management.

### **Discussion**

Buschke-Löwenstein tumor is a condition that develops primarily following infection with HPV serotypes 6 and 11 (9) although a few cases without this virus have been described (14). It is quite often associated with human immunodeficiency virus (HIV) infection (9,10) although this was not the case in our patient.

Our patient is male, which is consistent with most of the published work on the subject, which shows a clear predominance of men among affected patients. The sex ratio is around 2.7: 1 (5). This difference could be explained in part by the fact that women would consult much more frequently than men, especially in gynecology where HPV infection would be detected more quickly and therefore more quickly taken care of (2).

The patient is 13 years old. The mean age of onset of this tumor is 43.9 years (5). It is considered a sexually transmitted disease (1, 6, 10, 11,14) which could explain its high prevalence in young adults. However, the notion of sexual abuse, which was not found in our patient, should always be suspected in young adolescents and children (5,13). It should be noted that HPV can be transmitted asexually in these patients by self-inoculation or by heteroinoculation via soiled objects (13,14)

The tumor is of scrotal location in our work. This is an infrequent location given that the majority of studies report a penile or anoperineal location (12,15–18). A few cases of extragenital localization have been described(19).

In our case, it appears as a confluence of nodules of variable size giving a cauliflower or bunch of grape appearance. This description is similar to most of those found in the literature (2,7–9, 11,18). The lesion was oozing, which is a characteristic quite frequently found as well. This is caused by the presence of fistulas which promote bacterial superinfection as shown by cytobacteriological analysis of the fluid collected (1, 3,7). This bacterial superinfection can also explain the presence of inguinal lymphadenopathy.

Pathological examination shows acanthotic, papillomatous epithelium with koilocytosis. The dermis is dense fibrous and is the site of a diffuse polymorphic inflammatory infiltrate made up of lymphocytes, plasma cells and eosinophils. The basement membrane is intact. This description is quite typical for this tumor and agrees with the data in the literature (2, 6, 8, 10, 15,18).

The main differential diagnosis is squamous cell carcinoma, which will present with numerous atypias and mitoses, but above all with an invasion of the basement membrane (2).

The management of this tumor is complex, particularly because of its size and the depth of infiltration into adjacent tissues (20). Our patient was transferred to a urology department for surgical management, which is the gold standard for giant condyloma acuminata (2,3). He received antibiotherapy before complete excision of the mass. Postoperative course was simple. He left hospital one week after the surgery. Other treatment alternatives are described, including

chemotherapy, radiotherapy, topical treatments (podophyllin), and electrocaogulation among others (2, 4,5), with varying success rates depending on the authors.

The disease can progress to recurrence in 60 to 66% of cases despite complete excision or to cancerization promoted by radiotherapy treatment (2, 4,11).

### **Conclusion**

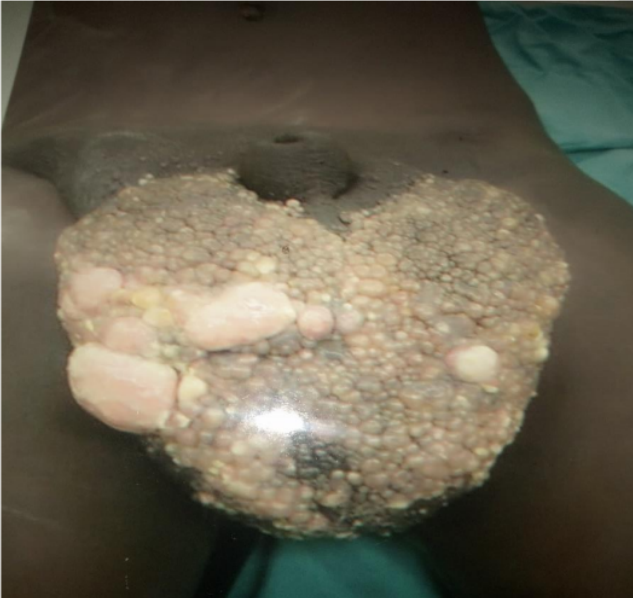We reported a case of Buschke-Löwenstein tumor in a 13-year-old boy. This is a rare tumor caused by HPV. The clinical and histological presentations are characteristic. Because of its high potential for recurrence and malignant transformation, the treatment of choice remains surgical excision.

### **References**

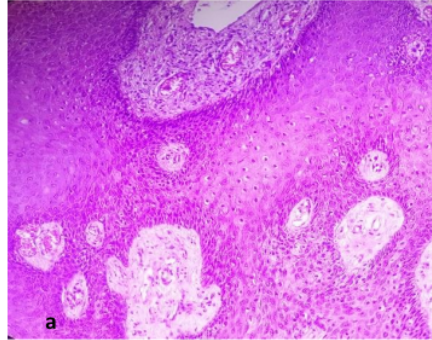
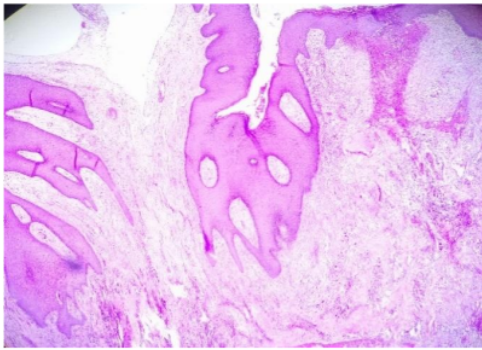
1. Lahmidani N, Bahja S, Sidi Adil I, El Abkari M. Buschke-Löwenstein Tumor: About an Observation and Review of Literature. *Arch Clin Med Case Rep.* 2021;05:1015-18.
2. Sarr A, Thiam A, Sow O, Ondo CZ, Sine B, Ndiaye M, et al. Les tumeurs de Buschke-Löwenstein à propos de 8 cas. *PAMJ Clin MedJ.* 2020;4.
3. Kim HG, Kesey JE, Griswold JA. Giant anorectal condyloma acuminatum of Buschke-Löwenstein presents difficult management decisions. *J Surg Case Rep.* 1 avr 2018;2018.
4. Pineda-Murillo J, Lugo-García JA, Martínez-Carrillo G, Torres-Aguilar J, Viveros-Contreras C, Schettino-Peredo MV. Buschke-Löwenstein tumor of the penis. *Afr J Urol.* déc 2019;25:9.
5. Nieves-Condoy JF, Acuña-Pinzón CL, Chavarría-Chavira JL, Hinojosa-Ugarte D, Zúñiga-Vázquez LA. Giant Condyloma Acuminata (Buschke-Löwenstein Tumor): Review of an Unusual Disease and Difficult to Manage. *Infect Dis Obstet Gynecol.* 30 juin 2021;2021:1-5.
6. Irshad U, Puckett Y. Giant Condylomata Acuminata Of Buschke And Lowenstein. In: *StatPearls.* Treasure Island (FL): StatPearls Publishing; 2021
7. Sara Elloudi KE, Hanane Baybay SD, Fatima Zahra Mernissi SE, H. Abid ZB, M. El Yousfi NL, A. Ibrahimi NA, et al. Bushke-Löwenstein Tumor Transforming To an Aggressive Squamous Cell Carcinoma: A Case Report with Literature Review. *Saudi J Med Pharm Sci.* 30 nov 2019;05:1015-8.
8. Ndiaye M, Sow O. Buschke-Löwenstein tumor with peno-inguino-scrotal location. *PAMJ Clin Med.* 2020;4.
9. Ibrahimi A, Ziani I. Penile Buschke-Löwenstein tumor. *Pan Afr Med J.* 2020
10. Hasbi S. Buschke-Löwenstein tumor with anoperineal location. *J Afr Hepato-Gastroenterology.* Sep 2017;11:128-9.
11. Akdag O, Yildiran G. Malign Differentiation of a Large Buschke Loewenstein Tumor in Penis. *Surg J.* avr 2018;04:53-4.

12. Khullar G, Narang T, De D, Nahar Saikia U, Dogra S, Handa S. Recalcitrant giant condyloma acuminatum treated successfully with a novel combination of *Mycobacterium indicus pranii* immunotherapy and acitretin. *Int J STD AIDS*. oct 2017;28:1155-7.
13. Costa-Silva M, Fernandes I, Rodrigues AG, Lisboa C. Anogenital warts in pediatric population. *An Bras Dermatol*. oct 2017;92:675-81.
14. Lepekhova A, Dunaeva E, Teplyuk N, Vertieva E. A rare case of Buschke–Löwenstein tumor in HPV-negative patient. *Dermatol Rep*. 24 sept 2020;12: 52-53.
15. Patel R, Kaloucava S. A case of penile Buschke-Lowenstein tumor in a developing country. *Clin Case Rep*. mars 2017;5:257-9.
16. El Khoury A, Jensen JC, Pacioles T. Neoadjuvant chemotherapy and penile conservation in the management of Buschke – Lowenstein tumor, a case report. *Urol Case Rep*. mars 2020;29:101.
17. El Bessi M, Dougaz W, Jones M, Jerraya H, Dziri C. A Giant Anorectal Condyloma Is Not Synonym of Malignancy. *J Gastrointest Cancer*. déc 2019;50:1026-8.
18. Bazouti S, Zizi N, Dikhaye S. Perianal giant condyloma Acuminatum-Buschke-Löwenstein tumor. *Presse Médicale*. mai 2019;48:584-5.
19. Hsu T, Nahmias ZP, Rosman IS, Sheinbein D. Extragenital condyloma acuminatum in the left axillary vault. *JAAD Case Rep*. oct 2018;4:947-9.
20. Purzycka-Bohdan D, Szczerkowska-Dobosz A, Swiatecka-Czaj J, Peksa R, Urban M, Szczypior M, et al. Buschke-Löwenstein tumour associated with low-risk human papillomavirus genotypes successfully treated surgically. *Adv Dermatol Allergol*. 2019;36:112-4.

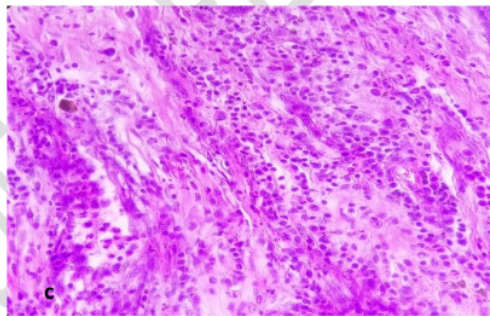
**Figures**



**Figure 1:** voluminous cauliflower-like budding mass made up of numerous confluent nodules of variable size, oozing, invading the entire scrotum, without affecting the penis. It measures almost 20 cm long axis.



b



c

**Figure 2:** Pathological examination. a: Acanthotic and papillomatous epidermis (HE, x10). b: Numerous koilocytes visible, as well as congestive blood vessels in the superficial dermis (HE, x20). c: Diffuse polymorphic inflammatory infiltrate made up of lymphocytes, plasma cells, and eosinophils (HE, x40).

# Article

---

## ORIGINALITY REPORT

---

5%

SIMILARITY INDEX

5%

INTERNET SOURCES

3%

PUBLICATIONS

%

STUDENT PAPERS

---

## PRIMARY SOURCES

---

- |   |   |    |
|---|---|----|
| 1 | Wyatt, J.K.. "Verrucous carcinoma of urinary bladder", Urology, 198007<br>Publication   | 1% |
| 2 | <a href="http://www.urotoday.com">www.urotoday.com</a><br>Internet Source   | 1% |
| 3 | Anthony El Khoury, James C. Jensen, Tony Pacioles. "Neoadjuvant chemotherapy and penile conservation in the management of Buschke – Lowenstein tumor, a case report", Urology Case Reports, 2020<br>Publication | 1% |
| 4 | <a href="http://e-journal.unair.ac.id">e-journal.unair.ac.id</a><br>Internet Source   | 1% |
| 5 | <a href="http://www.gavinpublishers.com">www.gavinpublishers.com</a><br>Internet Source   | 1% |
| 6 | <a href="http://www.omicsonline.org">www.omicsonline.org</a><br>Internet Source   | 1% |
| 7 | <a href="http://www.pagepress.org">www.pagepress.org</a><br>Internet Source   | 1% |
-

---

Exclude quotes      On

Exclude matches      Off

Exclude bibliography      On