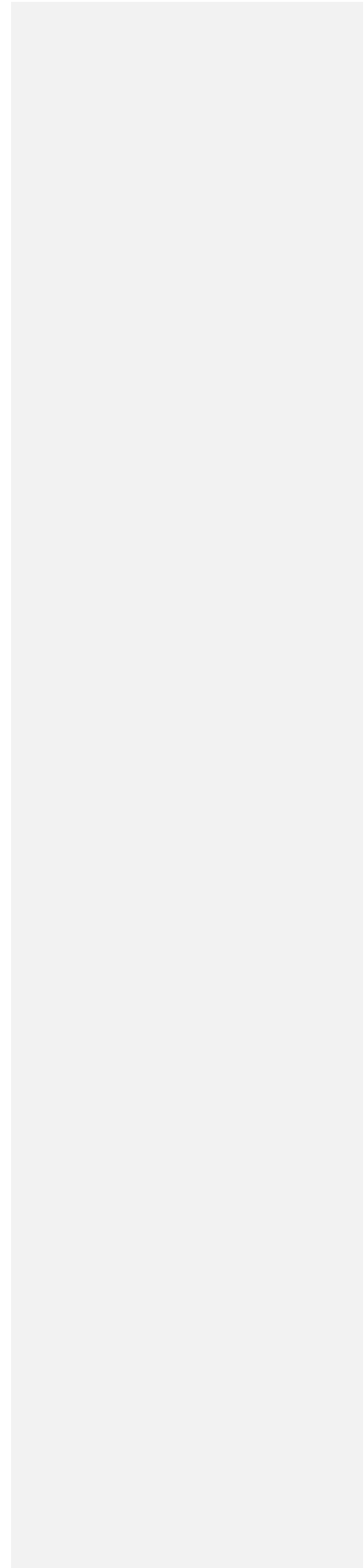


Case study

**Henoch-Schonlein Purpura Successfully Treated with Oral Steroids: A Case
Report**

UNDER PEER REVIEW



Abstract

A 38-years old male patient presented to the clinic with complaints of severe pain in the center of the abdomen. Along with that, he had a severe rash on his skin and a documented history of visiting many hospitals for the same reason. He was diagnosed with irritable bowel syndrome (IBS) previously.

The day before presenting to the clinic, the patient went to the Emergency Department for the same complaints. The staff at the ED had investigated the cause, including a CT abdomen with contrast, but the reports had been all clear. He had mildly raised serum creatinine at that time.

According to the patient, the abdominal pain was colicky in nature. There were no associated complaints of nausea, vomiting, or GI bleeding, but did have an upper respiratory tract infection three weeks ago, after which he had started experiencing these symptoms. His infection was treated with oral antibiotics and was soon got resolved.

The patient had severe tenderness in his abdominal region. The rash was extensive, reddish, raised, and purpuric in nature and had spread all over his lower limbs and hips on both sides. The upper limbs were also involved up to the forearms.

All the lab investigations conducted on the patient were normal, including CBC, Creatinine, Serum C3, C4, and the rheumatoid factor. CRP was found to be elevated and positive occult blood was seen in the stool of the patient.

The combination of the above medical symptoms and investigations revealed that the patient was suffering from abdominal angina. The symptoms had a classic presentation pattern: positive occult blood in stool, a purpuric rash, abdominal pain, and renal involvement that was preceded by a documented case of upper respiratory tract infection (URTI).

Comment [r1]: Struct like introduction; case report; conclusion

Comment [r2]: Abdominal several pain and severe rash

Comment [r3]: remove

Comment [r4]: medical history? So it should be first

Comment [r5]: reformulate in last paragraph. It is confuse – it must have chronology
38 years old man with abdominal pain, severe rash, along XXX days went to emergency. Abdominal pain was...and no associated symptoms. Last day we has at emergency and only had raised serum creatinine..

Comment [r6]: It is about this episode and not some different

Later, the patient was found to have all findings consistent with immune-mediated IgA vasculitis (Henoch Schonlein Purpura) and was then treated accordingly.

The above-mentioned case was an interesting presentation: the condition is not often presented to the hospital with such clear manifestations, leading to an absolute diagnosis. The following sections of this case study will explore how the patient was diagnosed, treated, and managed accordingly to save his life.

Keywords: Henoch Schonlein Purpura, irritable bowel syndrome, GI bleeding, abdominal angina.

UNDER PEER REVIEW

INTRODUCTION

Abdominal angina is a type of pain related to the gastrointestinal tract that is seen to occur mostly after meals. This form of pain occurs when there is an insufficient supply of blood to the colon and it is unable to meet the demands of the rest of the viscera of the GI tract. Abdominal angina is most commonly seen to occur in cases of mesenteric occlusive vascular disease.^[1]

Abdominal angina gets its name from the intermittent claudication that occurs in similar cases of myocardial angina or vascular disease.^[2] However, abdominal angina is a rare phenomenon, both in the United States as well as elsewhere in the world. This is because most cases of mesenteric occlusive disease get diagnosed early and so urgent evaluation and timely treatment ensure that no further complications develop in the patient.^[3]

However, since there were obvious signs of what the patient was suffering from, it was later on that it was concluded that abdominal angina might just be a part of his presenting symptoms. The spectrum of the symptoms were more than indicated by the diagnosis and that is why the patient underwent further examination and investigation to gain a more accurate indication of the condition that he was suffering from.

Later on, the presence of abnormally elevated protein levels in the patient's blood pointed to a condition similar to henoch Schonlein Purpura, but the normalcy of the rheumatoid factor and C4 tests lead to the exclusion of this diagnosis as well. Another trip to the dermatologist helped in confirm the diagnosis as Henoch Schonlein Purpura or IgA vasculitis.

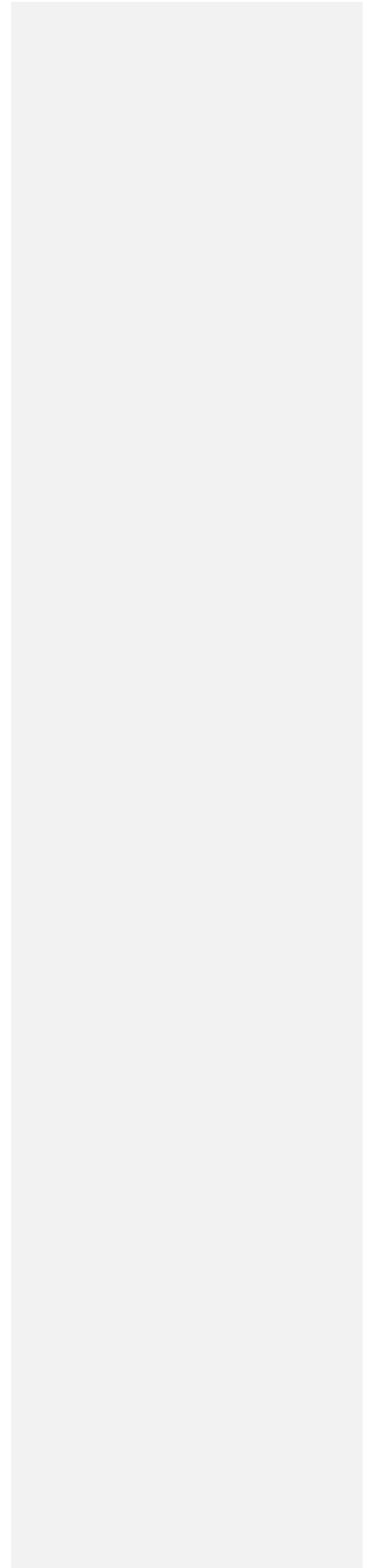
Henoch Schonlein Purpura is an IgA-mediated immune vasculitis that involves the small vessels of the gastrointestinal tract, kidneys, joints, skin, respiratory system and lungs. The presentation

Comment [r7]: Confuse!!
Definition; epidemiology, characteristics,
....

Comment [r8]: Reformulate
Abdominal angina is an abdominal pain that
occurs after meals related with insufficient
supply of blood and

of the patient was considered to be classic of this condition which allowed for timely diagnosis and appropriate management to avoid complications in the long run.^[4]

UNDER PEER REVIEW



CASE STUDY

A 38-year old male patient, who appeared to be quite anxious and restless, presented to the clinic. This patient complained of having severe central abdominal pain and a skin rash. He had been to many hospitals and clinics, and nearly all of them had failed to diagnose what was wrong with him, despite there being obvious signs of illness, owing to his deteriorating state.

Earlier, the patient was diagnosed with irritable bowel syndrome (IBS). The day before the patient presented, he had gone to the Emergency Department for the same complaints. The ED had promptly ordered lab investigations, along with a CT abdomen with contrast to rule out possible warning signs that might have developed insidiously inside the patient. The CT Scan was completely normal. The same applies to the lab reports, except for a small rise in the levels of serum creatinine.

Comment [r9]: The day before he went to emergency and....

Examination

When the patient was thoroughly examined, the nature of his pain turned out to be colicky. However, the pain was not associated with any kind of nausea, vomiting, GI loss, or bleeding. The patient reported suffering from an upper respiratory tract infection about three weeks ago, for which he was treated successfully with oral antibiotics.

The physical examination of the patient revealed that he was tearful and anxious because of his condition. He had obvious signs of central abdominal tenderness and there was an extensive rash which was raised, reddish and purpuric, across both the lower limbs and hips of the patient. The upper limb was also involved, but only up to the forearms of the patient.

The following is an image of the patient's rash, which has been used with the patient's consent.

Image 1

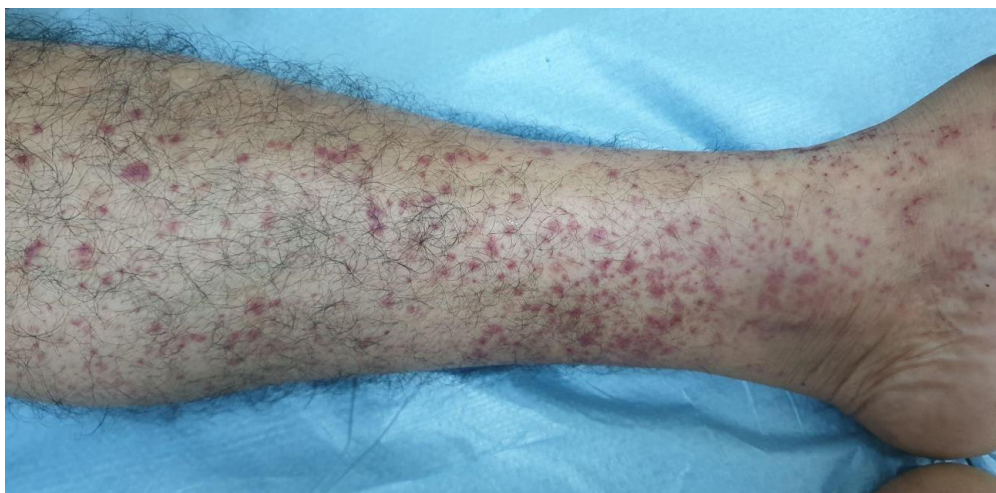

Image 2

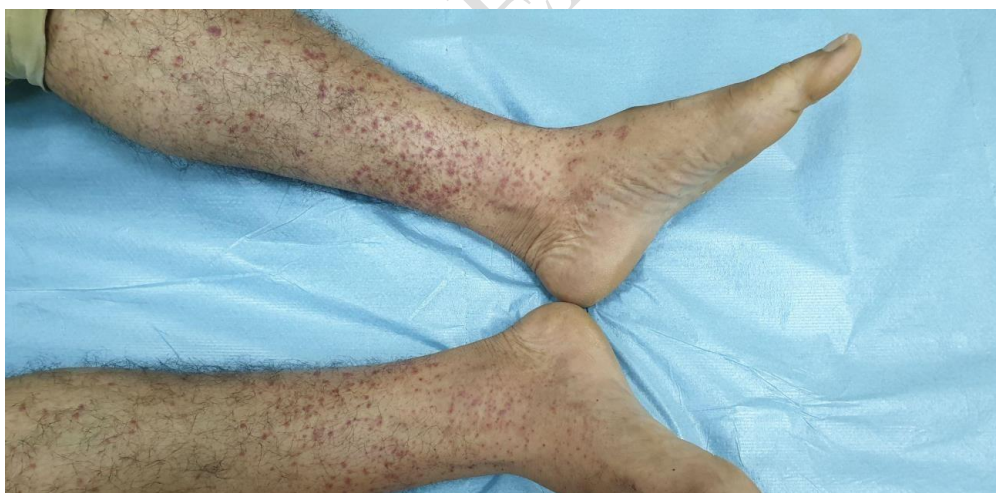

Image 1 and 2. Purpuric, reddish-purple rash involving the lower limbs of the patient.

Investigations

At the clinic, the patient again had some of investigations done for a better picture of his condition. Here is a summary of what was found:

CBC	Normal
Creatinine	Abnormal in the earlier reports but had normalized.
CRP	Mildly elevated
Serum C3 and C4	Normal levels
Rheumatoid Factor	Normal
Other Important Findings	Positive occult blood in stool

Diagnosis and Management

From the above reports, it was clear that the patient was suffering from abdominal angina as he had the classic triad of purpuric rash, abdominal pain, and renal involvement, all of which had begun after the patient had an upper respiratory tract infection.

It was also suspected as an ideal differential that the patient might go on to develop Henoch Schonlein Purpura (IgA Vasculitis) with cryoglobulinemia. However, since this profile was not being favored due to the normal rheumatoid factor and C4 levels, the possibility was excluded.

As a final resort, the patient was sent to the dermatology clinic for another opinion and to have a skin biopsy. The biopsy without immunofluorescence supported a diagnosis of IgA vasculitis and so he was treated accordingly.

This biopsy led to the patient being administered a course of daily oral prednisolone (20 mg, PO) along with oral PPI for his abdominal symptoms. The response of the patient to steroids was dramatic. His rash regressed spontaneously and, within 48 hours of starting this treatment, the patient's abdominal pain had completely resolved as well.

After this, a skin biopsy was taken without immunofluorescence again, and the following image, used with consent, was visible at that time

UNDER PEER REVIEW

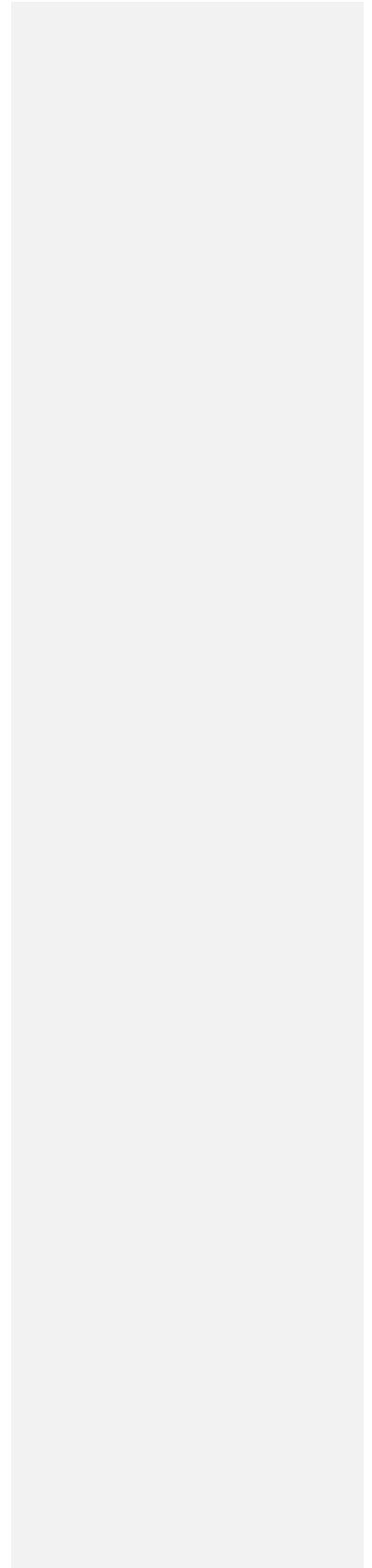
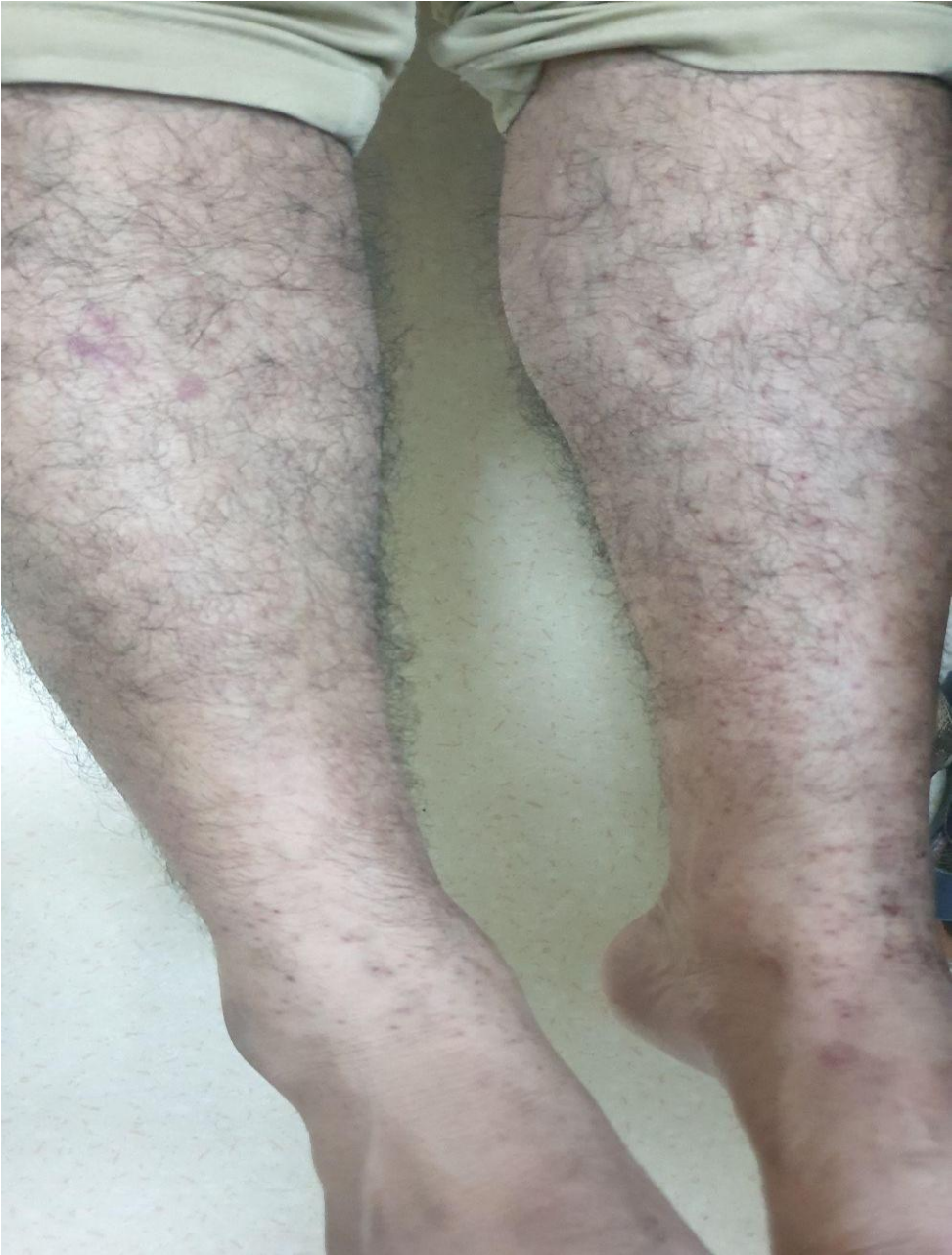


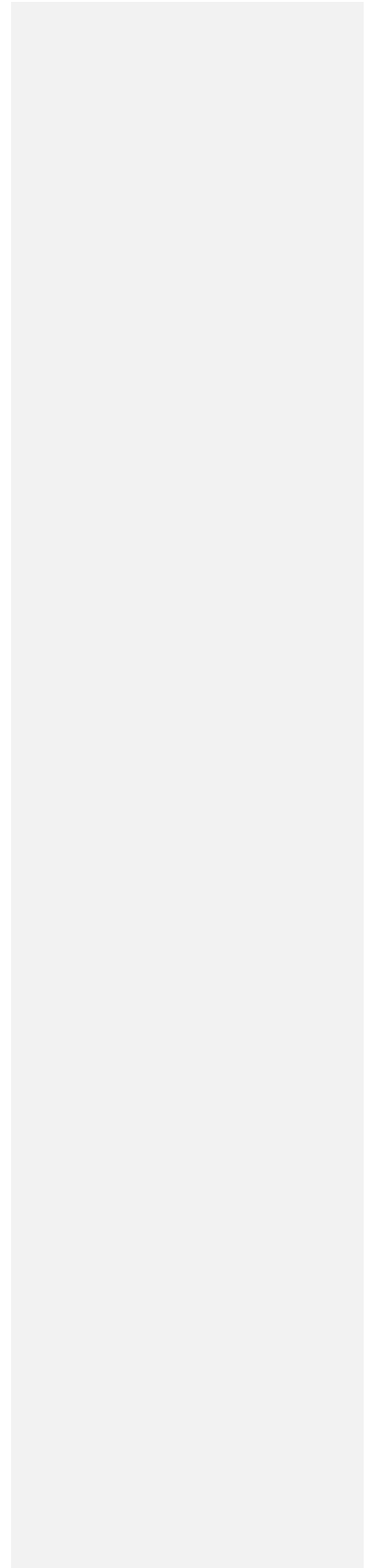
Image 3. A skin biopsy without immunofluorescence



There is an obvious resolution of the rash when compared with the patient's earlier images. Immunofluorescence was not ordered for this patient because there was no fresh rash present at the time of biopsy, so it was omitted to avoid confusion.

This is how this case was managed successfully in this patient with an absolute resolution of all the symptoms that the patient had presented with and had been suffering from for a long time.

UNDER PEER REVIEW



DISCUSSION

The IgA present in the human body has a unique way of dealing with the microorganisms it encounters. It sometimes causes an autoreactive response, which can become an autoimmune-mediated response, resulting in the development of conditions such as IgA vasculitis, which is also known as Henoch Schonlein Purpura.^[5]

Bacterial and viral diseases have been seen to trigger IgA Vasculitis and COVID19 has also been seen to cause similar responses in the human host body. These bacteria and viruses are seen to elicit an autoimmune response which results in further insults and, finally, the appearance of IgA vasculitis in affected individuals. Some of the most well-known triggers that cause IgA Vasculitis include streptococcus, S.aureus, varicella zoster virus, human immunodeficiency virus (HIV), cytomegalovirus, and so on.^{[6][7]}

IgA vasculitis can affect both children and adults. In adults, it mostly takes the appearance of palpable purpura which are markedly present in the lower limbs of the patient. At times, the upper limbs and trunk of the patient can also be involved.^[8]

Approximately 70% of patients who suffer from IgA vasculitis experience abdominal pain. Of these, 30% also experience an episode or multiple episodes of gastrointestinal bleeding. However, this bleeding presents around a week after the rash has manifested on the skin of the patient.^[9]

When a patient's kidneys become involved, which is an infrequent occurrence, the options for an appropriate medication or treatment regimen become narrower to avoid further damage to the kidneys.

Almost all the affected patients have shown significant improvement as soon as a corticosteroid management plan is started. Prednisolone especially favors the renal profile without causing any further damage to the patient.^[10]

Apart from corticosteroids, the other available treatment options include dapsone, rituximab, intravenous immunoglobulin, and ACE inhibitors, depending on the underlying causes of the symptoms and the severity of the IgA vasculitis that the patient is suffering from.

UNDER PEER REVIEW

CONCLUSION

IgA vasculitis, also known as Henoch Schonlein Purpura, is an inflammatory disease of the blood vessels that mostly affects children, although it can also occur in adults. People who suffer from IgA vasculitis are seen to have a raised red or purple rash marked predominantly on the lower limbs. Later in the progression of the disease, an affected person may develop problems of the gastrointestinal tract, joints, or even the renal system, although the severity and intensity of all these symptoms differ from patient to patient.

IgA vasculitis is a rare disease, but it is found to have a familial component. As far as treatment is concerned, most of the time the condition goes away on its own after some weeks. However, if the patient is suffering from other associated symptoms, then supportive management along with a course of steroids might be needed to control the disease.

There have been reports of recurrence of the disease, but since it is rare and the symptoms controlled, the same treatment protocol can help to control these flare-ups easily.

REFERENCES:

1. Mahajan K, Osueni A, Haseeb M. Abdominal Angina. [Updated 2021 May 24]. In: StatPearls [Internet]. Treasure Island (FL): StatPearls Publishing; 2021 Jan-. Available from: <https://www.ncbi.nlm.nih.gov/books/NBK441943/>
2. Mosselvelde P, van Werkum MH, Menting TP, Pieters AMMJ, Müller METM, Bosch FH. (2018) A case of progressive abdominal angina. *Neth. J. Med.*, 76(5): 255.
3. Mensink PB, Moons LM, Kuipers EJ. (2011) Chronic gastrointestinal ischaemia: shifting paradigms. *Gut*, 60(5): 722-37.
4. Roache-Robinson P, Hotwagner DT. Henoch Schönlein Purpura. [Updated 2021 Aug 11]. In: StatPearls [Internet]. Treasure Island (FL): StatPearls Publishing; 2021 Jan-. Available from: <https://www.ncbi.nlm.nih.gov/books/NBK537252/>
5. Sugino, H., Sawada, Y., & Nakamura, M. (2021). IgA Vasculitis: Etiology, Treatment, Biomarkers and Epigenetic Changes. *International Journal of Molecular Sciences*, 22(14): 7538. <https://doi.org/10.3390/ijms22147538>.
6. Nakatsuka K. (1993). Serum anti-streptococcal IgA, IgG and IgM antibodies in IgA-associated diseases. *Acta Paediatr. Jpn*, 35:118–123. doi: 10.1111/j.1442-

200X.1993.tb03020.x.

7. Ushigome Y., Yamazaki Y., Shiohara T. (2017) IgA vasculitis with severe gastrointestinal symptoms may be an unusual manifestation of varicella zoster virus reactivation. *Br. J. Dermato.*,176: 1103–1105. doi: 10.1111/bjd.14948
8. Jennette J.C., Falk R.J., Bacon P.A., Basu N., Cid M.C., Ferrario F., Flores-Suarez L.F., Gross W.L., Guillevin L., Hagen E.C., et al. (2013). 2012 Revised International Chapel Hill Consensus Conference Nomenclature of Vasculitides. *Arthritis Rheum*, 65: 1–11. doi: 10.1002/art.37715.
9. Saulsbury F.T. (2007) Clinical update: Henoch-Schönlein Purpura. *Lancet*. 369: 976–978. doi: 10.1016/S0140-6736(07)60474-7
10. Pozzi C., Bolasco P.G., Fogazzi G.B., Andrulli S., Altieri P., Ponticelli C., Locatelli F. (1999). Corticosteroids in IgA nephropathy: A randomised controlled trial. *Lancet*, 353: 883–887. doi: 10.1016/S0140-6736(98)03563-6.