

## Effect of Dietary *Persea americana* on the Organosomatic Indices, Diseases Resistance and Liver Histopathology of *Klebsiella pneumonia* Infected *Clarias gariepinus*

### Abstract

The experiment was carried out to evaluate the prophylactic efficiency of dietary powdered *Persea americana* leaves on the organosomatic indices, disease resistance and liver histopathology of *Klebsiella pneumonia* infected *Clarias gariepinus*. Five (5) different isonitrogenous diets with varying percentages of *P. americana* powdered leaves inclusion were formulated as follows: Do(0%); D1(3%); D3 (6%); D3 (9%) and D4 (12%). One hundred and fifty (150) *C. gariepinus* were distributed in five groups in triplicates and fed diets Do-D4 accordingly. After eight (8) weeks of feeding, they were injected intraperitoneally at days 1, 7 and 14. After twenty one (21) days post infection period, three fish from each group were scarified for evaluation of the Hepatosomatic index (HSI); Cistosomatic index (CSI) and Splenosomatic index (SSI), and the liver was taken to the laboratory for histopathological analysis. The survival rate was calculated in each of the group and the disease resistance was determined. At the end of the experiment, serious ulcerations was observe on the fish fed Do and infected with *K. pneumonia*, while the fish fed D1 – D4 were ulcer free. The result reveals that the SSI and CSI were similar in all the groups (Do-D4), but the HSI was higher ( $P>0.05$ ) in the group fed Do (control) compared to the group fed D1-D4. The survival rate and the diseases resistance were lover ( $P<0.05$ ) in the group fed Do compared to the group fed D1-D4, though it was not does dependant. The result of the histopathology shows that the liver of the fish fed Do had blood stain in the portal vein and sinusoid, while the liver of the fish fed D1-D4 have no blood stain the experiment reveals that *Persea americana* powdered leaves as applied is an anti-liver inflammatory herb, disease resistant and bacterial.

Keywords: Aquaculture, Histology, Organosomatic Indices, Disease and *Klebsiella pneumonia*

### 12. Introduction

\_\_\_\_\_Aquaculture is the rearing of aquatic organism in a conducive and controlled environments or enclosures. It is one of the fasted growing food sector in the world [1]. The demand for fish and fish products have been on the high side due to population increase, and this cannot be met by the supply from natural water bodies. Environmental degradation and

population increase have affected aquaculture in developing countries [2], but agriculture and science have been developing ways to enhance productivity in aquaculture to meet up the high population demand and reduce the effects of environmental degradation [3]. Nutrients contain in fish and fish products could go a long way to solve the world malnutrition problems [4], and more than half billion people all over the world are relying on aquaculture and fisheries for a living [5].

One of the problems associated with aquaculture practice is the presence of micro-organisms. And this is as a result of so many factors, including maladministration of feed [6]. The presence of micro-organisms makes fish susceptible to diseases, which causes death and retard growth [7], and most of these diseases are caused by bacteria, viruses, fungi, parasites etc. [8]. There is serious need to improve disease resistance in aquaculture to enhance feed acceptability and growth [9; 10].

Synthetic drugs and chemicals have been used in aquaculture for the prevention and eradication of diseases, but their uses are associated with disadvantages such as polluting the environment, depositing on fish flesh, drug resistance, etc [10]. ~~[10] further stated that~~ the use of herb and herbal products is fast replacing the use of chemical, because it does not pollute the environment, deposit on fish flesh, and are not immunospecific [10].

The presence of disease or pathogen causing disease can be assessed in fish in so many ways: Haematological analysis [11; 12]; Organosomatic indices [13; 14], Biochemical parameters [15; 16] Histopathological analysis [17] among others.

Several herbs and herbal extracts have shown their potency as antibacterial in aquaculture, they includes: *Caricapapay* aqueous root extracts [18], *Persea americana* aqueous leaves extracts [19], *Azardirachta/curcuma lionga* aqueous extracts [20] etc.

The *Persea americana* leaves extracts have been reported to contain medicinal phytochemicals [21; 22]. This research work tents to assess the efficacy of *P. americanan* powered leave as in *Clarias gariepinus* infected with *Klebsiella pneumonia*.

### 23. Material and Methods

#### 23.1 Experimental Fish

The experimental fish was purchased in Idi-Onyana farms along Abua Ahoada road in Abua/Odual Local Government Area of Rivers State.

**Comment [S1]:** add the scientific name of the fish

#### 23.2 Experimental Diets

*Persea americana* leaves were harvested within Port Harcourt, Rivers State, Nigeria. They were air dried to constant weight, grounded to powdered, sieved and stored. The sieved powered leaves were added to 38.35cp formulated diets D<sub>0</sub>, at 3%(D1), 6% (D2), 9% (D3) and 12% (D4) respectively following the method of [23].

**Comment [S2]:** D<sub>0</sub> (group control )

#### 23.3 Experimental Procedure

150 catfish ( $117.80 \pm 0.11g$  and  $25.88 \pm 0.14cm$ ) were stocked in the experimental tanks in triplicate at 10 fish per tank. Feeding commenced 24 (twenty four) hours after stocking, and

**Comment [S3]:** Did the research go through an ethics committee? Are all procedures in accordance with ethical aspects? Put all this information at work

the fish were fed with the experimented diets (Do – D4) accordingly at 5% body weight per day, two (2) times daily. After 8 weeks of feeding, the fish were infected intraperitoneally at the day 1, 7 and 14 with 1.5ml of  $1.9 \times 10^5$  cfu/ml of overnight grown *K. pneumonea*. After 28 days post infection, the liver, spleen, heart were harvested from the experimental fish for organosomatic indices, the liver was analysed for histopathology, and the disease resistance ability and survival rates were determined.

**Comment [S4]:** Have the fish been anesthetized for this procedure? put more details on how it was done

**Comment [S5]:** after the first infection?

**Comment [S6]:** Were the fish euthanized for this collection? Like? put the entire procedure done

#### 2.3.4 Determination of Organosomatic Indices

This was determined using the formula:

$$\frac{\text{Weight of Organ}}{\text{Weight of fish}} \times 100 \quad [15]$$

#### 2.5 Histopathological Analysis

The fish liver was taken to the laboratory in sample bottles containing 10% formaline solution. The samples (liver) were manually processed and trimmed using a rotary microtone (LEICA RM 2125 RTS), manufactured by LEKA Brosysteo, Buffalo Grove, U.S.A. Tissues were dewaxed, stained in hematoxylin and eosin for display of tissue architecture. Stained slides were examined under light micro scope at x 10 magnification.

**Formatted:** Normal, No bullets or numbering

**Formatted:** Font: (Default) Times New Roman, 12 pt, Bold

#### 2.3.6 Anti-pathogenic Ability (Disease Resistance)

This was determined as relative percentage survival, using:

$$RSP = 1 - \frac{\% \text{ Mortality in treated}}{\% \text{ Mortality in control}} \times 100 \quad [24]$$

\_\_\_\_\_ Where RSP = Relative Survival Percentage

### **23.7 Data Analysis**

\_\_\_\_\_ The collected data were analysed using SPSS statistics software 17.0 windows. A one way analysis of variance (ANOVA) was employed to reveal significant difference between control and treated groups. Turkey's-Tukey's multiple comparison test was applied to separate treatments with significant difference [25].

### **3. Results**

\_\_\_\_\_ The result of the Organosomatic indices is shown in table 1, there were no significant difference in the spleenosomatic and cardiosomatic indices in the experimental fish fed Do – D4. The hepatosomatic index was significantly higher in fish fed Do ~~followed by fish fed D1~~, but significantly the same in fish fed D1 – D4 diets. The result for the disease resistance fluctuated across the diets, but it was significantly lower in the fish fed Do (control) followed by the fish fed D1 and significantly the same in the fish fed D2 – D4 (Table 2).

**Comment [S7]:** used the survival percentage and not the RSP

**Comment [S8]:** varied

\_\_\_\_\_ Plate 1 (a-f) shows the liver histopathology of the experimental fish infected with *K. pneumonia*. 4.1a is the liver of fish fed Do without infection, it has normal portal vein (P) and there are patches of liver vacuolations; 4.1b is the liver of fish fed Do and infected with *K. pneumonia*, it has blood stained portal vein with micro liver vacuoles and sinusoid; 4.1c is the liver of fish fed D1 and infected with *K. pneumonia*, it has central vein (CV) with no liver vacuoles and sinusoid; 4.1d is the liver of fish fed with D2 and infected with the *K. pneumonia*, it has micro liver vacuoles and sinusoid; 4.1e is the liver of fish fed D3 and infected with *K.*

*pneumonia*, it has portal vein, micro vacuoles and sinusoid; while 4.1f is the liver of fish fed D4, it has patches of liver vacuolations. Figure 1 shows picture of fish D0 and infected with *K. pneumonia* and figure 2 shows picture of fish fed supplemented diets and injected with *K. pneumonia*.

**Table 1: Organosomatic indices of some organs of *Clarias gariepinus* fed with Avocado pear leaf Supplemented diets and infected with *Klebsiella pneumonia* (Mean ±SD)**

Parameters	Diets				
	D0	D1	D2	D3	D4
HSI	2.00±0.25 <sup>a</sup>	1.71±0.09 <sup>b</sup>	1.06±0.21 <sup>b</sup>	1.19±0.02 <sup>b</sup>	1.20±0.08 <sup>b</sup>
CIS	0.08±0.02 <sup>a</sup>	0.15±0.00 <sup>a</sup>	0.78±0.01 <sup>a</sup>	0.10±0.02 <sup>a</sup>	0.06±0.05 <sup>a</sup>
SSI	0.06±0.04 <sup>a</sup>	0.08±0.04 <sup>a</sup>	0.06±0.02 <sup>a</sup>	0.07±0.01 <sup>a</sup>	0.03±0.02 <sup>a</sup>

Means within the same roll with different superscript are significantly different (p<0.05)

**Comment [S9]:** put here which test (ANOVA or Tukey)

HSI: Hepetasomatic Index; CSI: Cardiosomatic Index and SSI: Spleenosomatic Index

SSI: Spleenosomatic Index; CSI: Cardiosomatic Index

HSI: Hepetasomatic Index

**Table 2: Percentage Survival and Relative Survival Percentage (Disease Resistance) of *Clarias gariepinus* fed with Avocado pear leaf Supplemented diets and infected with *Klebsiella pneumonia* (Mean  $\pm$ SD)**

Parameters	Diets				
	D0	D1	D2	D3	D4
% Surv	66.66 $\pm$ 5.77 <sup>c</sup>	90.00 $\pm$ 10.00 <sup>b</sup>	96.66 $\pm$ 5.77 <sup>a</sup>	96.66 $\pm$ 5.77 <sup>a</sup>	93.33 $\pm$ 11.54 <sup>a</sup>
RSP	0.00 $\pm$ 0.00 <sup>d</sup>	69.33 $\pm$ 33.85 <sup>c</sup>	91.66 $\pm$ 14.43 <sup>a</sup>	91.66 $\pm$ 14.43 <sup>a</sup>	77.66 $\pm$ 38.68 <sup>b</sup>

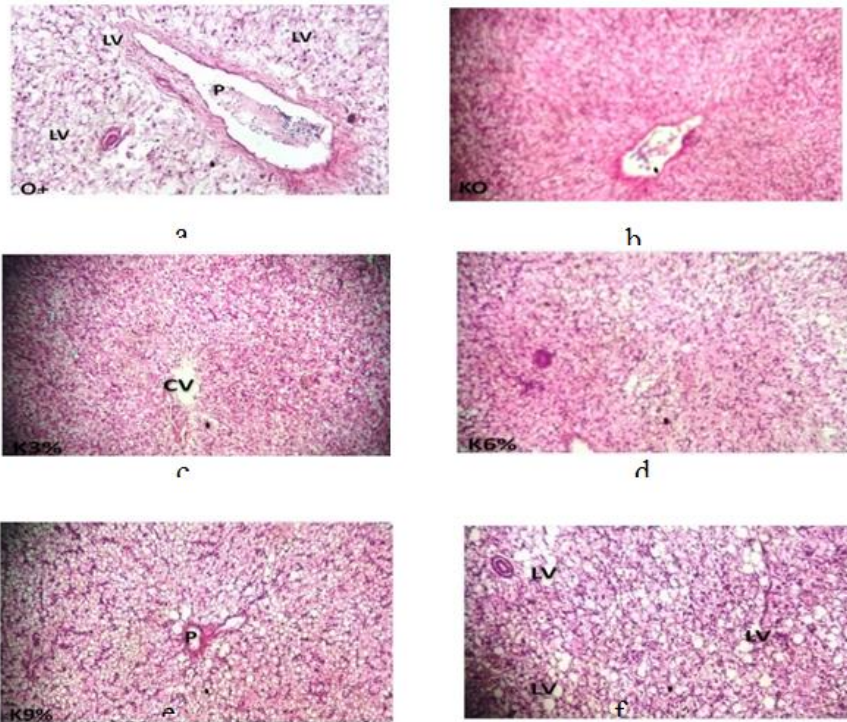
**Comment [S10]:** did not have this rate in the methodology. Put it in the methodology or remove it from here

Means within the same roll with different superscript are significantly different ( $p < 0.05$ )

**Comment [S11]:** put here which test (ANOVA or Tukey)

% Surv: Percentage Survival; RSP: Relative Survival Percentage

**Plate 1: Pathology of liver of *C.gariepinus* fed the experimented diets and exposed to *Klebsiella Pneumoniae***



- a: liver of fish fed (Do) 0% leaf inclusion diet without infection
- b: liver of fish fed (Do) 0% leaf inclusion diet exposed to *K.pneumoniae*
- c: liver of fish fed (D1) 3% leaf inclusion diet exposed to *K.pneumoniae*
- d: liver of fish fed (D2) 6% leaf inclusion diet exposed to *K.pneumoniae*
- e: liver of fish fed (D3) 9% leaf inclusion diet exposed to *K.pneumoniae*
- f: liver of fish fed (D4) 12% leaf inclusion diet exposed to *K.pneumoniae*



**Figure 1:** Fish Fed Do and Infected with *K. pneumonia*



**Figure 2: Fish Fed *P. americana* supplemented diet and infected with *K. pneumonia***

## **45. Discussion**

### **45.1 Behaviour Observation**

There were no ulcerations on the body of the fish fed D1 – D4 after the infection with *K. pneumonia*, but there were serious ulceration in the fish fed Do and exposed to *K. pneumonia*. Similar result was obtained when *C. gariepinus* was challenged with *P. aeruginosa* and exposed to *Carica Papaya* aqueous root extracts [11]. [26] also reported similar result when *punica* peel and oxytetracycline were administered on *A. hydrophila* infected *C. gariepinus*. This could be as a result of the phytochemicals present in the *P. americana* powdered leaves that are antibacterial [27; 28]. [29] also reported that phenolic compounds (as contained in *P. americana* in this work) seriously inhibits microbial activities. The result obtained in this work could also be as a result of improved thrombocytes formation in fish fed D1 – D4, which is believed to prevent injuries infected fish [30; 13].

### **45.2 Organosomatic Indices**

Organosomatic indices such as HSI, SSI and CSI are used to evaluate the health status of fish and other organisms [31; 14; 32]. Some of the factors that affects the organosomatic indices in fish includes water quality, feed type, presence of pathogen/disease etc. [14; 32; 13]. The result of the organosomatic indices after the period of infection in this work reveals that there were no significant difference in the CSI and SSI in the experimental fishes but the HSI value was higher ( $P>0.05$ ) in the fish fed Do compared to the fish fed D1 – D4. This result is in

**Comment [S12]:** this analysis was not in the methodology. To state that the observation of behavior in the methodology was also carried out.

agreement with the reports of [33] who reported increase in HSI when *rattus rattus* was infected with *cysticercus fasciolaris* and [13] when *C. gariepinus* fed dietary mango bark were experimentally infected the *P. aeruginosa*. [15] also reported increase in the size of the liver, spleen and intraperitoneal fat in the control, when *C. gariepinus* was challenged with *P. aeruginosa* and exposed to *P. americana* aqueous extracts.

\_\_\_\_\_ The increased HSI in the infected fish fed Do (control) could be as a result of glycogen depletion [34] arising from the restlessness and rapid opercula movement observed in the fish fed Do when they were injected with the *K. pneumonia* and depletion of glycogen leads to liver inflammation [35]. Lack of glycogen also leads to metabolic formation of fat in the liver [36] and this could lead to liver weight increase. The lower HSI in the fish fed D1-D4 compared to fish fed Do could be as a result of the antibacterial activities in the experimental herb [40; 18]. It could also be as a result of the anti-inflammatory effects of flavonoids and Saponins present in the *P. americana* powdered leaves [41; 15].

### **4.5.3 Liver Histopathology**

\_\_\_\_\_ There were high presence of liver vacuoles in the liver of fish fed 0% leaf inclusion diet without exposure to *K. pneumonia* (positive control), but the liver of the fish fed 0% leaf inclusion diet and exposed to *K. pneumonia* (negative control) had no vacuoles, but minor necrosis. This result is similar to the result of [41] when *Lactobacillus acidophilus* was used as a biocontrol agent against *Clarias gariepinus* juveniles infected with pathogenic bacteria (*Aeromonas hydrophila*). The liver of the fish fed D1 – D4 and exposed to *K. pneumonia* had little presence of liver vacuolation, with more in the fish fed D4. The high presence of liver vacuolation in the positive control could be as a result of the presence of high glycogen due to

energy intake and use, as a result of artificial feeding and rearing conditions [43], which is believed to be nutritionally induced [44]. The presence of necrosis in the infected fish fed Do could be as a result of poison released by the pathogenic bacteria (*K. pneumonia*) during infection [42], and the absence of liver vacuoles in the same fish could be the fish way of responding to infectious diseases [45], as loss of glycogen has been associated with concurrent diseases and stress [43]. The presence of liver vacuolation was noticed in the fish fed D1-D4 after the infection, but was prominent on fish fed D4. This could be as a result of the antimicrobial activities of the avocado pear powdered leaves [11], [19], due to the presence of medicinal phytochemicals [46, [47], [48].

#### **4.5.4 Disease Resistance**

The disease resistance ability which was calculated as relative percentage survival (RSP), and the percentage survival were lowest ( $P < 0.05$ ) in fish fed Do compared to the fish fed D1-D4, and it increased as the percentage inclusion of *P. americana* leaves increased in the diets. The result is similar to the reports of [13] who reported the effect of mango bark extract on *C. gariepinus* infected with *P. aeruginosa*; [49] who reported the effect of neem leaf powder on common carp infected with *A. hydrophila*. [18] also reported high disease resistance when *P. aeruginosa* infected *C. gariepinus* was exposed to *Carica papaya* aqueous extracts, and attributed the results to the presence of phytochemicals such as phenols. The high disease resistance in the fish fed D1-D4 could be as a result of the phytochemicals such as flavonoids and other alkaloids present in the *P. americana* leaves that are bactericidal or bacteriostatic [18; 21].

#### **5. Conclusion**

The result of this research work shows that powdered *P. americana* is a good prophylactic agent against ulceration and other skin diseases in *Clarias gariepinus* that may arise from the attack of *K. pneumonia*. Despite being a good antibacterial as seen in the result of the disease resistance in this work, *P. americana* powdered leaves have also proven to be a good anti-inflammatory and anti-necrosis agent in *C. gariepinus* liver in the presence of pathogens such as *K. pneumonia*. *P. americana* powdered leaves should also be tested for their efficacy against other fish pathogens, to enhance its usage in aquaculture. To this end, we advised that *P. americana* trees should be planted in our farms for availability of the leaves when needed.

#### **COMPETING INTERESTS DISCLAIMER:**

Authors have declared that no competing interests exist. The products used for this research are commonly and predominantly used products in our area of research and country. There is absolutely no conflict of interest between the authors and producers of the products because we do not intend to use these products as an avenue for any litigation but for the advancement of knowledge. Also, the research was not funded by the producing company rather it was funded by personal efforts of the authors.

#### **REFERENCES**

1. Food and Agriculture Organization (FAO). (2013). The state of food insecurity in the World 2013. The multiple dimensions of food security. Rome.

2. Otene, B.B and Ukwe, O. I. K.,(2018). Evaluation of Heavy Metal Accumulation in Water and Sediment from Elechi Creek, Port Harcourt, Nigeria *International Journal of Geography and Environmental Management*. 4 ( 1), 1-9.
3. Akinrotimi, O. A., Gabriel, U. U. Edun, O. M. (2015). The efficacy of clove seed extracts as an anaesthetic agent and its effect of haematological parameters of African Catfish (*Clarias garipinus*). *International journal of Aquaculture and fish Science* 1, 012 – 047.
4. Fasakin, E. A. (2007). Fish as food yesterday, today and forever. Inaugural lecture series 48. The Federal University of Technology, Akure.
5. Future Directions International (2013). Strategies Analysis paper: Fish for the future and food security. Independent strategic analysis of Autalia's Global Interests.
6. Ukwe, I. O. K., and Jamabo, N.A., (2020). Effects of Dietary Mango Bark (*Mangifera indica*) Extract on *Clarias gariepinus* (Burchell, 1822) Infected with *Pseudomonas aeruginosa*. *World Journal of Fish and Marine Sciences*, 12 (3): 74-80
7. Edward, J. N. (2010). Fish Diseases: Diagnosis and Treatment. Second edition, Wiley Blackwell.
7. Edward, J. N. (2010). Fish Diseases: Diagnosis and Treatment. Second edition, Wiley Blackwell.
8. Sharma, M. Shrivastav, A. B., Sahni, Y. P., and Pandey, G. (2012). Overviews of the Treatment and Control of common fish diseases. *International Research Journal of Pharmacy*, 3(7), 123-127.
9. EL-Haroun, E. R., Ma, A., Goda, S., & Kabir, C. M. A. (2008). Effects of dietary probiotics Biogens supplementation as growth promoters on growth performance and feed utilization of Nile tilapia, *Oreochromis niloticus*. *Aquatic Research*, 37, 1473 – 1480.
10. Ukwe, I. O. K. & Gabriel, U.U. (2019). Herbs and Herbal supplements: Key to a productive, Healthy and Eco-friendly aquaculture. *Delta Agriculturist*, 11(1/1), 55 – 67.
11. Ukwe, O.I.K, Abbey, I.S and Akinrotimi, O.A (2021). Behavioural and Haematological Changes in *Pseudomonas aeruginosa* Infected *Clarias gariepinus* Exposed to *Carica papaya* Root Extracts. *HEMATOLOGY ASIAN RESEARCH JOURNAL*, 5(1), 20-33.
12. Alsaid, M., Abuseliana, A. F. Deud, H. H., Mustapha, N. M., Bejo, S. K., Abdelhadi, V. M. & Handan, R. H. (2014). Haematological, Biochemical and Clinical signs changes following Experimental Infection of *Streptococcus agalactiae* in Red Hybrid Tilapia (*Oreochromis sp.*). *Aquaculture Indononesiana*, 15 (2), 86-93.
13. Ukwe, I. O. K., and Jamabo, N.A., (2020). Effects of Dietary Mango Bark (*Mangifera indica*) Extract on *Clarias gariepinus* (Burchell, 1822) Infected with *Pseudomonas aeruginosa*. *World Journal of Fish and Marine Sciences*, 12 (3): 74-80
14. Adeniran, A., Adeyemo, O. K., Emikpe, B. O. & Alarape, S. A. (2017). Organosomatic

Indices, Haematological and Histological Assessment as Biomarkers of Health Status in Feal and Cultured *Clarias gariepinus* *African Journal of Biomedicl Research*, 20:189-194.

15. Ukwe, I. O. K., and Etire, D.I. (2021). The Effects of *Persea americana* leaves on the Enzymes and Organosomatic indices of *Pseudomonas aeruginosa* Infected *Clarias gariepinus* *Journal of Medical Care Research and Review* 4(7), 1-29.
16. Gabriel, N. N., Quiang, J., Ma, X. Y., He, J., Xu, P. & Liu, K. (2015). Dietary Aloe vera improve plasma liquid profile, antioxidant, and hepatoprotective enzyme activities in GIFT- tilapia (*Oreochromis niloticus*) after *Streptococcus iniae* challenge. *Fish physiology and Biochemistry*, 41,1321 – 1332.
17. El-Barbary, M. J. (2010). Some clinical, microbiological and molecular characteristics of *Aeromonas hydrophila* isolated from various naturally infected fishes *Aquaculture International*, 18, 943-954.
18. Ukwe, I. O. K., and Vopnu, F.B. (2021). Diseases Resistance and Enzymatic Changes in *Pseudomonus aeruginosa* Infected *Clarias gariepinus* treated with *Carica Papaya* root extracts. *Journal of Medical Care Research and Review* 4(7), 1-26.
19. Ukwe, I. O. K., and Irondi, P. (2021). Effects of *Persea amaericana* leaves extracts on antioxidant activities and diseases resistance of *Pseudomonas aeruginosa* infected *Clarias gariepinus*. *European Journal of Biomedical and Pharmaceutical Sciences* , 8(9), 67-78.
20. Harikrishnan, R., Balasundaram, C. & Heo, M. S. (2010). Potential use of probiotic and triherbal extract – enriched diets to control *Aeromonus hydrophila* infection in carp. *Diseases of Aquatic Organisms*, 92, 41-49.
21. Ogundare, A. O. & Oladejo, B. O. (2014). Antibacterial Activities of the leaf and Bark Extract of *Persea Americana*. *American Journal of Ethnomedicine*, 1(1), 64-71.
22. Oyeyemi, A. O. & Oyeyemi, R. B. (2015). Effect of Aqueous of the leaves and seeds of Avocado pear (*Persea Americana*) on some Marker Enzymes and Cholesterol in Albino Rat Tissues. *Journal of Environmental Science, Toxicology and food Technology*, 9 (3), 15-18.
23. Lee, D. H., Ra, C. S., Song, Y. H., Sung, K. I. & Kim, J. D. (2012). Effects of dietary garlic extract on growth, feed utilization and whole body composition of juvenile starlet sturgeon (*Acipenser ruthenus*). *Asian Australian Journal of Animal Sciences*, 25(4), 577583.
24. Harikrishnan, R., Kim, J. S., Balusundaram, C. & Heo, M. S. (2012). Protection of *vibro herveyi* infection through dietary administration of *Pueraria thunbergiana* in kelp grouper, *Epinephelus bruneus*. *Aquaculture*, 324, 27-32.

25. Wahua, T. A. T. (1999). Applied statistics for scientific studies. Africa links books. Aba, Nigeria, 365pp.
26. Reda, M. R., Galal, A. A. A. & Alam, R. T. M. (2012). Comparism of Punica Peel and Oxytetracy on Aeromonas hydrophile challenged *Clarias gariepius*. *Global Journal of Fisheries and Aquatic Research*, 5(5): 01-15.
27. Noorul, H., Nesar, A., Zafar, K., Khalid, M., Zeeshan, A. & Vartika, S. (2016). Health benefits and pharmacology of Persea Americana mill (Avocado). *International Journal of Research in Pharmacology and Pharmacotherapeutics*, 5(2),132-141.
28. Sales, C. H., Souza, P. R., Peghini, B. C., Da Silver, J. S. & Cardoso, C. R. (2013). An overview of the modulatory effects of Oleic acid in health and diseases. *Mini-reviews in Medicinal Chemistry*, 13, 1-11.
29. Vasconcelos, L. C., Sampaio, F. C., Sampaio, M. C., Pereira Mdo, S., Higino, J. S. & Peixoto, M. H. (2006). Minimum inhibitory concentration of adherence of Punica grantum Linn (pomegranate) gel against *S. Mitans*, *S. mitis* and *C. albicans*. *Brazilian Dental Journal*, 17:223 – 227.
30. Etim, L., Ekanem, S. B. & Utim, A. (1999). Haemetological profile of two species of catfish chrysthus nigrodigitatus and chrysiethys furcatus from the great kwa River, Nigeria. *Global Journal of Pure and Applied Science*, 5(1): 1-8.
31. Gabriel, U. U., Obomanu, F. G. & Etori, O. S. (2009). Haematology, Plasma enzymes and Organ indices of *Clarias gariepinus* after intracellular injection with *aqueous* leaves extracts of *Lepidagathis alopecurotides* *African Journal of Biochemical Research*, 3, 312-316.
32. Kareem, Z. H., Abdelhadi, Y. M., Christianus, A., Karim, M. & Romano, M. (2016). Effects of some dietary crude plant extracts on the growth and gonadal maturity of Nile tilapia (*Oreochroius niloticus*) and their resistance to streptococcus agalactiae infection. *Fish Physiology and Biochemistry*, 42,757-769.
33. Gupta, N., Gupta, D. K. & Sharma, P. K. (2016). Condition factor and organosomatic indices of Parasitized *Rattus rattus* as indications of host health. *Journal of Parasitic diseases*, 61, 21-25.
34. Quentel, C. & Obach, A. (1992). The cellular composition of the blood and hematopoietic organs of turbot, *Scophthalmus maximus* . *Journal of Fish Biology*, 415, 709-716.
35. Bandsman, R. H., Prinsen, B. H., Van, D. V., Rake, J. P., Boer, T., Smith, G. O., Reingngoud, D. J. & Kuipers, F. (2008). Increase de novo lipogenesis and delayed conversion of large VLDL into ointermediate density lipoprotein particles contribute to hyperlipidenua in glurogen storage disease type. *La pediatric Research*, 63: 702-707.

36. Irima, J. M., Meyer, C. M., Segvich, D. M., Surendran, S., Depali – Roach, A. A., Moral, N. & Roach, P. J. (2017). Lack of liver glycogen causes hepatic insulin resistance and steatosis in mice. *Journal of Biological Chemistry*, 292 (25): 10455 – 10464.
37. Sivaram, V., Babu, M. M. Citarasu, T., Immanuel, G., Murugadass, S. & Mariam, M. P. (2004). Growth and Immune response of juvenile greasy groupers (*Epinephelus tavivina*) fed with herbal antibacterial active principle supplemented diets against *Vibrio harveyi* infections. *Aquaculture*, 237, 9-20.
38. Kumala, S., Utami, H. & Sari, W. K. (2013). The effect of Avocado (*P. americana mill*) leaves Extract Towards the Mouse's Blood Glucose Decrease with the Glucose Tolerance Method. *International Journal of Pharmaceutical Sciences and Research*, 4(2), 661 – 665.
39. Al-Dohail, M. A., Hashim, R. & Aliyu-Paiko, M. (2011). Evaluating the use of *Lactobacillus accidephilus* as a biocontrol agent against common pathogenic bacteria and the effects on the haematology parameters and histology in African catfish *clarias gariepinus* juveniles. *Aquaculture Research*, 42(2), 196-209.
40. Bowser, P. R., Wooster, G. A., chen, C. Y. & Mo, R. S. (2004). Polymicrobial infection of hybrid striped bass (*Morone chrysops* x *Morone saxatilis*) with three bacterial pathogens: A case report. *Journal of Fish Diseases*: 27, 123 – 127.
41. Wolf, C. J. & Wolfe, M. J. (2005). A Brief Overview of Nonneoplastic Hepatic toxicity in fish. *Toxicologic Pathology*, 33,75-85.
42. Penrith, M. I., Bastianello, S. S. & Penrith, M. J. (1994). Hepatic lipidosis and fatty infiltration of organs in captive African Stonefish, *Synanceja verrucosa* Bloch and Schneider. *Journal of Fish Diseases*, 17,171-176.
43. Boorman, G. A., Batts, S., Bunton, T. E., Fournie, J. W., Harshbarger, J. C., Hawkins, W. E., Hinton, D. E., (1997). Diagnostic criteria for degenerative, inflammatory, Proliferative non-neoplastic and neoplastic liver lesions in medaka (*Oryziaslatipes*) consensus of a National Toxicology program pathology Working Group. *Toxicology Pathology*, 25, 202-210.
44. Adeyemi, J. A. (2014). Oxidative stress and antioxidant enzymes activities in the African catfish, *Clarias gariepinus*, experimentally challenged with *Eshenchina coliarod* vibro fischeri. *Fish Physiology and Biochemistry*, 40, 347-354.
45. Ojewole, J. A. & Amabeoku, G. J. (2006). Anticonvulsant effect of *Persea americana mill*, Lauraceae (Avocado) leaf aqueous extract in mice. *Phytotherapy Researcher*, 20(8), 696 – 700.
46. Brai, B., Adisa, A. R. & Odetola, A. A. (2014). Hepatoprotective properties of Aqueous

leaf Extract of *Persea Americana*, Mil (Laura ceac) “Avocado” Against Cel <Sub>4,/Sub> Iduced Damage in Rats. *African Journal of Traditional Complementary and Alternative Medicine*, 11(2): 236 – 244.

47. Verma, R. K., Kumari, M. & Singh, G. (2013). Ameliorating effect of neem (*Azadiracha indica*) leaf powder on pathology of *Aeromonas hydrophila* infection in common carp (*Cyprinus carpio* L.) *Annals of Biology*, 29, 418 – 428.

UNDER PEER REVIEW