

**MANAGEMENT OF INSTRUMENT SEPARATION:
RETRIEVAL AND BYPASSING – CASE REPORTS**

Comment [MF1]: IN MOLARS

ABSTRACT

A thorough knowledge of the root canal morphology and unusual anatomy of the tooth is critical for successful endodontic treatment. Common configuration in mandibular molar is two roots and three root canals with different combinations or curvatures. Instrument separation is one of the most common iatrogenic error that occurs in an endodontic practice. The treatment option and success vary based on a number of factors. These case reports are on the retrieval of the separated instrument from the coronal third of the middle mesial canal of the mandibular first molar and bypassing the instrument in the apical curvature of distobuccal root of maxillary second molar.

Keywords: Instrument, separation, retrieval, bypass

INTRODUCTION

Procedural errors happening during endodontic procedures have shown to have a direct impact on the long-term prognosis of the treated tooth. The most common errors during an endodontic procedure includes ledge formation, canal transportation, perforation, instrument separation and missed canals.¹

The main reason for separation of instrument is cyclic fatigue in 44.3% and torsional fatigue in 55.7% of the cases. The

stainless-steel instrument has an 0.25-6% fracture rate and Spili in 2005 showed the rate of fracture of Nickel Titanium (NiTi) files were 1.3%-10%.^{2,3} The prognosis for a tooth with a separated instrument depends on the extent of undebrided and unobturated canal that remains below the broken instrument when the instrument cannot be removed or bypassed. There are various treatment options available for the retrieval of separated instrument from the canal and ultrasonics have gained major attention in the recent times for retrieval.⁴

Comment [MF2]: deleted

Comment [MF3]: ,

Common anatomic variation that have been noticed in the mandibular molars include the occurrence of Middle Mesial Canal (MMC), isthmus and C shaped canals.⁵ The prevalence of MMC in 0.26-53.8% depending on the population.⁶ Pomeranz et al classified MMC into three types namely Fin, Confluent and Independent. Fin based on the origin and termination of canal.⁷

In relatively smaller sized roots, retrieving the fragment is not opted for treatment as it is not conservative. An alternative technique that does not require direct visibility to the fragment is the “bypass”, where a fine file is inserted between the fragment and root canal wall and thereby negotiating the canal to full working length and enable thorough instrumentation and obturation with the fragment remaining in situ.

PRESENTATION OF CASE

CASE REPORT 1:

A 17-year-old male patient reported with the complaint of pain in left lower back tooth region for 2 weeks. Intra oral examination revealed deep dentinal caries with respect to 36. IOPAR findings showed the radiolucency was involving enamel, dentin and pulp in relation to 36. Diagnosed as

Comment [MF4]: at

Comment [MF5]: posterior

asymptomatic irreversible pulpitis in 36. Treatment plan was to do RCT in 36. Under LA and rubber dam isolation access cavity preparation was carried out. The floor of the pulp chamber was explored using DG 16 explorer and the canals were identified. Mesio Buccal (MB), Mesio lingual(ML), Middle Mesial (MMC) and Distal canals were identified. Initial scouting of the canal was done with 10 K file, working length was measured with an electronic apex locator and then confirmed with a radiograph, path finder rotary NiTi file was used to create a glide path. During the preparation of the MMC, instrument separation was identified in the coronal one third and was confirmed with the radiograph. (1a) The separated instrument was visualized under microscope(1b) Since the fragment was above the root canal primary curvature and present in the coronal one third, Pro Ultra tips (Dentsply Tulsa) was used for troughing and the retrieval of the instrument. The orifices of the other canals were blocked with cotton during retrieval to prevent it from getting displaced to the other canals. (1c, d) After the retrieval the MMC was negotiated to the working length (1e). Cleaning and shaping were done till 25.06 for MB, ML and Distal and 25.04 for MMC (1f). Seal apex sealer and Single cone techniques was used for the obturation of the canals. (1g) Composite coronal restoration was placed(1h).

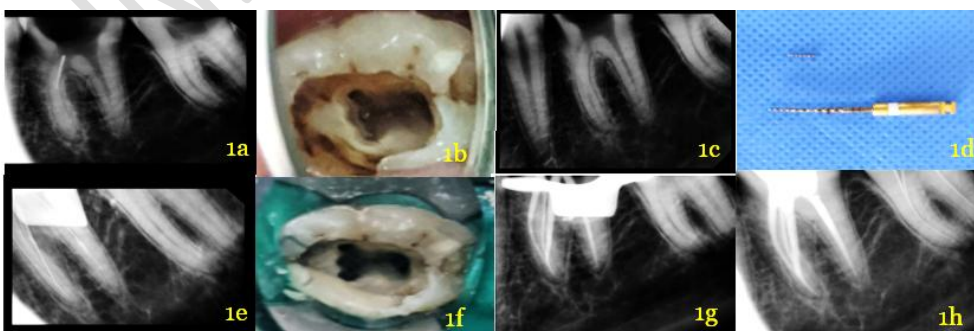


Fig :1a. IOPAR showing fractured fragment 1b. Access cavity preparation and location of separated instrument fragment in MMC 1c. Fragment retrieved using ultrasonic tips 1d. Retrieved fragment 1e. working length estimation. 1f. Cleaning and shaping done. 1g. Master cone verification 1g. Final coronal restoration with composite.

CASE REPORT 2:

A 30-year-old male patient came with the complaint of pain in his upper right back tooth region for the past 2 months. Clinical examination revealed fractured restoration in 17 and Electric Pulp Testing gave a negative response. IOPA in relation to 17 shows radiolucency involving enamel, dentin and pulp. Diagnosis was symptomatic irreversible pulpitis in 17. Treatment plan formulated to do RCT in 17. RCT initiated in 17 with Protaper Gold Rotary files in sequence, instrument S2 got separated in distobuccal canal of 17 (2a) was verified in IOPA (2b) Bypassing was started by introducing a size 06.02 SS pre-curved K-file engaging between the separated file and root dentin in lateral filing motion withdrawing it and the process repeated with a 08.02, 10.02, 15.02 (2c) followed by Working length estimation with apex locator and confirmed radiographically (2d, e). Glide path preparation with path files, Proglider 16.02, 19.02. Following which cleaning and shaping was completed up to Protaper F1 and master cone was verified (2f, g) obturation done using Bioceramic sealer and coronal restoration done with composite resin in 17 (2h).

Comment [MF6]: posterior

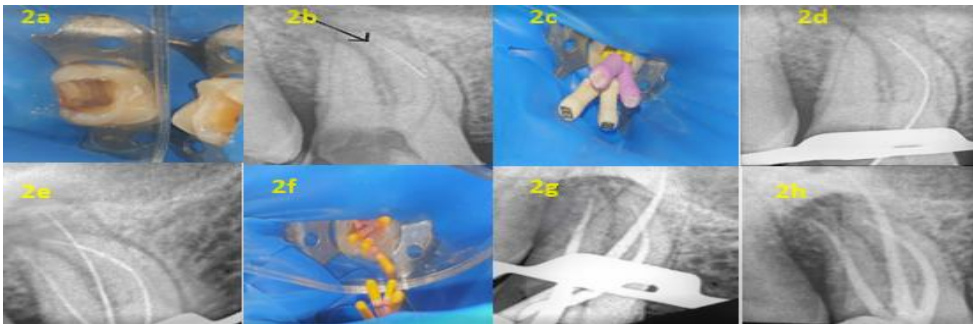


Fig 2a. Access cavity preparation and separated instrument
 distobuccal canal 2b. IOPAR showing fractured fragment 2c.
 Instrument bypassed using hand file 2d,e. working length
 estimation and radiographic confirmation 2f..Master cone
 placed 2g. master cone verification done radiographically 2h.
 Final coronal restoration with composite.

DISCUSSION

The management of a separated instrument includes retrieval, bypassing the separated instrument, leaving it in situ and surgical management. Retrieval of the instrument can be attempted if the separated fragment can be visualized, present above the primary curvature of the root and does not further complicate the root canal treatment by the formation of ledge. Instrument retrieval system, wire loop, canal finder system, Endo Extractor kit, Masserann Kit are some of the commercially available tools to retrieve a separated instrument. The most common complication associated with the removal of the instrument include potential.⁸

Ultrasonic tips designed for creating staging platform and instrument has been introduced as they are more conservative

by preserving the dentin wall thickness reducing the chances of strip perforation. Studies have shown that with the use of ultrasonic for retrieval the outcome ranges from 67-95%. The ultra-sonics used in trephining action and the vibration being transmitted to the fragment, the latter often begins to loosen and then comes out of the root canal. In the present case study ultrasonic with low setting and pro ultra-tips were used for the retrieval which preserves maximum amount of dentin in the root surface.⁹

In first case, middle mesial canal was confluent variety where middle mesial canal originated as a separate orifice but apically joined the MB canal. An ultrasonic tip used for removal of any protuberance from the mesial axial wall which prevent direct access to the developmental groove between MB and ML orifices. If depression or orifices are located, the groove can be troughed with ultrasonic tips at its mesial aspect until a small file can negotiate this intermediate canal.⁹ Cleaning and shaping of the MMC in the present case was stopped at 25.04 to preserve the dentin and prevent strip perforation. In the recent studies by Keles A in 2020 and Kilic Y in 2021 the fracture resistance of the mesial root of the mandibular molar decreases with the increase in the taper of the instrument and apical size preparation.^{10,11}

Use of magnification or a pre-operative CBCT image have shown to improve the identification of the middle mesial canal. Although in the present case CBCT image was not taken, the use of magnification aided in the identification of the MMC.^{12,13}

In the second case the separated instrument was located beyond the root curvature. Incorporating the fragment in the root canal obturation material considerably improves the case prognosis. Before bypassing a separated instrument, the

clinician should examine different horizontally angulated radiographs¹⁴. Proper coronal access should be made before bypassing a separated instrument. Different techniques may be employed in flaring the canal coronal to an intra-canal obstruction.¹⁵

However, the predictable and safe way is sequential use of initially hand files, followed by Gates Glidden (GG) drills sizes 1 to 2.¹⁶ Flushing the canal system with irrigating solution facilitate flaring of the canal walls. The irrigation protocol, the delivery and sequence in which they are delivered is important to remove smear layer as well as debris. The use of a chelating agent can facilitate removal or dissolve it partially or total removal of debris in between the instrument and between the instrument itself and the dentinal wall. In the cases reported here, we used Avuprep 17% EDTA as chelating agent and it made bypassing an easy procedure¹⁷ associated with the action of an increasing taper hand files for bypassing.¹⁸ The tooth structure would be preserved and major accidents, such as deviations and root perforations, would be avoided. The incidence of these events could significantly compromise the prognosis of the cases. This clinical decision agrees with previous studies that found that, due to the impossibility of completely removing the fragments, especially those located in the apical thirds, bypassing constitutes an important alternative.¹⁹ The current procedure presented a safe technique targeting this goal.

Comment [MF7]: deleted

CONCLUSION

The best method for managing separated instruments in the root canal is prevention of such incidences. Decision making is a key in success of the treatment, whether to bypass it or to

retrieve the separated instrument and it depends on various factors. From the two cases mentioned in this article we were able to reach to a conclusion that if the separated instrument is able to be bypassed, it is more conservative than retrieving the separated instrument although with the aid of magnification and ultrasonic, proved to have the potential to be used safely, avoiding the incidence of accidents in retrieval and has now become an emerging successful treatment modality. Proper management of these cases have good success in long term clinical practice.

REFERENCES:

1. Ansari I, Maria R. Managing curved canals. *Contemp Clin Dent.* 2012;3(2):237–41.
2. Iqbal MK, Kohli MR, Kim JS. A retrospective clinical study of incidence of root canal instrument separation in an endodontics graduate program: a PennEndo database study. *J Endod* 2006; 32:1048–52.
3. Spili P, Parashos P, Messer HH. The impact of instrument fracture on outcome of endodontic treatment. *J Endod* 2005; 31:845–50.
4. Bahcall JK, Carp S, Miner M, Skidmore L. The causes, prevention, and clinical management of broken endodontic rotary files. *Dent Today* 2005;24. 74, 76, 78–80.

5. Fabra-Campos H. Unusual root anatomy of mandibular first molars. *Journal of endodontics*. 2015 Dec 1;11(12):568-72.
6. Bansal R, Hegde S, Astekar M. Morphology and prevalence of middle canals in the mandibular molars: A systematic review. *Journal of oral and maxillofacial pathology: JOMFP*. 2018 May;22(2):216.
7. Pomeranz HH, Eidelman DL, Goldberg MG. Treatment considerations of the middle mesial canal of mandibular first and second molars. *J Endod*. 2018; 7:565–8.
8. McGuigan MB, Louca C, Duncan HF. Endodontic instrument fracture: causes and prevention. *British dental journal*. 2013 Apr;214(7):341-8.
9. CHHina H, HanS MK, CHanDer S. Ultrasonics: a novel approach for retrieval of separated instruments. *Journal of clinical and diagnostic research: JCDR*. 2015 Jan;9(1): ZD18.
10. Keles A, Keskin C, Alqawasmi R, Versiani MA. Evaluation of dentine thickness of middle mesial canals of mandibular molars prepared with rotary instruments: a micro-CT study. *International endodontic journal*. 2020 Apr;53(4):519-28.
11. Kılıç Y, Karataşlıoğlu E, Kaval ME. The effect of root canal preparation size and taper of middle mesial canals on fracture resistance of the mandibular molar teeth: An in vitro study. *Journal of Endodontics*. 2021 Jun 9.
12. Patel, S., Brown, J., Pimentel, T., Kelly, R.D., Abella, F. and Durack, C., 2019. Cone beam computed tomography in endodontics—a review of the literature. *International endodontic journal*, 52(8), pp.1138-1152.

13. Kim S, Baek S. The microscope and endodontics. *Dental Clinics*. 2014 Jan 1;48(1):11-8.
14. Adl A, Shahravan A, Farshad M, Honar S. Success Rate and Time for Bypassing the Fractured Segments of Four NiTi Rotary Instruments. *Iran Endod J*. 2017;12(3):349-353
15. Nevares G, Cunha RS, Zuolo ML, da Silveira Bueno CE. Success rates for removing or bypassing fractured instruments: a prospective clinical study. *J Endod*. 2012;38(4):442-4.
16. Schäfer E, Schulz-Bongert U, Tulus G. Comparison of hand stainless steel and nickel titanium rotary instrumentation: a clinical study. *J Endod*. 2014;30(6):432-5.
17. Huque, K.Kota, M. Yamaga, M. Iwaku, E. Hoshino. Bacterial eradication from root dentine by ultrasonic irrigation with sodium hypochlorite and EDTA IEJ.2018;31:242-250.
18. Madarati AA, Hunter MJ, Dummer PM. Management of intracanal separated instruments. *J Endod*. 2013;39(5):569-81
19. El-Kishawi, Mohamed & Khalaf, Khaled. (2021). An Update on Root Canal Preparation Techniques and How to Avoid Procedural Errors in Endodontics. *The Open Dentistry Journal*. 15. 318-324.