

Case study

HEART FAILURE: A RARE COMPLICATION OF HYPOCALCEMIA

ABSTRACT:

Calcium plays a crucial role in heart muscle contraction and relaxation. Hypocalcemic heart failure has been rarely reported.

We present the case of a 23-year-old woman who developed acute heart failure during the period following total thyroidectomy. The patient presented with congestive heart failure that improved dramatically with amelioration of plasma calcium levels. The patient was discharged asymptomatic, medicated with calcium carbonate, calcitriol, Vit-D supplementation with standard heart failure treatment.

This case highlights the importance of considering hypocalcemia as a cause of reversible myocardial dysfunction.

KEYWORDS:

Hypocalcemia, Hypoparathyroidism, Heart failure

INTRODUCTION:

Calcium is an important factor that controls myocardial contraction and relaxation (1), Hypocalcemia is a rare reversible cause of heart failure. We report the case of a young patient with reversible dilated cardiomyopathy and heart failure due to iatrogenic hypoparathyroidism.

CASE REPORT:

We report the case of a 23-year-old woman, with a history of thyroidectomy for papillary thyroid carcinoma 3 years ago, that came to the emergency department for progressive installation of dyspnea and lower leg edema. The clinical examination showed hypotension of 90/70mmHg, tachycardia of 102bpm and ankles edema. The electrocardiogram (**Figure 1**) revealed a sinus rhythm with prolonged corrected QT-interval (520ms). The chest X-ray (**Figure 2**) showed a cardiomegaly. The echocardiography revealed a dilated cardiomyopathy with left and right ventricular dysfunction, an ejection fraction of 45%, moderate mitral regurgitation with restriction of the posterior leaflet, moderate tricuspid regurgitation, dilated inferior vena cava and an estimated pulmonary artery pressure of 46 mmHg.

Comment [mm1]: She

The biological tests revealed severe hypocalcemia (38 mg/l) with normal albumin and thyroxin values, high levels of phosphoremia and thyroid stimulating hormone. The patient received calcium and Vit-D supplementation and was treated with betablockers, ACE-inhibitor and diuretics with a good evolution and a progressive normalization of cardiac function.

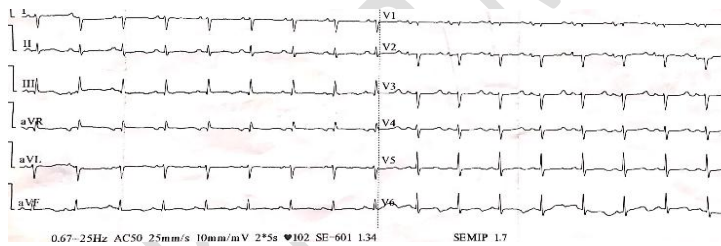


Figure 1 : Electrocardiogram showing a sinus rhythm with prolonged corrected QT-interval (520ms)

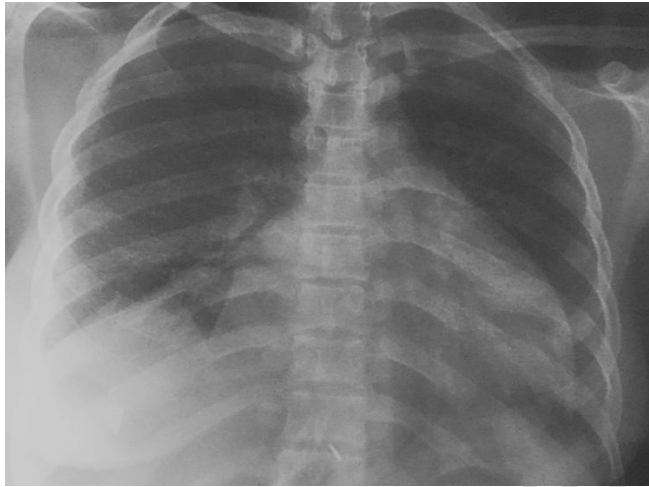

Figure 2 : Chest X-Ray showing cardiomegaly

DISCUSSION:

Cardiovascular manifestations of chronic hypocalcemia appear for deep low levels of calcium. It can lead to hypotension, arrhythmias, ventricular fibrillation, prolonged QT-interval, or heart failure. Heart failure is a rare and severe complication of hypocalcemia (2), but is characterized in most cases by a complete normalization of the myocardial function after the correction of hypocalcemia.

The role of serum calcium in excitation and contraction of heart muscle fibers is well established. During membrane depolarization, extracellular calcium ions flux into the myocytes through voltage-gated L-type calcium channels. This triggers release of calcium from sarcoplasmic reticulum. Subsequent binding of calcium ions to troponin-tropomyosin complex stimulates cross-linking of actin and myosin filaments leading to muscle contraction (3). Although the kinetics of intracellular calcium is clearly related to muscle contraction and relaxation, the mechanism of myocardial dysfunction secondary to hypocalcemia is not fully understood (1,4,5), and at the same time, more recent evidence suggests that vitamin D and Parathormon (PTH) may also have an independent role to play.

The main etiology of hypocalcemia is Hypoparathyroidism that may affect both sexes and all ages, and can have different causes, particularly idiopathic and surgical, and its main clinical

manifestations are due to its effects on calcium-phosphorus metabolism.

Hypocalcemia following thyroidectomy can be caused by the accidental removal of one or more parathyroid glands, ischemia caused by damage to their delicate blood supply, or simply manipulating the glands (3, 4). It is now known that hypocalcemia is a relatively common complication of surgery that in most cases is transient and asymptomatic (4).

Most commonly, the characteristic ECG manifestation of hypocalcemia is prolongation of the QT interval as a result of lengthening of the ST segment (like in our patient). The T waves are typically normal in duration, amplitude and morphology. Decreased T wave voltage, T wave flattening, terminal T wave inversion, or deeply inverted T waves have rarely been described in cases of severe hypocalcemia. Although rarely reported, hypocalcemia can be associated with ST segment elevation, mimicking an acute myocardial infarction or T wave abnormalities. (6)

Comment [mm2]: Like present case

In the few cases in the literature describing heart failure as a complication of hypocalcemia, all patients recovered myocardial function when calcemia was corrected, which supports the hypothesis that it is a reversible cause of heart failure. (7, 8)

This relationship was also observed in our patient, because recovery of myocardial function was seen once the metabolic disturbance was resolved.

Early measurement has the advantage of enabling appropriate treatment, including calcium and calcitriol supplementation and, in extreme cases, intravenous parathyroid hormone.

CONCLUSION:

Hypocalcemic heart failure is a rare but reversible heart disease. A systematic follow-up of calcium levels is recommended after thyroid surgery for early diagnosis of hypoparathyroidism.

REFERENCES:

- 1-Opie LH. Mechanisms of cardiac contraction and relaxation. In: Braunwald E, editor. Heart disease: a textbook of cardiovascular medicine. Philadelphia: WB Saunders; 2008. p. 509-39.
- 2- Pallidis LS et al. A case of severe hypocalcemia mimicking myocardial infarction. *Int J Cardiol.* 1997;61:89–91
- 3- Szent-Györgyi AG. Calcium regulation of muscle contraction. *Bio-phys J.* 1975;15:707–723.
- 4- Noordzij JP, Lee SL, Bernet VJ, et al. Early prediction of hypocalcemia after thyroidectomy using parathyroid hormone: an analysis of pooled individual patient data from nine observational studies. *J Am Coll Surg.* 2007;205:748---54.
- 5- Stulz PM, Scheidegger D, Drop LJ. Ventricular pump performance during hypocalcemia: clinical and experimental studies. *J Thorac Cardiovasc Surg.* 1979;78:185:94
- 6- Ehad C, Raphael R, Sami V. Electrocardiographic Manifestations of Calcium Abnormalities. *Ann Noninvasive Electrocardiol.* 2016 Jan; 21(1): 7–9.
- 7- Suzuki T, Ikeda U, Fujikawa H, et al. Hypocalcemic heart failure: a reversible form of heart muscle disease. *Clin Cardiol.* 1998;21:227---8.
- 8- Hurley K, Baggs D. Hypocalcemic cardiac failure in the emergency department. *J Emerg Med.* 2005;28:155---9.