

Secondary diverticulum ~~containing multiple stones at the tip~~ of a Meckel's diverticulum containing enteroliths:

A case report.

Abstract

Perforation of Meckel's diverticulum with enteroliths is a rare complication. Here, in our case of perforation of Meckel's diverticulum with a secondary diverticulum at its tip containing multiple stones. We report a case of a 31-year-old man who was previously healthy and who presented with lower abdominal pain for 3 days associated with vomiting and fever. Abdominal multi-detector CT showed a well-defined collection close to the terminal ileum containing multiple stones and oral contrast. Laparotomy was done and resection of a small part of the terminal ileum containing the Meckel's diverticulum with its secondary diverticulum and anastomosis was done.

***Keywords:* Meckel's diverticulum, Secondary diverticulum, and ~~enterolith~~faecolith, laparoscopy.**

Introduction

Meckel's diverticulum is frequently suspected, often thought of, and seldom found- Charles Mayo. At the beginning of the 19th century, the embryological and pathological features of Meckel's diverticulum were described by Johann Friedrich Meckel (1). Meckel's diverticulum is the most prevalent congenital abnormality of the gastrointestinal tract, occurring in about 2% of the general population. When present, there is an estimated 4–16% lifetime risk of becoming complicated causing intestinal obstruction, intussusception, bleeding, inflammation, and occasionally perforation (2-3). ***Chan et al.*** (8) reported about 300 cases of perforation of Meckel's diverticulum by a foreign body, and many cases of fish and chicken bones, wood splinters, and button batteries have been mentioned in the literature (8-9). However, the formation of a stone in the Meckel's diverticulum is a rare condition, we are presenting a case with a secondary diverticulum at its tip containing multiple stones.

Case history

A 31-year-old male patient presented with continuous abdominal pain that he has been experiencing for two days. The pain was associated with fever, vomiting, and loss of appetite. On physical examination, he had rebound tenderness and guarding in the right lower quadrant and the midline, his other systems examinations were normal. The white blood cell

count was 13,600, and the C-reactive protein (CRP) level was 113.9, with no abnormalities in his remaining laboratory examinations. **The abdominal CT** showed a well-defined collection about 5.5x4 cm close to the terminal ileum containing air, multiple stones, and oral contrast. On emergent surgery, a diagnostic laparoscopy was started, and the appendix was normal and there was an inflamed Meckel's diverticulum 40 cm from the ileocecal valve that was surrounded by adhesions. On its tip, there was a secondary diverticulum as shown in the pictures (fig. 1). The laparoscopy was converted to lower midline laparotomy and resection of a small part of the small bowel containing the Meckel's diverticulum and anastomosis was done. The histopathological evaluation showed a perforated Meckel's diverticulum with a secondary diverticulum and multiple dark brown stones within the secondary diverticulum. The Meckel's diverticula contained intestinal mucosa lining without ectopic gastric mucosa and the secondary diverticulum had no muscle layer. The patient was discharged home after 5 days without any complications. After 2 weeks, the patient was seen at the surgical outpatient clinic, and he was completely free of any symptoms.

Discussion

Meckel's diverticulum is a true diverticulum of the terminal ileum containing the three layers of the bowel wall and arises from the antimesenteric border of the bowel.

This anomaly is summarized with the 'rule of 2s'. It is seen in 2% of the population and is more common under 2 years of age. There is a 2% incidence of complications. It usually contains 2 types of ectopic mucosa (gastric and pancreatic). It is located 2 feet proximal to the ileocecal valve and its length is 2 inches long (4-5).

Gallstone and foreign body are the most common causes of stones in the small bowel. Stones in the Meckel's diverticulum are very rare which can be explained by stasis (5). Also, the alkaline environment of the small bowel favors stasis (10). Sixty-seven percent of cases were diagnosed with pre-operative imaging, although only 48% of enteroliths were radiopaque. Multiple stones were found in 23.5% of the cases. The average stone size was 3.6 cm, ranging from 2.5 to 6 cm.

The preoperative diagnosis of Meckel enterolith by radiology is rare (7). Meckel enterolith is radio-opaque in about one-third of patients and thus can be determined. Computed tomography, small bowel contrast radiography, angiography, technetium-99m pertechnetate (Tc-99m) scintigraphy, and ultrasonography may be used. **Higginson and Hall** (7) showed that Meckel enterolith can be detected by computed tomography at a high rate. **Park et al.** (6) have evaluated Meckel's diverticulum detected incidentally during laparotomy in a survey done on 1476 patients.

It has been shown that being over fifty years of age, male gender, being longer than 2 cm, and the presence of ectopic or

abnormal structures in the diverticulum were associated with symptomatic diverticula, while the width and width to length ratio of the diverticulum were ineffective factors.

The most important differential diagnosis of Meckel's enterolith is appendicolith. Patients with appendicolith usually present with acute onset, not as Meckel's stones. Small-bowel and barium enema studies will help differentiate one from the other. Meckel's stone ileus could be confused with gallstone ileus; both diseases have a chronic course with superimposed acute small-bowel obstruction.

Many authors suggested resection of incidental Meckel's diverticulum if it is associated with the presence of one of the features associated with symptomatic Meckel's diverticulum. It was also suggested that simple diverticulectomy would be enough in the absence of a mass and surgical margins should be paid attention to in the presence of a palpable mass in the base of Meckel's diverticulum. Although laparoscopic Meckel's diverticulum resection is common, there are no reports of laparoscopic diverticulectomy with the removal of an obstructing enterolith (6).

Conclusions

A complicated Meckel's diverticulum must be expected if an inflammatory process is visualized on CT in the lower abdomen or pelvis, particularly at the midline. If a normal appendix is

identified, the likelihood of this diagnosis increases. Meckel's diverticulum complications present with a wide range of clinical and imaging manifestations, from benign indolent findings to acute life-threatening conditions. Although Meckel's diverticulum may be radiologically diagnosed, laparoscopy and laparotomy are both diagnostic and therapeutic. We highly appreciate the help of the surgical community in documenting and sharing these types of rare cases to overcome the limitations of resources available within the literature.

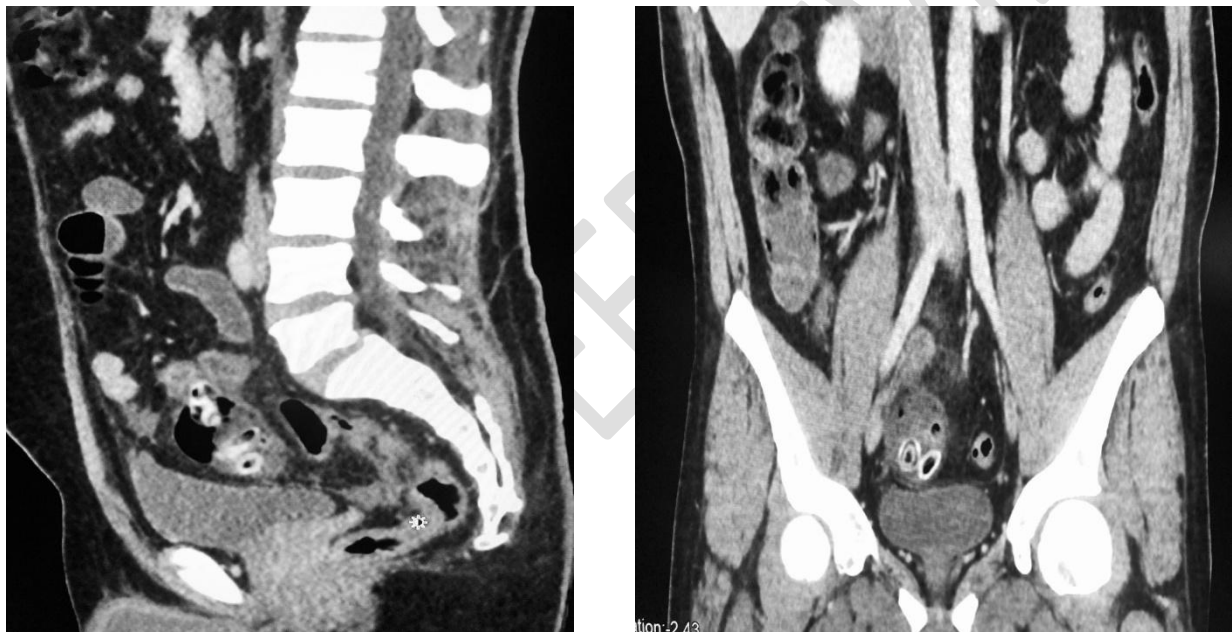

Figure 1 : CT abdomen

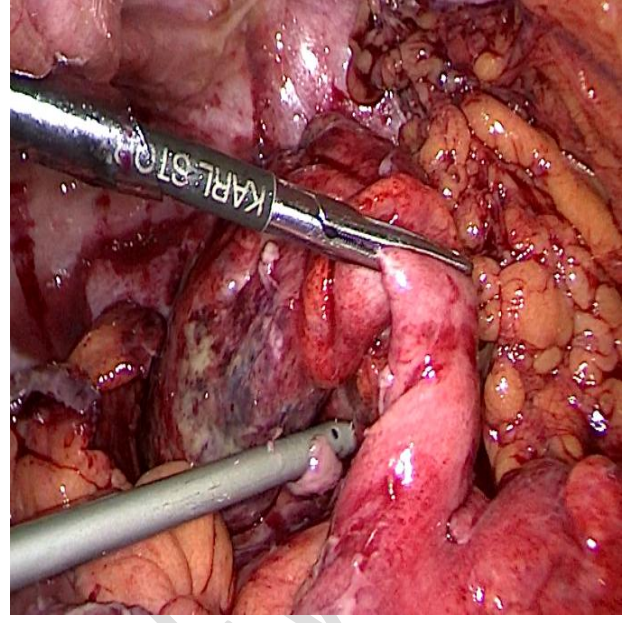
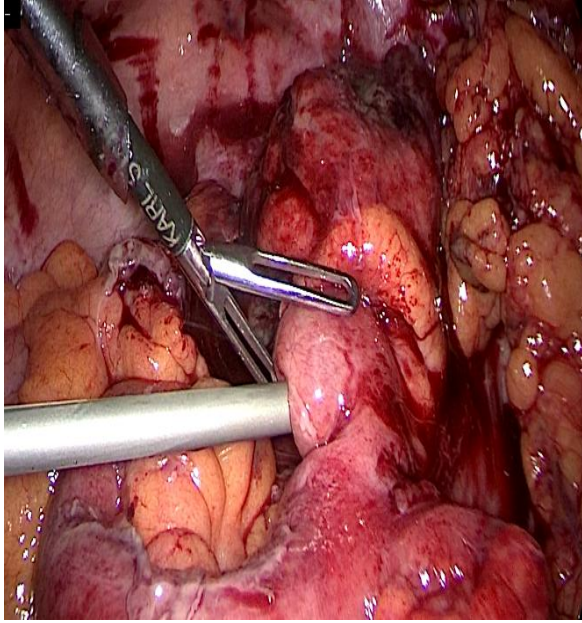


Figure 2 : Laparoscopic viewer

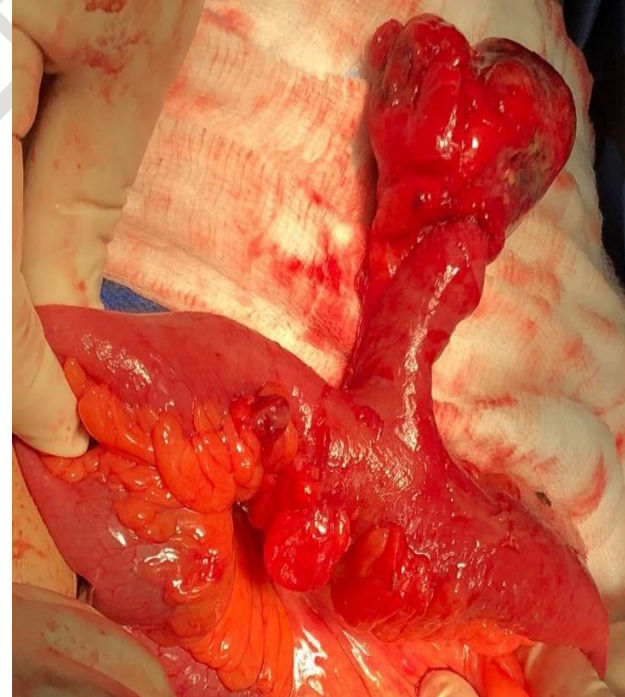
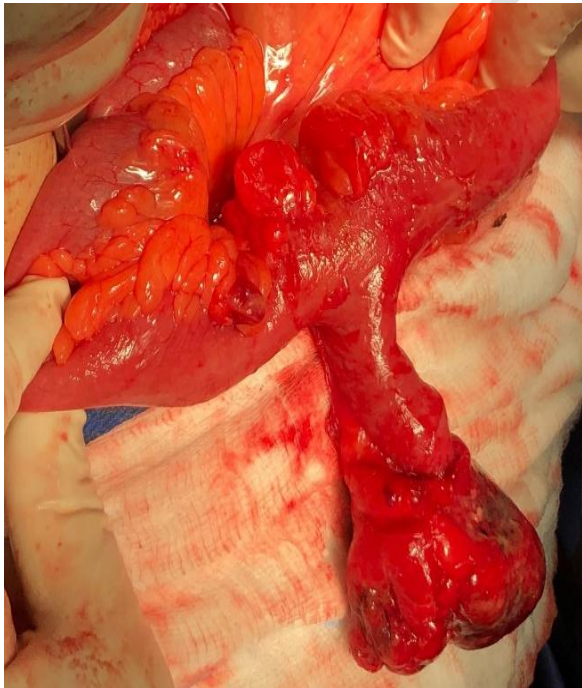


Figure 3 : Laparotomy view

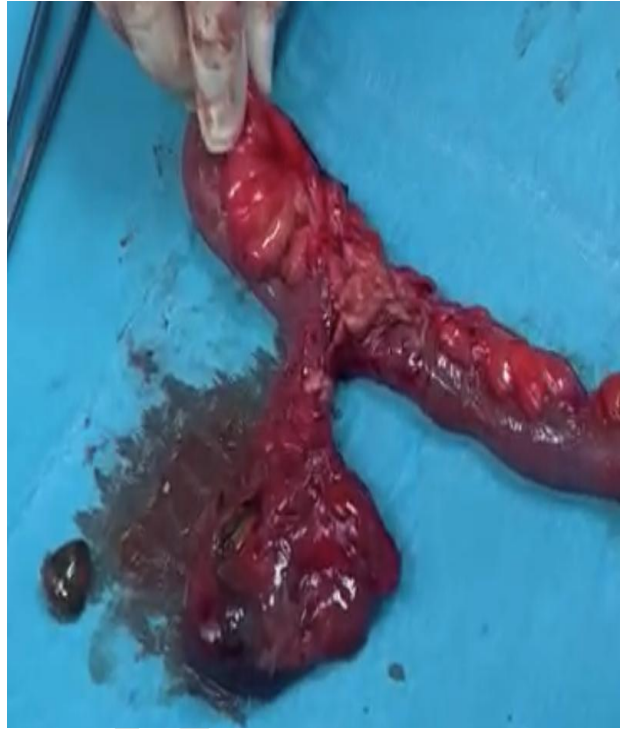
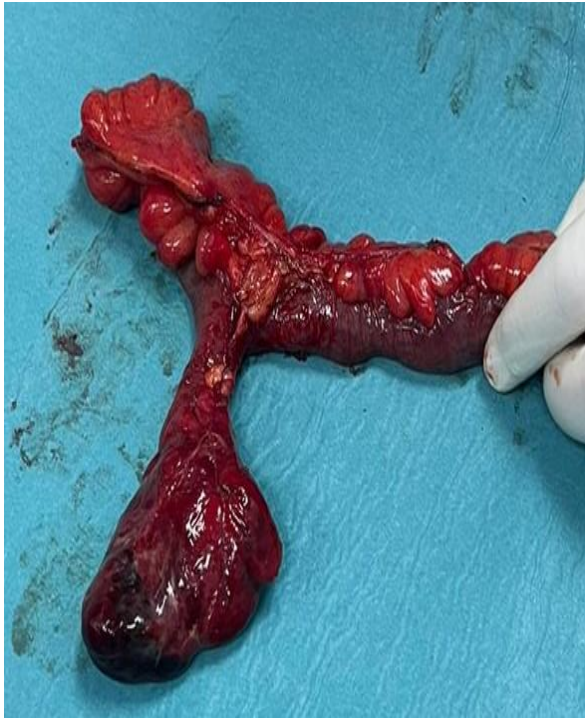
Figure 4 : After resection and exposing one of the stones

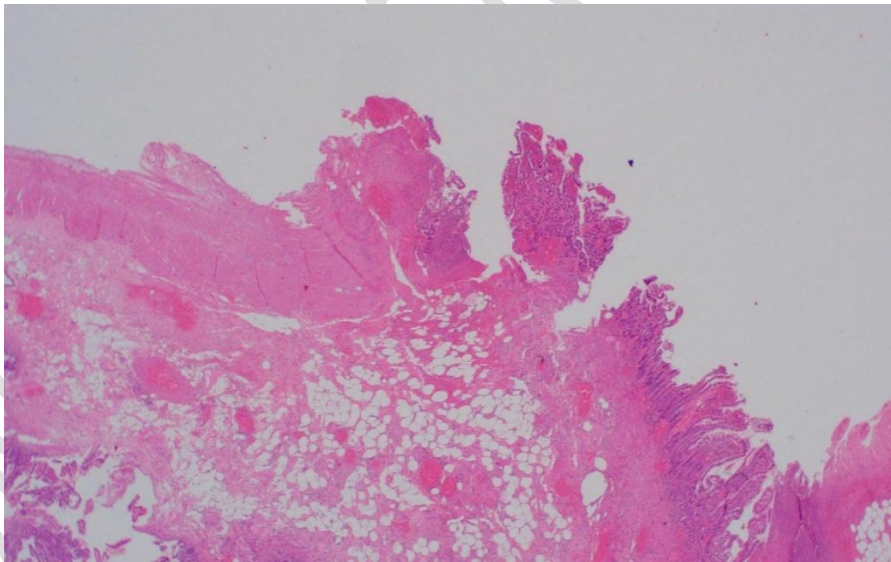


Figure 5:5: The histopathology

References

1. Blouhos K, Boulas KA, Tsalis K, Baretas N, Paraskeva A, Kariotis I, et al. Meckel's diverticulum in adults: surgical concerns. *Front Surg.* [2018;5:55](#)[2018; 5:55](#).
2. Sagar J, Kumar V, Shah DK. Meckel's diverticulum: a systematic review. *J R Soc Med.* [2006;99:501](#)[2006; 99:501](#)–5.
3. Kloss BT, Broton CE, Sullivan AM. Perforated Meckel diverticulum. *Int J Emerg Med.* 2010;3(4):455–7.
4. Bani-Hani KE, Shatnawi NJ. Meckel's diverticulum: comparison of incidental and symptomatic cases. *World J Surg* 2004; 28: 917- 920.
5. Pantongraph-Brown L, Levine MS, Buetow PC, Buck JL, Elsayed AM. Meckel's [enteroliths](#)[;enteroliths;](#) [clinical,radiologic](#)[clinical,](#) [radiologic,](#) and pathologic findings. *Am J Roentgenol* [1996;167:1447](#)[1996; 167:1447](#)–1450.
6. Park JJ, Wolff BG, Tollefson MK, Walsh EE, Larson DR. Meckel diverticulum: the Mayo Clinic experience with 1476 patients (1950- 2002). *Ann Surg* 2005; 241: 529-533.
7. Higginson AP, Hall RI. Meckel's diverticulitis due to an obstructing enterolith: ultrasound and CT appearances. *Clin Radiol* 2001; 56: 593-595.
8. Chan KW. Perforation of Meckel's diverticulum caused by a chicken bone: a case report. *J Med Case Rep.* 2009;3:48.
9. Ozokutan BH, Ceylan H, Yapici S, Simsik S. Perforation of Meckel's diverticulum by a button battery: report of two cases. *Ulus Travma Acil Cerrahi Derg.* 2012;18(4):358–60.
10. Singhal B, Kaval S, Kumar P, Singh C. Enterolithiasis:

An unusual cause of small intestinal obstruction. Arch Int Surg. 2013;3(2):137–41.

UNDER PEER REVIEW