

Retroperitoneal mucocele of the appendix: diagnostic problem

Abstract:

Appendicular mucocele is a rare pathological entity, of variable clinical presentation, often identified incidentally on imaging or during surgical exploration for an unrelated diagnosis. The diagnosis of certainty is mainly anatomic-pathological. We report the case of a 49-year-old female patient with no previous surgical history in whom we discovered this condition in an incidental manner. The clinical presentation was that of an acute appendicular syndrome and revealed a mass in the right iliac fossa. The patient underwent a right hemicolectomy with ileocolic anastomosis and the anatomicopathological study confirmed mucinous adenocarcinoma. The postoperative course was simple.

Keywords: The Appendicular mucocele, Appendiceal mucinous adenocarcinoma, surgery

INTRODUCTION

Appendiceal Mucocele is a rare disease that represents only 0.25% of appendectomy specimens. It is characterized by a progressive appendix dilation due to intraluminal accumulation of mucoid substance and it might be malignant or benign [1]. The clinical picture of this disease is unusual. Appendiceal Mucocele is asymptomatic in 25 to 30% of cases and it manifests by a chronic pain in the right iliac fossa in 70 to 75% of cases. The diagnosis is usually incidental and often is discovered during a radiological or endoscopic examination or during an operation for acute appendicitis[2]. Treatment is usually surgical and it is determined by the integrity of the organ, the size of the base and the histological type of the lesion.

We report a case treated in the Department of Surgery in order to show the diagnostic difficulties of this condition in our practice.

Case report

A 67-year-old woman presents to the emergency room with a sharp pain in the right iliac fossa that began 15 days ago and was associated with nausea, vomiting, and constipation. The patient was febrile, but his vital signs were normal. A 7-cm-diameter mass in the right iliac fossa spreading to the right flank, painful and fixed, was discovered during a clinical examination of the abdomen. An empty rectal ampulla was found during a rectal examination. The cecum lesion had a polylobed shape of 75x67mm on the abdominal CT image, with agglutination of the **gallbladder and micronodular infiltration around it**, as well as thickening of the right iliac muscle with a roughly rounded right formation [figure1]. The appendix was not visible, resulting in an

abscess of the right iliac muscle on the cecum's tumoral process. An emergency operation was performed on the patient. Surgical exploration revealed a burst retrocaecal appendix with mucus discharge in the retroperitoneal area, as well as a 4 cm thickening of the cecum's posterior side, which was non-stenosing and had an abscessed collection [Figure 2, Figure 3]. A right ileo-hemicolectomy was done, With an ileo-colic anastomosis. A mucinous adenocarcinoma of the appendix was discovered in the surgical material, which had permeated the whole caecal wall and reached the peritoneum. The recovery process was uncomplicated.

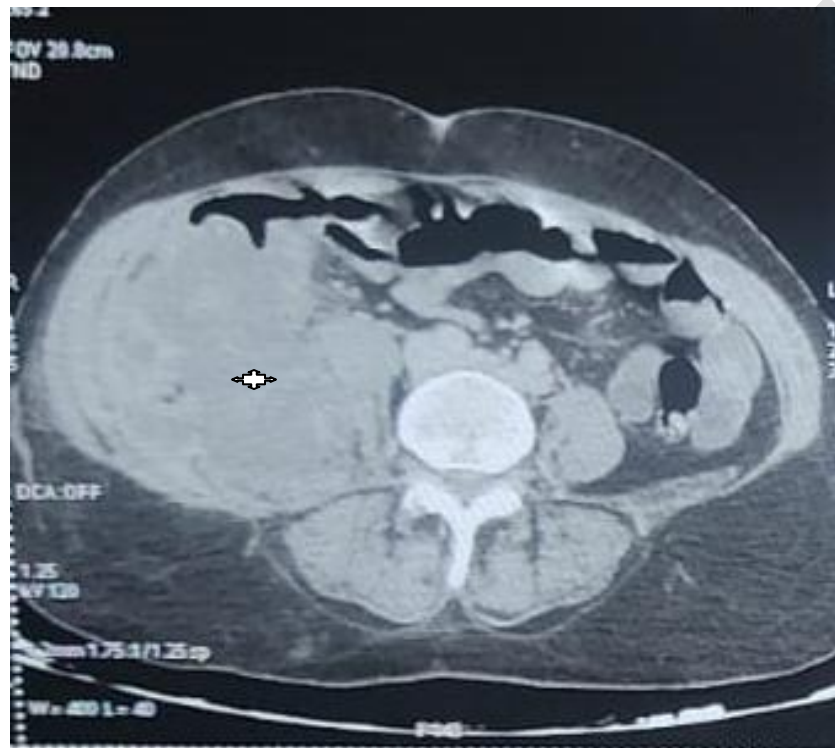

Figure 1: CT appearance of morol process of cecum

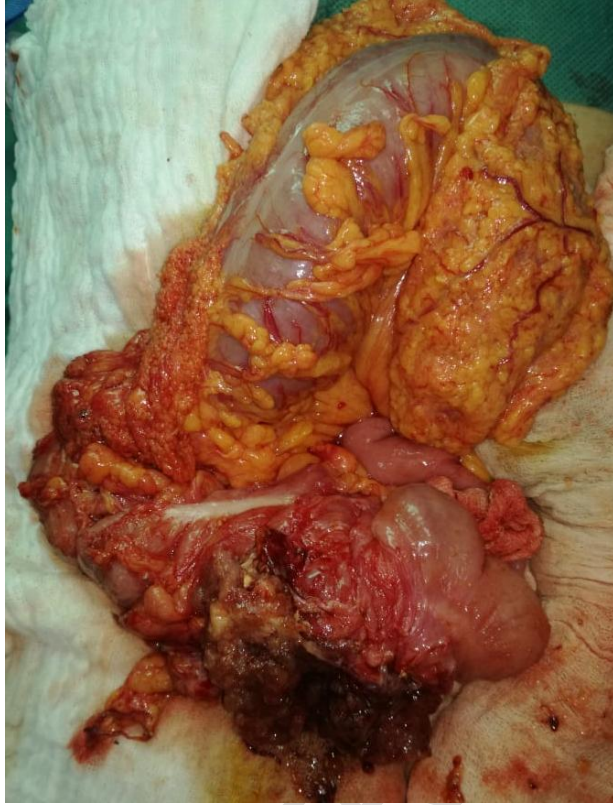

Figure 2: tumor mass of cecum

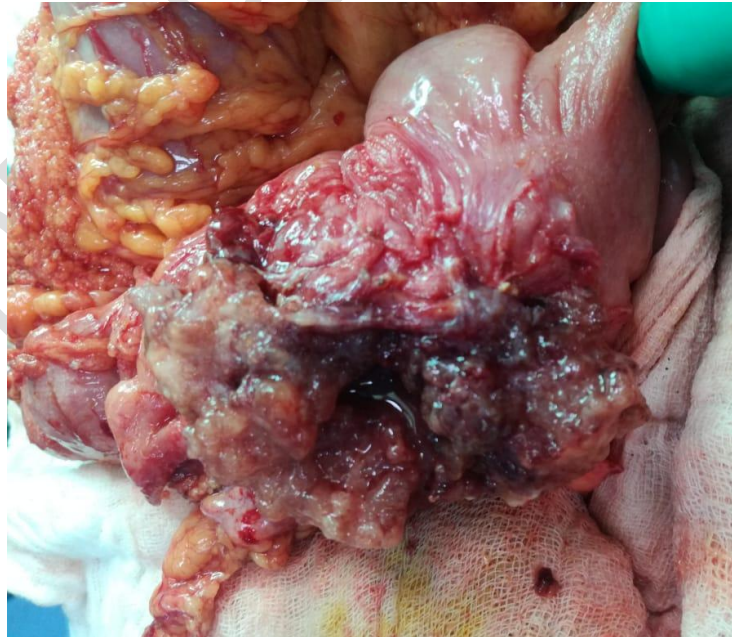


Figure 3: intraoperative image of the cecal tumor mass

Discussion

Appendix mucinous neoplasms are an uncommon and poorly understood heterogeneous condition that affects less than 0.3 percent of appendectomies [3]. Particularly, appendiceal mucinous adenocarcinomas are uncommon, with only 0.2 percent of appendectomies showing mucinous tumors [3]. According to our observations, they are four times more common in women than in males, with an average age of 50 to 60 years [4]. Peritoneal pseudomyxoma is a malignant peritoneal tumor characterized by an effusion of varying size, viscous or mucinous appearance, in the peritoneal cavity. Mucinous appendiceal neoplasms and mucinous adenocarcinomas are the most common causes.

The symptoms aren't very specific clinically. Acute stomach discomfort (which might mimic acute appendicitis) or chronic abdominal pain, abdominal mass, or weight loss are all possibilities. As a result, a clinical examination alone is insufficient to confirm a diagnosis of appendiceal mucinous neoplasm [5]. In half of the cases, mucinous tumors of the appendix appear on an abdominal scan with signs of appendicitis or as a well-encapsulated cystic mass with mural calcification [6].

The treatment is surgical, the interest of which is to respect the carcinogenic criteria of resection in order to avoid perforation of the tumor. The treatment of appendicular tumors for many years has been appendectomy (for tumors less than 2 cm) and right hemicolectomy (for tumors greater than 2 cm), although in situations where total resection of the primary tumor cannot be achieved by simple or radical appendectomy, where tumor lymph node involvement is found, right hemicolectomy is recommended as the standard procedure [7]. Mucinous adenocarcinomas are frequently greater than 4 cm in diameter and, in 50% of cases, metastatic to the peritoneum [8].

As a result, whether the tumor has progressed, the degree of malignancy, and the existence of a peritoneal pseudomyxoma all have a role in the prognosis of appendix mucinous adenocarcinoma [9]. The formation of peritoneal pseudomyxoma and physical indications of likely infiltration surrounding the abdominal organs imply a poor prognosis [10]. If the patient has limited clinical symptoms and no evidence of infiltration or dissemination of surrounding tissue, complete removal of the appendix tissue can considerably extend the life span [11].

Conclusion:

The retroperitoneal appendix mucocele is a somewhat uncommon condition. When an atypical appendicular syndrome or a right iliac fossa tumor is present, they should be considered. Before

surgery, it's crucial to have an accurate radiological preoperative diagnosis based on a CT scan to avoid major intraoperative and postoperative problems that might affect the patient's prognosis.

Reference

1. MEYER, Jérémy, BALAPHAS, Alexandre, KOESSLER, Thibaud, *et al.* Les tumeurs de l'appendice et leur prise en charge. *Revue médicale suisse*, 2018, p. 1225-1229.
2. Lu Y, Li F, Ma R, Fang L, Qi C. Clinicopathological Features of Low-Grade Appendiceal Mucinous Neoplasms Confined to the Appendix. *Front Oncol.* 2021;11:696846.
3. B.B. SK, Jasuja P. Appendiceal mucocele—A rare case report. *Int J Surg Case Rep.* 9 avr 2019;58:21-5.
4. Wakunga E, Mukuku O, Bugeme M, Tshiband M, Kipili A, Mobambo P, et al. Mucocèle appendiculaire: à propos d'un cas observé à Lubumbashi. *Pan Afr Med J.* 9 mai 2014;18:36.
5. Teixeira FJR, Couto Netto SD do, Akaishi EH, Utiyama EM, Menegozzo CAM, Rocha MC. Acute appendicitis, inflammatory appendiceal mass and the risk of a hidden malignant tumor: a systematic review of the literature. *World J Emerg Surg.* 9 mars 2017;12(1):12.
6. Cestino L, Festa F, Cavuoti G, Bonatti L, Soncini S, Dani L, et al. Appendiceal mucocele: three cases with different clinical presentation and review of literature. *J Surg Case Rep.* sept 2020;2020(9):rjaa344.
7. Chirca A, Negreanu L, Iliesiu A, Costea R. Mucinous appendiceal neoplasm: A case report. *World J Clin Cases.* 6 mars 2021;9(7):1728-33.
8. Aggarwal N, Bhargava A. Appendiceal mucocele secondary to torsion in an asymptomatic patient. *J Surg Case Rep.* 14 août 2019;2019(8):rjz241.
9. Aleter A, El Ansari W, Toffaha A, Ammar A, Shahid F, Abdelaal A. Epidemiology, histopathology, clinical outcomes and survival of 50 cases of appendiceal mucinous neoplasms: Retrospective cross-sectional single academic tertiary care hospital experience. *Ann Med Surg.* 1 avr 2021;64:102199.
10. Kang DW, Kim B hui, Kim JM, Kim J, Chang HJ, Chang MS, et al. Standardization of the pathologic diagnosis of appendiceal mucinous neoplasms. *J Pathol Transl Med.* juill 2021;55(4):247-64.
11. Demiral G, Çolakoğlu MK, Kalcan S, Özdemir A, Pergel A. Mucinous Neoplasms of the Appendix: Our Clinical Experience and Review of the Literature. *Turk J Colorectal Dis.* 1 sept 2019;29(3):127-32.