

Case study

1
2
3
4
5
6
7
8
9
10
11
12
13
14
15
16
17
18
19
20
21
22
23
24
25
26
27
28
29
30
31
32
33
34

BILATERAL VARICOCELE CO-EXISTING WITH SUB-ACUTE APPENDICITIS : A CASE REPORT

ABSTRACT

Introduction

The diagnosis of bilateral varicocele and sub-acute appendicitis co-existing in the same patient is rare and we report the management of a patient who presented to Lily Hospitals Limited, Warri, Delta State, Nigeria with both recurrent right iliac fossa pain and scrotal pain.

Case presentation

A 27 year old male who presented with recurrent scrotal pain of 3 years duration and recurrent right iliac fossa pain of 2 years duration. Following evaluation, the diagnosis of bilateral varicocele and sub-acute appendicitis was made and he subsequently had open bilateral inguinal varicocelectomy and open appendicectomy at the same sitting under regional anaesthesia. He had uneventful post-operative recovery and was subsequently discharged.

Conclusion

A thorough evaluation of patients presenting with scrotal and right iliac fossa pains is invaluable to avoid missing the diagnosis of both bilateral varicocele and appendicitis when they co-exist in the same patient.

Keywords: Varicocele, sub-acute appendicitis, pain, bilateral

INTRODUCTION

The presentation of recurrent scrotal pain and right iliac fossa pain resulting from two different pathologies and occurring in the same patient at similar time is uncommon with the report of such rare in the literature. Commonly seen are patients presenting with either scrotal pains or right iliac fossa pains resulting from either varicocele or appendicitis respectively.

Varicocele is the dilation of veins of the pampiniform plexus draining the testis. Appendicitis is the inflammation of the appendix, symptoms include right lower abdominal pain, nausea, vomiting and decreased appetite¹. Sub-acute appendicitis is part of the non-acute variants of appendicitis.

We report the management of a 27 year old male who presented to our facility with complaints of right iliac fossa pain and scrotal pain.

Comment [m1]: English-the sentence doesn't make sense. I don't understand what does the author wants to explain.

Comment [m2]: What is iliac fossa pain and scrotal pain. Can you explain better to understand whether they happened at the same time during patient inflammation.

35 **CASE PRESENTATION**

36 A 27 year old male who presented to the Urology Clinic, Lily Hospitals Limited, Warri, Delta State,
37 Nigeria with complaints of recurrent scrotal pains of 3 years duration and right iliac fossa pain of 2 years
38 duration. Scrotal pain was insidious in onset, dull aching, does not radiate to any part of the body, not
39 worse at any time of the day, no known aggravating or relieving factors, not associated with scrotal
40 swelling, lower urinary tract symptoms, urethral discharge or haematuria. The right iliac fossa pain was
41 insidious in onset, colicky, does not radiate to any part of the body, aggravated by strenuous activities
42 and cough, no known relieving factors, not associated with fever, anorexia, nausea, vomiting or
43 abdominal distension. There was no past history of surgery and he was not allergic to any medications.

44 Physical examination revealed right iliac fossa tenderness with positive Rovsing's sign and bilateral grade
45 2 varicoceles.

46 Investigations requested were Scrotal Doppler ultrasound scan that revealed bilateral dilated
47 pampiniform plexus of veins above 3 millimeters in keeping with varicoceles (fig 1) Abdominal ultrasound
48 scan that revealed sub-acute appendicitis (fig 2) Urinalysis that was normal with normal Full blood count,
49 Serum electrolytes, urea and creatinine. The diagnosis of bilateral varicocele with subacute appendicitis
50 was made.

51 He subsequently had bilateral Open Inguinal Varicocelectomy and Open Appendicectomy done by the
52 Consultant Urologist and General Surgeon respectively at the same sitting under regional anaesthesia.

53 Intraoperative findings were bilateral dilated pampiniform plexus of veins and retroileal inflamed
54 appendix measuring about 12 centimeters (fig 3) He had uneventful post-operative recovery and was
55 discharged home 3 days after surgery. He is currently on follow up visit with complete resolution of both
56 right iliac fossa pain and scrotal pain.

57 Histopathology report of the resected appendix revealed lymphoid follicular hyperplasia with no
58 evidence of malignancy while that of the resected varicocele segment revealed features consistent with
59 varicocele

60 **DISCUSSION**

61 The presentation of distinct scrotal pains and right iliac fossa pains occurring in the same patient at the
62 same time is not common with paucity of data reporting such findings. Varicoceles may begin with the
63 onset of puberty at around the age of 15 years², most are left sided and left sided predominance is
64 explained by turbulent venous flow related to the right angle insertion of the left testicular vein into the
65 left renal vein³. Varicocele is a physical abnormality present in 11.7% of men with normal semen
66 analysis and 25.4% of men with abnormal semen⁴. Varicocele can lead to male infertility, scrotal
67 swelling or pain and progressive ipsilateral testicular atrophy as complications. Our index patient
68 presented with the complication of scrotal pain and had treatment for that. The exact relationship
69 between reduced male fertility and varicocele is unknown but a meta-analysis showed that semen
70 improvement is usually observed after surgical correction⁵. Varicoceles are graded according to the
71 Dublin grading system from grades 1 to 3⁶. Our patient had bilateral grade 2 varicoceles. The surgical
72 correction of varicocele was first described by Tulloch in 1952⁷. The surgical treatment for varicocele can
73 be done open or laparoscopically and our index patient had an open surgical treatment.

Comment [m3]: Again the English writing is so poor.

Comment [m4]: Did patient took any medicine over the last 3 years.

Comment [m5]: Fixed the writing

Comment [m6]: When this happened, before or after surgery

Comment [m7]: Repeating the sentence from introduction. Can you rephrase the sentence.

Comment [m8]: In CASE PRESENTATION author did not explain the relationship between the disease onset and male fertility. Can you present whether the patient has any problem with male fertility or less semen etc.

74 Appendicitis is the most common acute surgical condition of the abdomen⁸, with a lifetime occurrence
75 of 7%⁹. The diagnosis of appendicitis is mainly clinical but when unclear, close observation, medical
76 imaging and laboratory tests can be helpful¹⁰. The two most common imaging modalities used for the
77 diagnosis of appendicitis are abdominal ultrasound scan and abdominal computerized tomography
78 scan¹⁰. Our index patient had abdominal ultrasound scan during the initial evaluation although the
79 diagnosis was clear earlier from the clinical evaluation. In 1889, Mc Burney published a series of reports
80 on appendicitis and the therapeutic management and since then, appendicectomy has been the
81 standard treatment for uncomplicated appendicitis¹¹. Appendicectomy can be done open or
82 laparoscopically and our index patient had open appendicectomy.

83

84

85 **CONCLUSION**

86 The diagnosis of both bilateral varicoceles and appendicitis in the same patient occurring around the
87 same time is rare. Thorough clinical evaluation is thus pertinent during evaluation of patients presenting
88 with right iliac fossa pain and scrotal pain to avoid missing such pathologies when they co-exist in the
89 same patient.

90

91

92

93

94

95

96

97 **DECLARATIONS**

98 **Ethical approval**

99 Not applicable

100 **Consent to participate**

101 A written consent was signed by the patient

102 **Consent for publication**

103 Not applicable

104 **Availability of data and material**

105 Not applicable

106

107 **REFERENCES**

- 108 1. Graffeo CS, Counselman EL. Appendicitis. *Emergency Medicine Clinics of North America* 1996;
109 14: 653-71
- 110 2. Steeno O, Knops J, Declerck L, Adimoelja A, Vande Voorde H. Prevention of Fertility Disorders by
111 Detection and Treatment of Varicoceles at School and College Age. *Andrologia* 1976; 8: 47-53
- 112 3. Sabanegh E, Agarwal A. Male Infertility. In: Wein AJ, Kavoussi LR, Novick AC, Partin AW, eds.
113 *Campbell-Walsh Urology*. 10th ed. Philadelphia: Saunders, Elsevier Inc; 2012. Pp 636-637
- 114 4. Said S, Aribarg A, Virutamsen P, Chutivongse S, Koetsawang S, Meherjee P, et al. The Influence
115 of Varicoceles on Parameters of Fertility in a Large Group of Men Presenting to Infertility Clinics.
116 *Fertility and sterility* 1992; 57: 1289-93
- 117 5. Agarwal A, Deepinder F, Cocuzza M, Agarwal R, Short R, Sabanegh E, et al. Efficacy of
118 Varicocelectomy in Improving Semen Parameters: New Meta-analytical Approach. *Urology*
119 2007; 70: 532-38
- 120 6. Hirsh AV, Cameron KM, Tyler JP, Simpson J, Pryor JP. The Doppler Assessment of Varicoceles and
121 Internal Spermatic Veins Reflux in Infertile Men. *British Journal of Urology* 1980; 52: 50-56
- 122 7. Tulloch WS. A Consideration of Sterility Factors in the Light of Subsequent Pregnancies.11.Sub
123 fertility in the male. *Edinburgh Med J* 1952; 59: 29-34
- 124 8. Liu CD, Mc Fadden DW. Acute Abdomen and Appendix. In: Greenfield LJ, Mulholland MW,
125 Oldham KT, Zelenock GB, Lillemoe KD, eds. *Essentials of Surgery: Scientific Principles and*
126 *Practice*. 2nd ed. Philadelphia: Lippincott-Raven, 1997. Pp 1246-61
- 127 9. Hardin M. Acute Appendicitis: Review and Update. *Am Fam Physician* 1999; 60:2027-34
- 128 10. Paulson EK, Kalady MF, Pappas TN. Clinical Practice. Suspected Appendicitis. *New England*
129 *Journal of Medicine* 2003; 348: 236-42
- 130 11. Mc Burney C. Experiences with Early Operative Interference in Cases of Disease of the
131 Vermiform Appendix. *NY Med J* 1889; 50:1676-84

132

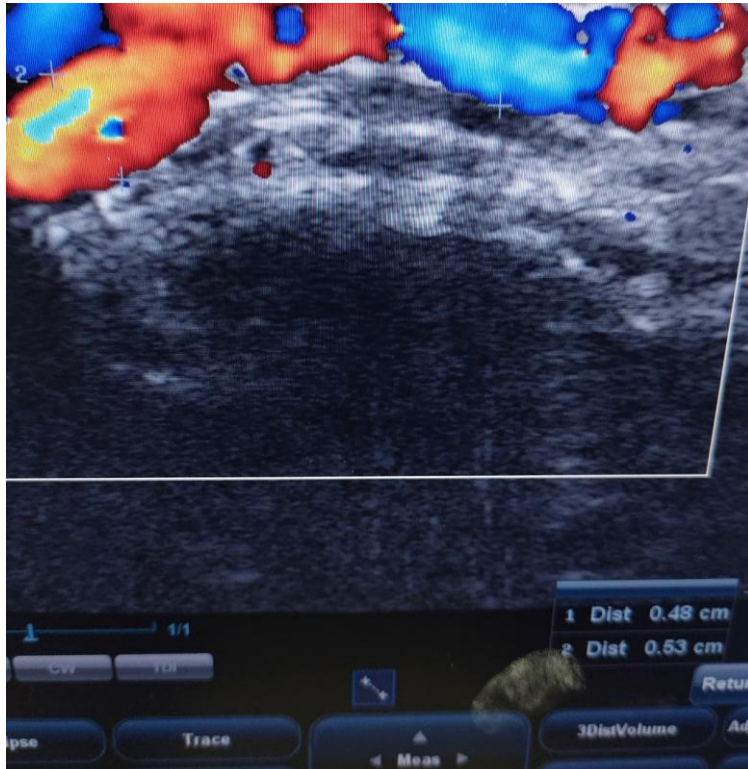
133

134

135

136

137



138

139

140

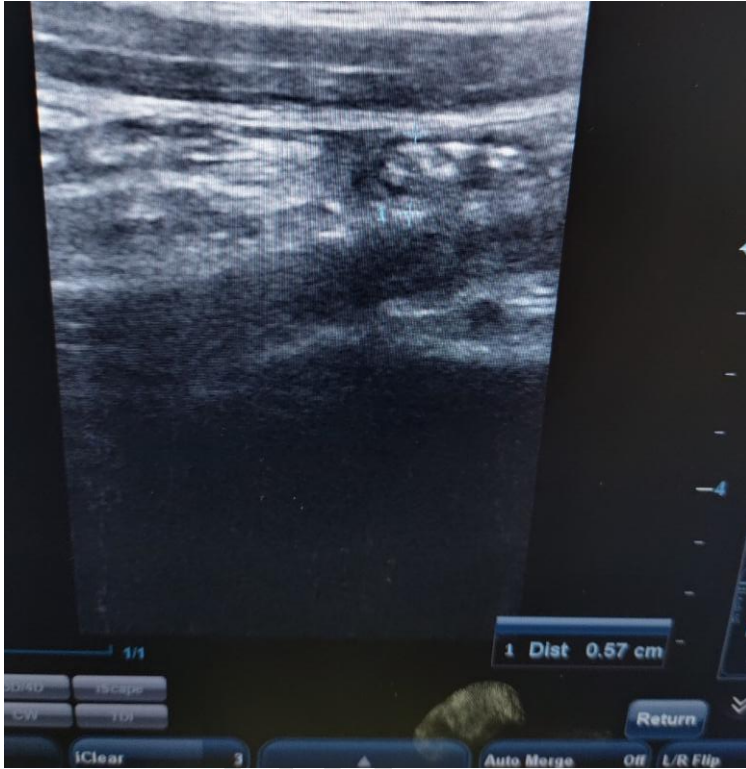141

142

143

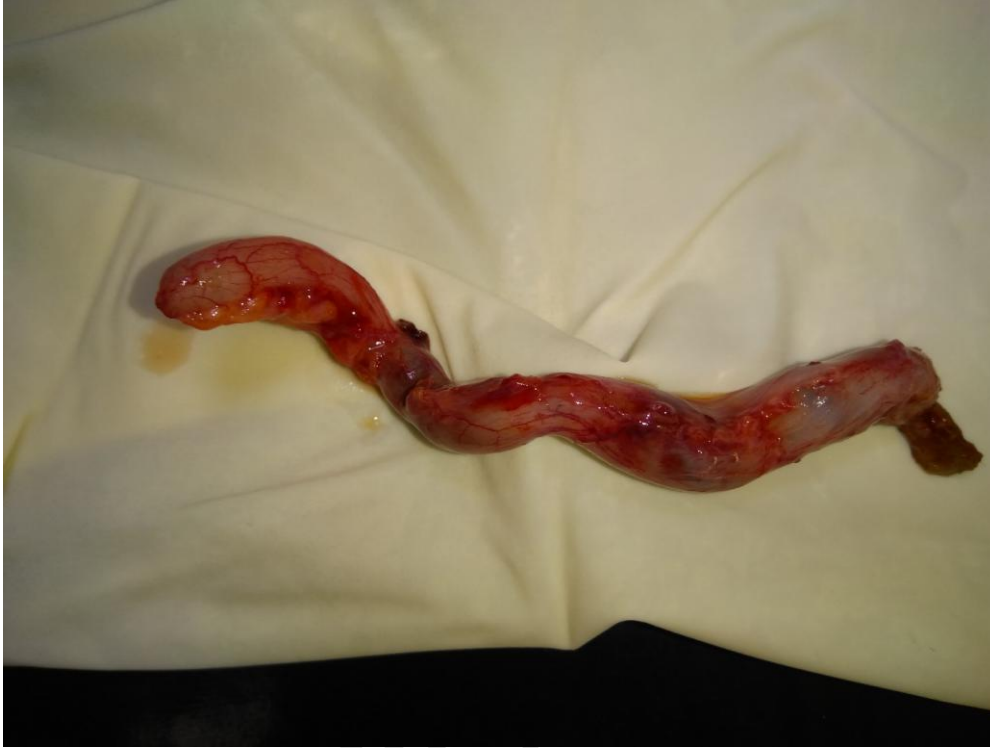144

Fig 1: Scrotal Doppler Ultrasound scan revealing dilated pampiniform plexus of veins



145
146
147
148
149
150
151
152
153
154
155

Fig 2: abdominal ultrasound scan revealing inflamed appendix



156

157 **Fig 3: Resected Appendix Specimen**

158

159

160

161

162

163

164

165

166

167

168