

Case study

Subclavian artery aneurysm in a HIV infected patient - Case report.

Abstract

Aim:

To highlight the presentation and endovascular management of a leaking subclavian artery aneurysm in a patient with human immunodeficiency virus infection.

Background:

The presentation of human immunodeficiency virus infection and its complications continue to be an ever-evolving diagnostic challenge for physicians all over the globe. Patients in the younger age group with de novo peripheral arterial aneurysms occasionally present with alarming complications. Subclavian artery aneurysm is one such entity which can be treated successfully with endovascular techniques.

Case Description:

45 yr. old diabetic female patient initially treated for upper respiratory tract infection later presented with a swelling in the right lower neck region. The cervical lymph node biopsy and blood tests confirmed positive for human immunodeficiency virus. She had spontaneous bleeding from the neck region and an urgent angiography revealed a leaking aneurysm at the origin of the right subclavian artery. This was treated with endovascular technique by using a covered stent and also sealing the retrograde flow from the vertebral artery.

Conclusion:

In the setting of bleeding in young patients with peripheral arterial non-traumatic aneurysms, endovascular management is the most efficient modality of treatment. The use of covered stents and percutaneous approach ensures a rapid recovery and avoids post-operative wound related complications.

Clinical Significance:

The aforementioned case will allow an improved clinical acumen and permit the early diagnosis of arterial aneurysms in the head and neck region. The highlighted endovascular treatment option may be used as a first line approach for treatment with the availability of required equipment and local expertise.

Keywords : Subclavian artery, peripheral aneurysm, endovascular

Background:

The vascular complications in human immunodeficiency virus (HIV) infected patients are well recognised and include vasculitis, large vessel occlusive disease and aneurysms. Among the peripheral arteries, subclavian artery aneurysms are a rare clinical entity occurring in less than 1% of the population¹. This case report highlights a rare occurrence of a subclavian artery aneurysm in a HIV infected patient which was entirely treated by the endovascular approach.

Case Description:

A 45 yr old diabetic female presented to our hospital with fever and chills of 3 days duration. She was initially treated with antibiotics and discharged with a provisional diagnosis of upper respiratory tract infection. She presented 3 weeks later with recurrent fever, pain and swelling in the right lower neck region. The ultrasound of the neck showed a cervical abscess and lymphadenopathy. The CT scan demonstrated a loculated pneumo-mediastinum in the superior mediastinum along with multiple enlarged lymph nodes. An excision biopsy of the cervical lymph node reported an acute on chronic inflammation with no granuloma or malignancy. The blood culture had a growth of Salmonella species. She was found to have an ELISA test positive for HIV with an absolute CD4 count of 182/mm³. This diagnosis was confirmed with HIV PCR. The patient developed spontaneous bleeding from the neck region with a haemoglobin fall of 3 g% and hypotension with shock. After an initial resuscitation with 3 units packed red blood cell transfusion, the patient was taken for an emergency endovascular repair. With a right femoral approach using 10F sheath a digital subtraction angiography image showed a leaking aneurysm at the right subclavian artery origin. The carotid, vertebral and internal mammary arteries were in close proximity to the aneurysm (Fig 1).

Comment [KM1]: I suggest you clarify that it was not COVID-19.

Comment [KM2]: ??

12 x 60 mm Fluency covered stent was deployed across the origin of the subclavian artery. This was post dilated with 10_x_4 mm balloon (Fig 2). The check angiogram showed occlusion of the subclavian artery aneurysm. However, the right vertebral artery was still feeding the aneurysm retrogradely. At this stage, a second access was used through the right brachial artery with a 6F shuttle sheath. An 8 x 10 mm Patent Ductus Arteriosus (PDA) occluder device was deployed to block the retrograde filling of the aneurysm (Fig 3). The end result was a complete exclusion of the subclavian artery aneurysm with a patent vertebral and internal mammary artery.

There were no symptoms of subclavian steal with a recorded blood pressure of 90/60 mmHg on right arm and 110/70 mmHg on the left arm. The patient was discharged after 3 days with antibiotics, antiplatelets and antiretroviral drugs. She has been on regular follow up of 1 and 3 months and has no further symptoms related to this intervention (Fig 4).

Discussion:

Arterial aneurysms in a HIV patient were first reported in Zimbabwe in 1989². They constitute a distinct clinical and pathological entity. They occur as multiple aneurysms in relatively young patients. The predilection for these aneurysms is in atypical sites such as the carotid and superficial femoral artery. They have a possible infective or immune complex origin. There is focal lymphoplasmacytic infiltration of small nerve fibres and vasa vasora of the vessel wall. The microbial studies show polymicrobial growth although positive cultures are seen in only 25% of cases.

Comment [KM3]: Reference?

There have been only 4 cases of subclavian artery aneurysms reported in HIV infected patients so far. Two of these patients were treated by open surgery and only one was treated with endovascular approach^{3,4}. Open surgery is the classic technique for treatment of subclavian artery aneurysms. The surgical approach to the extra thoracic subclavian artery aneurysm is often feasible through the combined supra and infraclavicular incisions.

In our patient the entire treatment was completed with a combined endovascular femoral and brachial access. We were able to gain hemodynamic stability by the prompt repair of the leaking aneurysm. The further use of a PDA occluder device enabled us to achieve a complete exclusion of the aneurysm. Since the open operative wounds were avoided, the post-operative recovery was uneventful. Endovascular repair being less invasive and well tolerated may be therefore more justifiable in patients with advanced HIV infection.

Clinical Significance:

This case report highlights the occurrence of aneurysms in the head and neck region which can occasionally present with bleeding. If the equipment and local expertise is available then the use of minimally invasive techniques can give excellent clinical outcomes.

References:

1. Pairolero PC, Walls JT, Payne WS, Hollier LH, Fairbairn JF 2nd. Subclavian-axillary artery aneurysms. *Surgery* 1981;90(4):757-763.
2. Sinzobahamvya N, Kalangu K, Hämel-Kalinowski W. Arterial aneurysms associated with human immunodeficiency virus (HIV) infection. *Acta Chir Belg* 1989;89:185-8.
3. Marks C, Kuskov S. Pattern of arterial aneurysms in acquired immunodeficiency disease. *World J Surg* 1995;19:127-32.
4. Nair R, Abdool-Carrim ATO, Chetty R, Robbs JV. Arterial aneurysms in patients infected with human immunodeficiency virus: a distinct clinicopathology entity? *J Vasc Surg* 1999;29:600-7

5. Kedora J, Grimsley B, Pearl G. Endovascular treatment of an aberrant right subclavian artery aneurysm with use of the Zenith iliac plug. Proc (Bayl Univ Med Cent) 2009-Apr;22(2):144–145.
6. May J, White G, Waugh R, Yu W, Harris J. Transluminal placement of a prosthetic graft-stent device for treatment of subclavian aneurysm. J Vasc Surg 1993;18:1056–1059.

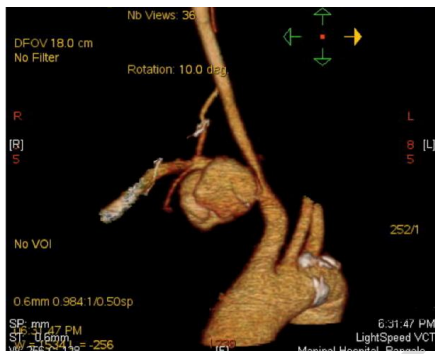


Fig 1: Pre-operative diagnostic imaging

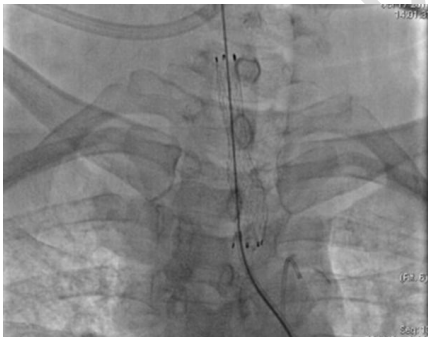


Fig 2: Deployment of stent across the Subclavian artery

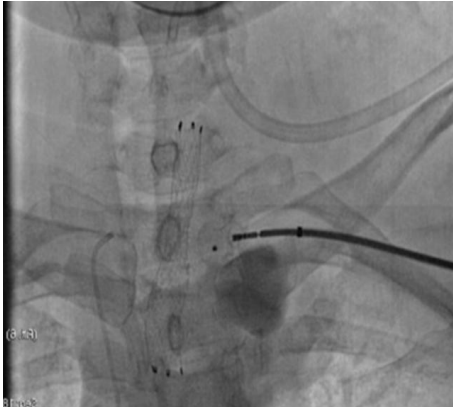

Fig 3: Deployment of the PDA occlusion device to prevent retrograde filling of the aneurysm.

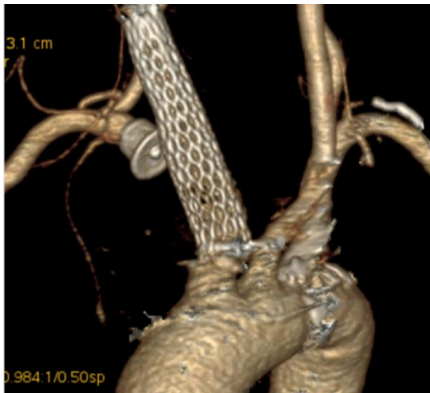


Fig 4: CT Angiogram done in the follow up period shows complete exclusion of the aneurysm.