

Case study

Pneumoperitoneum resulting from severe Coronavirus Disease 2019 (COVID-19) Pneumonia

ABSTRACT

Introduction: Pneumoperitoneum is considered a surgical emergency, as it is highly associated with abdominal viscus perforation. Pulmonary origin of pneumoperitoneum secondary to invasive mechanical ventilation in severe COVID-19 pneumonia has been rarely reported in the existing literature.

Presentation of case: A 62-year-old female was diagnosed with stage 5 COVID-19 pneumonia, and was intubated due to respiratory distress. She subsequently developed pneumomediastinum, pneumothorax, subcutaneous emphysema, and pneumoperitoneum a few days post-intubation. However, there was no radiological evidence of abdominal viscus perforation from a computed tomography (CT) scan. Coupled with clinical findings and blood investigation, the patient was managed non-surgically with bilateral chest tubes and close monitoring of the intra-abdominal pressure. The pneumoperitoneum resolved a few days later. However, the patient continued to deteriorate throughout her stay at the ICU, due to concurrent nosocomial sepsis with kidney failure. Ultimately, the patient passed away on day 14 of her hospital stay.

Discussion: The management of pulmonary origin of pneumoperitoneum is mainly conservative with close observation of intra-abdominal pressure. Unnecessary non-therapeutic laparotomy of such a condition will potentially increase the mortality and morbidity of critically-ill COVID-19 patients.

Conclusion: Pneumoperitoneum resulting from severe COVID-19 pneumonia should be managed non-operatively, provided there is clear evidence of the absence of viscus perforation. A radiological examination, coupled with clinical findings and blood investigation, is crucial in establishing an accurate diagnosis.

Keywords: pneumoperitoneum; pneumomediastinum; mechanical ventilation; COVID-19

1. INTRODUCTION

Pneumoperitoneum is an abnormal presence of air in the peritoneal cavity, and is commonly treated as a surgical emergency associated with abdominal viscus perforation [1]. Pneumomediastinum causing non-surgical aetiology of pneumoperitoneum in an invasive mechanical ventilated COVID-19 patient is a rare clinical entity in the literature. Herein, we present such a case, which was managed conservatively with close observation. Non-therapeutic laparotomy will lead to higher rates of morbidity and mortality. Details of the case, including clinical presentation, imaging, and management were discussed to alert surgeons and clinicians of such a rare condition.

2. PRESENTATION OF CASE

A 62-year-old female presented with shortness of breath associated with lethargy, poor appetite, and cough for five days. Her co-morbid condition involved poorly-controlled diabetes mellitus, hypertension, and dyslipidemia. On presentation, she appeared lethargic and tachypneic, with a respiratory rate of 32 breaths per minute, and an oxygen saturation (spO₂) of 88-90% under ambient air. A chest X-ray showed bilateral ground-glass opacity, primarily affecting the periphery and basal regions of both lungs (Fig. 1). Blood work showed acute kidney failure with raised C-reactive protein 124mg/L. A nasopharyngeal swab test for severe acute respiratory syndrome coronavirus 2 (SARS-CoV-2) was positive. Diagnosis of stage 5 coronavirus disease 2019 (COVID-19) pneumonia was established, and multi-modal treatments were initiated.

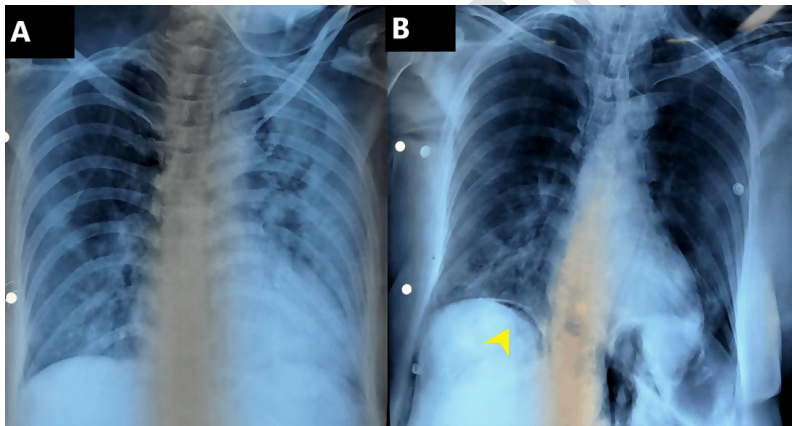


Figure 1: (A) Bilateral ground-glass opacity mainly affects both lungs periphery and basal region. (B) Subcutaneous emphysema at the left supraclavicular region with linear lucency outlining mediastinal and pericardium (pneumomediastinum and pneumopericardium) and air under the diaphragm (pneumoperitoneum –arrowhead)

Subsequently, she was intubated and admitted to the intensive care unit (ICU). Over the next four days, the patient's respiratory support gradually increased and she had multiple desaturation episodes. She was nursed in the prone position and the ventilation setting was set to high (fraction of inspired oxygen 0.8 with positive end-expiratory pressure 10), in order to maintain adequate oxygenation. She developed subcutaneous emphysema over the neck and chest. The presence of pneumomediastinum, pneumoperitoneum, and subcutaneous emphysema were seen in a repeated chest X-ray (Fig. 1). Perforated abdominal viscus was suspected. Hence, an urgent computed tomography (CT) scan of the

thorax and abdomen revealed diffuse ground glass densities in both lungs with pneumomediastinum, pneumothorax, and concurrent pneumoperitoneum, without evidence of perforated viscus (Figs. 2, 3). Two chest tubes were inserted for bilateral pneumothorax. The patient was managed non-operatively, given the lack of clinical and radiological findings of visceral perforation. There was a resolution of the pneumoperitoneum a few days later (Fig. 4). However, the patient continued to deteriorate throughout her stay at the ICU, due to concurrent nosocomial sepsis with kidney failure. Ultimately, the patient passed away on day 14 of her hospital stay.

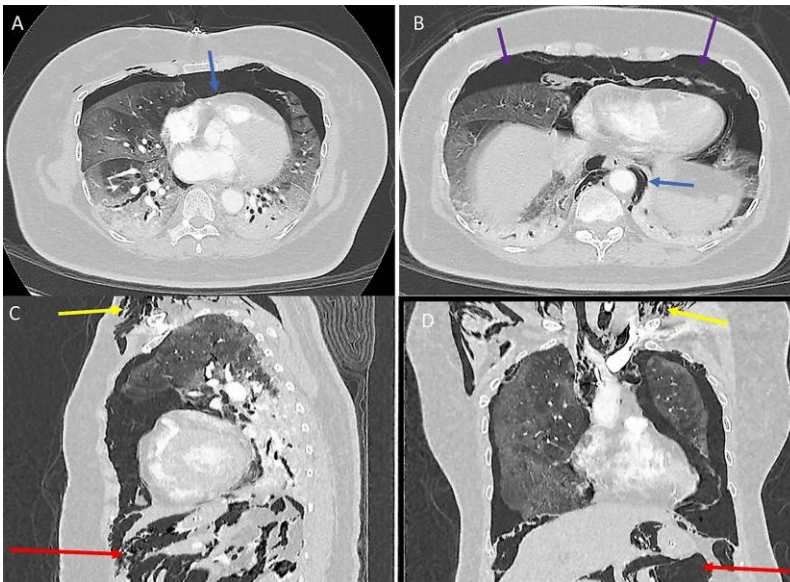


Figure 2: Axial images (A, B), sagittal reconstruction (C), and coronal reconstruction (D) of CT Thorax shows extensive subcutaneous emphysema at visualized lower neck (yellow arrow), extensive pneumomediastinum (blue arrow), bilateral pneumothorax with an extension of the air into the peritoneal cavity in keeping with massive pneumoperitoneum (red arrow) in the visualized upper abdomen. Diffuse ground-glass densities affecting both lungs with dense consolidative changes at the dependent area of lungs (purple arrow).

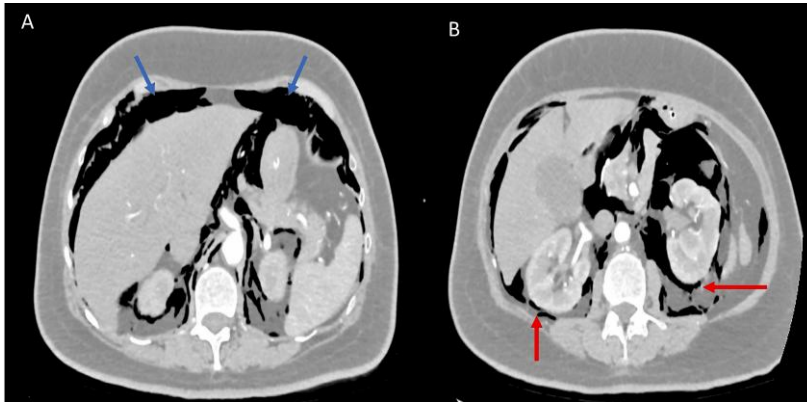


Figure 3: Axial images (A, B) at the upper abdomen level demonstrates extensive pneumomediastinum (blue arrows) involving visualized upper abdominal peritoneal cavity, also extending to involve retroperitoneal spaces (red arrows).

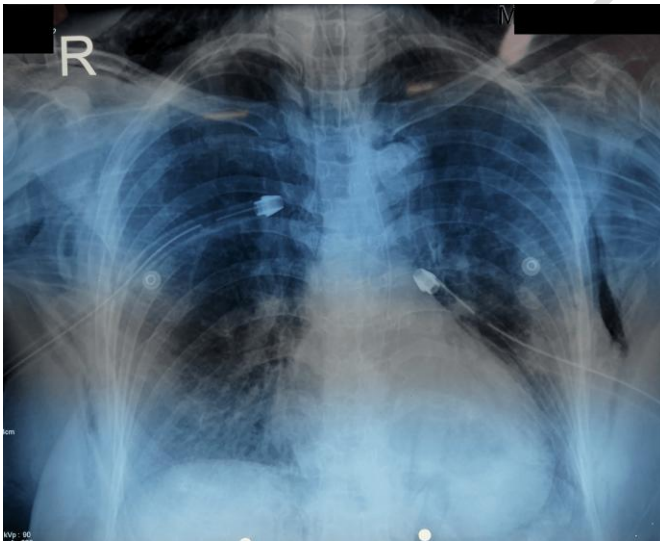


Figure 4: Bilateral chest tubes inserted with the resolution of pneumoperitoneum.

3. DISCUSSION

Nearly 90% of pneumoperitoneum cases are associated with visceral perforation that requires emergency surgical intervention [1]. The remainder of cases is attributed to non-surgical aetiology such as mechanical ventilation, pneumothorax, or cardiopulmonary resuscitation. The simultaneous presence of pneumomediastinum and pneumoperitoneum in a severe COVID-19 patient remained scarce in the literature.

COVID-19 potentially causes primary lung injury via diffuse alveolar damage, formation of intravascular microthrombi or acute fibrinous and organizing pneumonia [2]. A high risk of barotrauma was observed among COVID-19 patients on invasive mechanical ventilation,

with resultant pneumothorax or pneumomediastinum, as in the case presented [3]. Barotrauma leads to a rupture in the alveolar, which in turn causes an air leak in the pulmonary interstitium. The air leak will dissect along the bronchovascular sheaths, towards the pulmonary hilum and mediastinum, and cause pneumomediastinum, which is known as the Macklin Effect [4]. The free air is then leaked into the peritoneal cavity from the thoracic cavity.

Two mechanisms are used to explain how free air leaks into the peritoneal cavity. The first mechanism ~~are~~ thought due to communication between the thoracic and abdominal cavities by ~~an~~ undiagnosed diaphragmatic hernias such as posterolateral (Bochdalek) or parasternal (Morgagni) defects [5]. Another postulated mechanism is the passage of air from the mediastinum through the major diaphragmatic portals into the retroperitoneum, leaking into the peritoneal cavity [4]. The description latter is likely applied to our case, as evidenced by massive retroperitoneal free air (**Fig. 3**).

Accurate interpretation of such a condition is crucial and requires good correlation with radiological, clinical, and blood investigation, since non-therapeutic surgical intervention will incur higher morbidity and mortality on critically-ill severe COVID-19 patients. Our patient had radiographic evidence of the pneumoperitoneum, likely originating from the thorax, and there was no viscus perforation or intraabdominal collection. Clinically, the patient was hemodynamically stable, and could tolerate enteral feeding well, with no rise in septic parameters. Therefore, we can conclude that there was no viscus perforation. The patient was managed conservatively with close monitoring for intra-abdominal pressure or abdominal compartment syndrome if the pneumoperitoneum worsened. The pneumoperitoneum resolved a few days later.

4. CONCLUSION

Pneumomediastinum, pneumothorax, and subcutaneous emphysema coupled with pneumoperitoneum are rare complications of COVID-19 pneumonia. Non-surgical aetiology of pneumoperitoneum can be managed non-operatively, provided there is clear evidence of the absence of viscus perforation. A radiological examination, coupled with clinical findings and blood investigations, are crucial in establishing an accurate diagnosis. Unnecessary laparotomy will further compromise the outcome of critically-ill COVID-19 patients.

CONSENT

Written informed consent was obtained from the patient's family for publication of this case report and the accompanying images. A copy of the written consent is available for review by the Editor-in-Chief of this journal on request.

ETHICAL APPROVAL

The authors conformed to the provisions of the Declaration of Helsinki in 1995 (as revised in Brazil in 2013).

REFERENCES

1. Sharma M, Ojha P, Taweeseedt PT, Ratnani I, Surani S. An Intriguing Case of Pneumoperitoneum In a Patient With COVID-19: Do All Pneumoperitoneum Cases Need Surgery? *Cureus*. 2020 Dec 25;12(12):e12279.
2. Polak SB, Van Gool IC, Cohen D, von der Thüsen JH, van Paassen J. A systematic review of pathological findings in COVID-19: a pathophysiological timeline and possible mechanisms of disease progression. *Mod Pathol*. 2020;33(11):2128-2138.
3. McGuinness G, Zhan C, Rosenberg N, Azour L, Wickstrom M, Mason DM et al. Increased Incidence of Barotrauma in Patients with COVID-19 on Invasive Mechanical Ventilation. *Radiology*. 2020 Nov;297(2):E252-E262.
4. Vidrio Duarte R, Vidrio Duarte E, Gutierrez Ochoa J, GaviriaLeiva MC, Pimentel-Hayashi JA. Pneumoperitoneum in a COVID-19 Patient Due to the Macklin Effect. *Cureus*. 2021;13(2):e13200.
5. Lantsberg L, Rosenzweig V. Pneumomediastinum Causing Pneumoperitoneum. *Chest*. 1992;101(4):1176.

UNDR PEER REVIEW