

Case study

REVERSE STRAATSMA SYNDROME – A CASE REPORT

ABSTRACT-

Introduction- Straatsma Syndrome is a rare condition which presents as significant vision loss associated with triad of amblyopia, myopia and myelinated nerve fibres in retina, sometimes associated with strabismus. In this case report, we document a case of reverse Straatsma Syndrome exhibiting unilateral hypermetropia, amblyopia and myelinated nerve fibres in retina.

Objective- Ophthalmologic signs and symptoms were evaluated in a patient diagnosed with reverse Straatsma syndrome.

Materials and Methods- A 22 years old male from lower-middle class family, presented to Eye OPD with unilateral diminution of vision of left eye which was present since childhood but went unattended. Complete ophthalmologic examination showed anisometropic hypermetropic amblyopia of +8DS/ +3.5DC x 90° in LE, correctable to 6/60 and myelinated nerve fibres in LE retina superior to optic disc. The RE after refractive correction of +1.5 DS showed 6/6 vision.

Result- Patient was given full refractive correction of RE and counseled for the condition in LE.

INTRODUCTION-

Very often, myelinated nerve fibres are isolated findings which are incidentally detected on detailed examination of retina appearing as whitish- yellow network like thin membrane and obscuring the view of underlying retinal structures and they are very rarely associated with diminution or loss of vision. Sometimes, it is associated with refractive errors (myopia, hypermetropia), amblyopia or strabismus.

Straatsma Syndrome is one such rare condition which presents as significant diminution of vision associated with a triad of amblyopia, myopia and myelinated nerve fibres in retina^[1], sometimes associated with strabismus.^[2]

Reverse Straatsma Syndrome is even rarer and exhibits unilateral or bilaterally asymmetrical hypermetropia, amblyopia and myelinated nerve fibres in retina.^[1] Here, we document a rare case of a young patient of Reverse Straastma Syndrome.

AIMS AND OBJECTIVES-

To evaluate ophthalmologic signs and symptoms in a patient diagnosed with reverse Straatsma syndrome.

CASE PRESENTATION

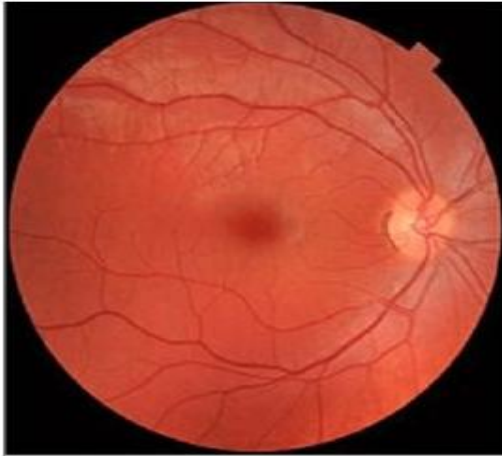MATERIALS AND METHODS-

A 22 years old male patient from lower-middle class, working as a shopkeeper, presented to eye OPD with unilateral diminution of vision of left eye (LE) which was present since childhood but he never paid due attention and ignored it. Complete and detailed ophthalmological examination was carried out in his both eyes. Preliminary examination showed –unaided visual acuity (VA) of counting fingers at 1m (CF@1m) in LE and 6/9(P) in RE. Refraction was done in both eyes to find out BCVA and amount and type of refractive error. Eyes were examined in primary position to check for strabismus and extra-ocular movements were checked in all gazes to note any restricted movement and conjugate/disconjugate movements. Complete anterior segment (AS) examination was done with torch light (pupillary reflexes) and Slit Lamp Biomicroscope. Intraocular pressure (IOP) was recorded in both eyes with Goldmann Applanation Tonometry. Dilated funduscopy of both eyes were done with indirect ophthalmoscopy and fundus pictures were taken with fundus camera. A-scan biometry was done in both eyes to record their axial length. Complete systemic examination was done to rule out tumors, inflammation etc.

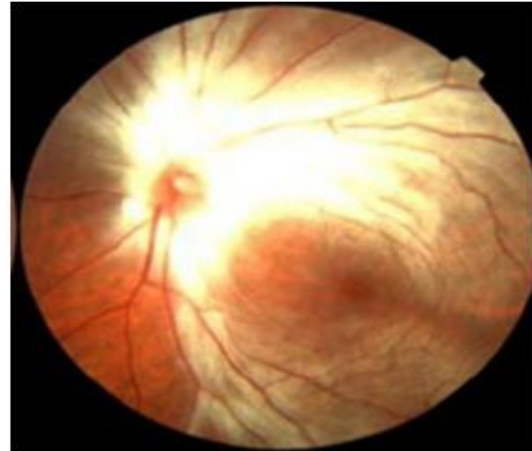
RESULTS-

Best Corrected Visual Acuity (BCVA) in right eye (RE) was 6/6 with refraction (+1.5DS) and left eye (LE) was 6/60 with refraction (+8DS/ +3.5DC x 90°). Both eyes were orthotropic (aligned straight) and there was complete range of movement and conjugate movement of both eyeballs in all gazes and positions. On torch light examination, pupils of both eyes (BE) were normal in size and normal light reflexes (direct and consensual) were present. Slit lamp biomicroscopy revealed normal structures in Anterior Segment of both eyes (BE). Intraocular Pressure (IOP) recorded by Goldmann Applanation Tonometer (GAT) measured 13mmHg in left eye (LE) and 12mmHg in right eye (RE). Indirect Ophthalmoscopy with a +20D lens showed

normal fundus in right eye (RE) but left eye (LE) fundus showed myelinated nerve fibres, emerging from optic disc and present superior, inferior and temporal to optic disc. Nasal retina and macula were free from myelination. Macula was normal (Foveal reflex seen). Optic disc showed a cup-disc ratio (C:D) of 0.4. A-Scan biometry done by immersion technique revealed axial length of : LE – 20mm and RE – 23mm.



Right eye – normal fundus



Left eye – myelinated nerve fibres
in superior, inferior and
temporal quadrant
Macula - normal

Figure 1 showing myelinated nerve fibres in superior, inferior and temporal quadrants of retina, emerging from optic nerve head in left eye

DISCUSSION-

Literatures quote that normally during embryonic development, nerve fibres entering the retina lose their myelin sheath at ora serrata, thus retinal nerve fibres are unmyelinated. The myelination process normally terminates at the level of lamina cribrosa at about 8th month of gestation till birth, but occasionally it continues into the retinal nerve fiber layer, giving it a whitish – yellow net-like appearance. Myelinated retinal nerve fibres result from the faulty location of oligodendrocyte-like cells in retina, prior to development or temporary loss or absence of the barrier function of the lamina cribrosa at optic nerve head ^[4].

Three different types of myelination are known^[5]-

- type 1 pattern along the superior temporal arcade
- type 2 pattern along both the arcades
- type 3 pattern with no contiguity with the ONH.

Our patient had type 2 myelination.

Myelinated retinal nerve fibres is a congenital and stationary condition which is more common in myopic than in hyperopic eyes, but there are some reports of myelinated fibers associated with hyperopia.^[3]

There are very few cases of Straatsma Syndrome and Reverse Straatsma Syndrome (<50) reported in literature making it rare and not much information is available on the pathophysiology of occurrence and it is unclear that whether diminution of vision is due to myelinated nerve fibres or a consequence of anisometropia.

In our case, anisometropia seems to have a stronger influence on the relative visual acuity of the patient's eyes than the presence of retinal nerve fiber myelination. With time, he developed anisometropic amblyopia and myelinated nerve fibres turned out to be an incidental finding.

Generally, such a large amount of anisometropia (more than +5D in our case) leads to development of squint in early age itself, but strangely our case had straight aligned eyes and no phorias were also noted. Some cases reported in literature have strabismus associated with them.

CONCLUSION-

Our patient was given full refractive correction of right eye (+1.50DS) and left eye was left unaided and he was counseled for the condition and visual prognosis in left eye.

Visual prognosis of amblyopia associated with myelination of retinal nerve fibers and anisometropia is poorer than anisometropic amblyopia without myelination. It is refractory to occlusive therapy. Despite having a poor prognosis, visual rehabilitation should be attempted.

REFERENCES-

1. Juhn, A. T., Houston, S. K., & Mehta, S. (2015). BILATERAL STRAATSMA SYNDROME WITH NYSTAGMUS. *Retinal Cases & Brief Reports*, 9(3), 198–200.
2. Straatsma BR, Heckenlively JR, Foos RY, Shahinian JK. Myelinated retinal nerve fibers associated with ipsilateral myopia, amblyopia, and strabismus. *Am J Ophthalmol*. 1979 Sep;88(3 Pt 1):506-10.

3. Lee JS, Daniel SJ. Myelinated retinal nerve fibers associated with hyperopia and amblyopia. JAAPOS, 2008; 12: 418-9
4. Tarabishy AB, Alexandrou TJ, Traboulsi EI. Syndrome of myelinated retinal nerve fibers, myopia and amblyopia: A review. Survey of Ophthalmol 2007; 52(6):588-96.
5. Ellis GS, Jr, Frey T, Gouterman RZ. Myelinated nerve fibers, axial myopia, and refractory amblyopia: An organic disease. J Pediatr Ophthalmol Strabismus. 1987;24:111-9.

UNDER PEER REVIEW