

Effects of opioid sparing analgesia for surgical procedure of laparoscopic pyloromyotomy in order to enhance recovery and better surgical outcomes

ABSTRACT

Aim: To determine the efficacy and outcomes of intraoperative and early post operative analgesia without respiratory depression for patients under laparoscopic pyloromyotomy. **Methodology:** This study was done at Pediatric surgery operating theatre and Post anesthesia care unit(PACU). Peoples University of Medical and Health Sciences for women (PUMHSW) Nawabshah during the period of 2010-2022. Total 103 cases were observed with n=68 male and n=35 females. Ethical approval was obtained from PUMHSW ethical review board and written informed consent was taken from subjects' parents or guardians. Infants of both sexes with 2-4.5 kg weight, age 3-8 weeks and diagnosed cases of infantile hypertrophic pyloric stenosis (IHPS) patients confirm by ultrasound were included in this study. Patients with the age of more than 2 months, with significant co morbid conditions, required an additional procedure during the operation, and those subjects possess a contraindication to the laparoscopic approach in the opinion of either the surgeon or the anesthesiologist were excluded from this study. Postoperative pain was measured by using the Neonatal Infant Pain Scale (NIPS) at 30,60,90,120 mins after completion of surgery. **Results:** In current study 103 patients were participated with male (n=68) to female (35) ratio 1.94:1 with mean age 34.94 ± 7.31 days. Mean weight of the patients were studied 3.08 ± 0.59 kg. Laparoscopic surgical procedure are less painful and patients can be managed by non opioid analgesic combination of intravenous acetaminophen with local anesthetic infiltration to achieved adequate pain relief and avoidance of delayed recovery, postoperative respiratory depression. **Conclusion:** Laparoscopic pyloromyotomy is safe and effective technique without postoperative respiratory depression and apneic episodes especially when opioid sparing multimodal analgesia is given.

Keywords: Acetaminophen, Laparoscopy, hypertrophic pyloric stenosis, non opioid analgesic

1. INTRODUCTION

Infantile hypertrophic pyloric stenosis is not uncommon surgical condition predominantly in male infants. The obstruction to gastric emptying leads to accumulation of gastric contents resulting persistent vomiting brings very detrimental electrolytes and biochemical changes along with dehydration. The predominant loses are in the form of severe depletion of potassium chloride, hydrogen and sodium. Alkalosis resulting from loses of these ions is preliminarily compensated by kidneys by excreting sodium Bicarbonates. The fluid of choice to

correct metabolic and electrolyte changes is done by sodium chloride solution supplemented with potassium. IHPS is never considered as surgical emergency, these patients are prone to postoperative respiratory depression and apneic spells. Despite of proper optimization of volume status, correction of electrolytes and acid base imbalance, meticulous attention during perioperative period such patients may end up in delayed recovery¹. Combination of local anesthetic and intravenous acetaminophen without use of opioids: a technique resulting better recovery profile and reduced immediate post operative analgesic requirement in patients undergoing Laparoscopic pyloromyotomy². Every patient received Inj: Acetaminophen 10mg/kg intravenously slowly, half hour before, Rapid sequence intubation (RSI) for general anesthesia^{3,4}. Prior to induction aspiration of nasogastric tube done in for positions of the patients by turning supine, right lateral, left lateral and prone. After strict aseptic measures 03 laparoscopy port sites marked by pediatric surgeon were in filtered at skin and deeper muscle plain by using ultrasound guided deposition of 0.5% xylocaine with adrenaline dose not exceeding 7mg/kg body weight. Anesthesia maintained with sevoflurane and cisatracurium with positive pressure ventilation (avoiding excessive hyperventilation)⁵.

The 1st explanation regarding pyloromyotomy through laparoscopic approach was showed in literature in 1991. The laparoscopic method having edge over open approach technique due to the reasons of reduces post-surgical pain and superior cosmesis although both have equal efficacy^{6,7}. One series has given the mixed results after the comparison of approaches, including the higher complications rate and extensive operating time in laparoscopic technique⁸. The other report claimed the operating time is equal but significantly decreases the recovery time and concluded laparoscopy was preferable⁹. Still other have claimed about both approaches have similar complications, equal operating and recovery time¹⁰. A recently published meta-analysis report observed less complication chances when used open approach, but recovery period was observed shorter in the favor of laparoscopy^{11,12}.

2. MATERIAL AND METHODS

This study was done at Pediatric surgical department operation theatre and PACU PUMHSW Nawabshah during the period of 2010-2022. Total 103 cases were observed with n=68 male and n=35 females. Ethical approval was obtained from PUMHSW ethical review board prior to select the patients in current study. Written informed consent was taken from subjects' parents or guardians. Infants of both sexes with 2-4.5 kg weight, age 3-8 weeks and diagnosed hypertrophic pyloric stenosis (HPS) patients by ultrasound were included in this study. Patients with the age of more than 2 months, with significant co morbid conditions, required an additional procedure during the operation, and those subjects possess a contraindication to the laparoscopic approach in the opinion of either the surgeon or the anesthesiologist were excluded from this study. The preoperative data included patient sex, age, weight, was collected at presentation. In this study laparoscopic technique was used for the treatment of HPS. For this purpose three port technique as one central 5-mm port through a periumbilical, incision was placed and two other small sized ports on either sides.

Non opioid analgesia by intravenous acetaminophen in combination with local anesthetic agents mixed with vasopressin(adrenaline) as the protocol by:1.Acetaminophen 15mg per kg half hour prior to commencing surgery to all

patients. 2. Ultrasound guided infiltration and deposition of xylocaine mixed with adrenaline dose not exceeding more than 7mg/kg block given immediately after Induction of general Anesthesia by using 0.5% lidocaine with adrenaline at the dose of 7mg per kg in every patient . OT temperature was maintained at 34°C. Neonatal Infant Pain Scale (NIPS) was used to measure the postoperative pain.

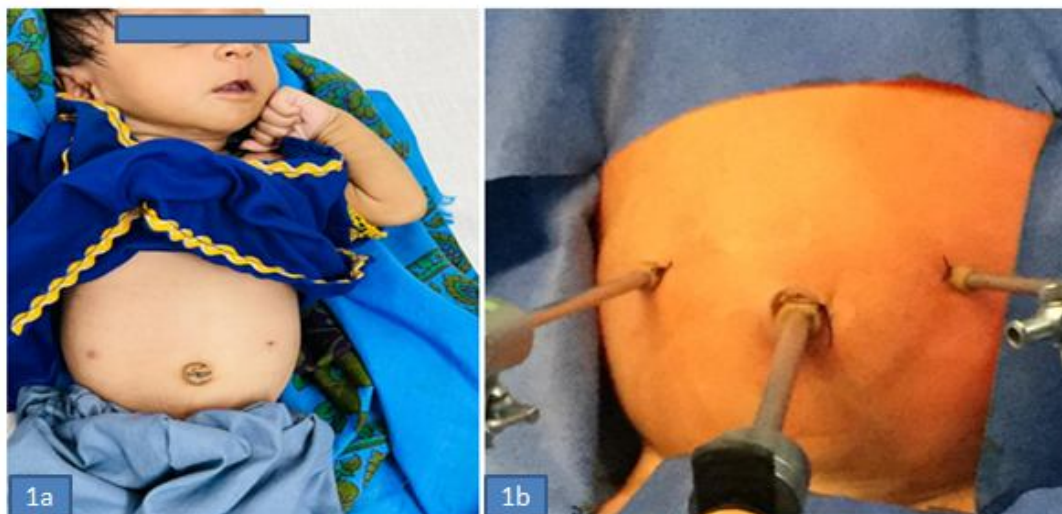

Figure 1a: 03 laparoscopic ports
1b: minimal post operative port marks

3. RESULTS

In this study 103 patients were enrolled with male (n=68) to female (35) ratio 1.94:1 with mean age 34.94 ± 7.31 days (fig 2). Mean age of male patients were observed 34.32 ± 7.5 days while female patients were 36.94 ± 6.75 days. Mean weight of the patients were studied 3.08 ± 0.59 kg. Mean weight male patients were observed 3.03 ± 0.59 kg while female patients were 3.16 ± 0.58 kg (table 1).

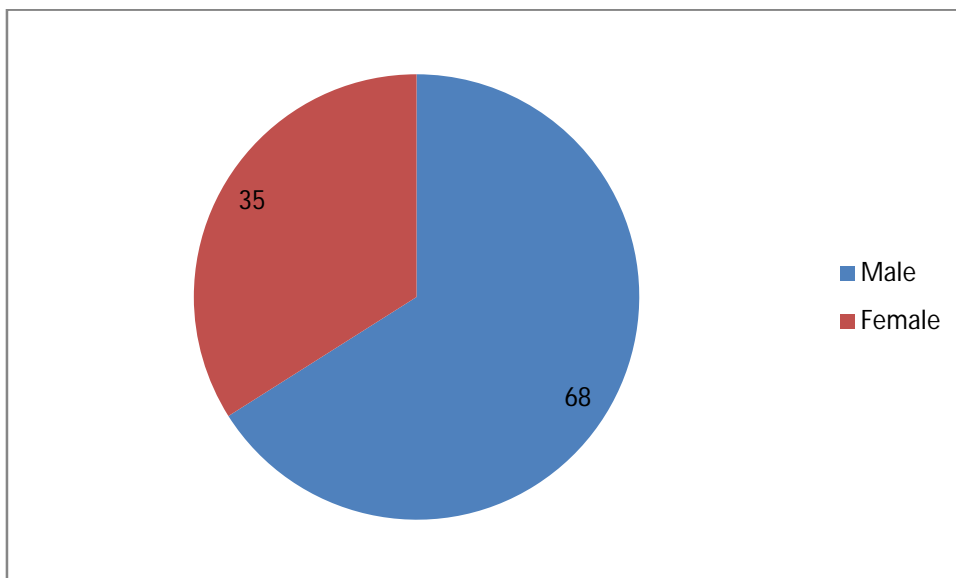


Figure 2 Distribution of patients by sex

Table 1: Preoperative data of HPS patients

Sr #	Variables	Total n=103(mean ± SE)	Male (n=68) (mean ± SE)	Female (n=35) (mean ± SE)
1	Age (days)	34.94±7.31	34.32±7.5	36.94±6.75
2	Weight (kg)	3.08±0.59	3.03±0.59	3.16±0.58

Postoperative complications, 3.88% bleeding (n=4), 3.85% persistent vomiting (n=5) and 1.94% portsite infection (n=2) were observed (fig 3).

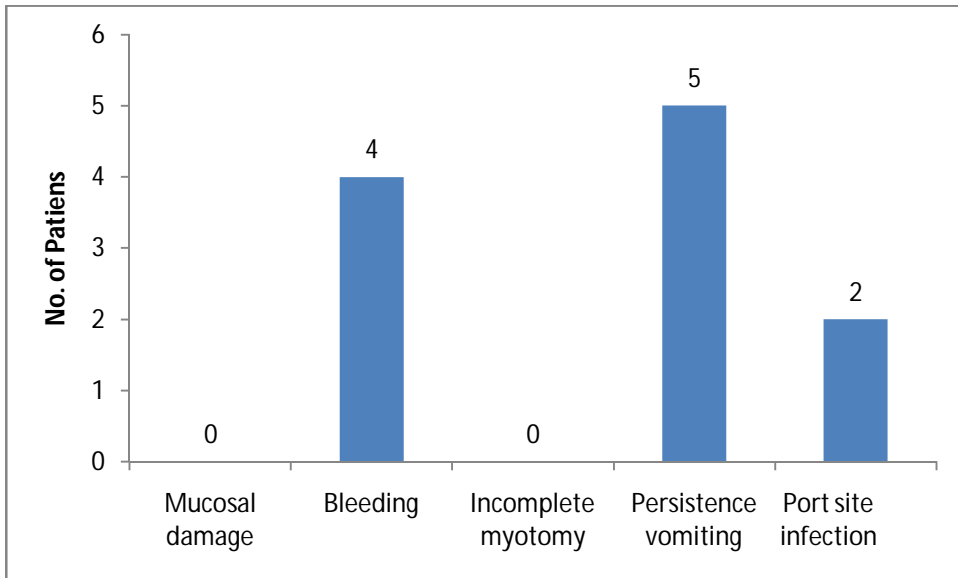


Figure 3: Postoperative complications (n=103)

Table 2: Postoperative pain assessment through neonatal infant pain scale (NIPS)

Postoperative time (min)	No. of Patients	NIPS
30	103	<03
60	103	<03
90	103	<03
120	88	<03
	15	>03

.All patients (n=103) were observed for NIPS at 30,60,90,120 mins post operatively. Two hours after surgery only 15 patients were observed NIPS more than 03, and were injected Inj: Acetaminophen 10mg/kg intravenously, bolus in 05 min, the NIPS score returned to less than 03 after 10 mins. After this injection none of patient (n=103) shown delay recovery and apnea spells. Laparoscopic surgical procedure is less painful and patients can be managed by non opioid analgesic combination of intravenous acetaminophen with local anesthetic infiltration to achieve adequate pain relief and avoidance of delayed recovery and postoperative respiratory depression.

4. DISCUSSION

Total 103 patients were included with mean age and weight 34.94 ± 7.31 days and kg respectively. Yung et al also observed the mean age of patients 34.2 ± 14.5 days and mean weight 4.01 ± 0.80 kg, all the patients had a laparoscopic approach for pyloromyotomy¹³. Peter et al also work on patients had a laparoscopic

approach for pyloromyotomy with mean age 5.33 ± 0.21 weeks¹⁴. These results are supporting our research findings. In current study postoperative complications, 3.88% bleeding, 3.85% persistent vomiting and 1.94% portsite infection were observed. Other researchers also experienced postoperative complications by 31.5% of the first 35 LP patients¹². The practice of anesthesiology involves choosing appropriate analgesic medications for a specific surgical patient population. Therefore, analgesic agents must be chosen judiciously, taking into account the patient's unique physiology⁸. In this study we use the combination of local anesthetic and I/V acetaminophen postoperatively in Laparoscopic pyloromyotomy. Opioids remain the primary analgesic regimen for perioperative pain. However, this class of analgesics is related with dose-dependent unfavorable effects which may impact postoperative outcomes especially in infants and neonates^{7,9}. Alternative non-opioid analgesic agents exist, which may offer advantages to opioid monotherapy.^{5,11} The basic advantage is the obstacle of opioid side effects including pruritus, nausea, constipation, vomiting and opioid-induced hyperalgesia. An opioid-sparing technique is often advocated for these patients during pyloromyotomy.⁴ Acetaminophen is a commonly used non-opioid analgesic with a well-established tolerability and safety profile. Acetaminophen is commercially accessible in numerous formulations.⁸ IV acetaminophen was approved by the US FDA in November 2010 for the management of mild-to-moderate pain, as an accessory to opioids for the management of moderate-to-severe pain, and the decrease in fever. As compared with peak acetaminophen plasma level following oral (45–60 minutes), IV acetaminophen results speedy peak plasma level at 15 minutes following infusion and an analgesic effect as quickly as 5 minutes with a duration of action up to 4 hours. Costanzo et al reported opioid-sparing effects with either rectal or IV administration.⁷ However, Staerkle et al noted no effect on total opioid needs with IV acetaminophen after major spine surgery in children and adolescents.⁹ The average IV acetaminophen dose was 8.6 mg/kg in the patients. Maintenance dosing ranging from 7.5 mg/kg to 10 mg/kg has been suggested, with some sources suggesting a loading dose of up to 20 mg/kg irrespective of age. IV acetaminophen has a clear benefit in patients who cannot tolerate acetaminophen via oral or rectal routes⁸. To adopt the non opioid based technique of perioperative pain management to prevent early post operative respiratory depression in patients of IHPS undergoing three port approach for laparoscopic pyloromyotomy at our teaching hospital with a very competent and skilled Pediatric surgical and experienced anesthesia surgical ICU and pain management team.

4. CONCLUSION

Laparoscopic pyloromyotomy is safe and effective technique without postoperative respiratory depression and apneic episodes especially when opioid sparing multimodal analgesia is given.

CONSENT

All authors declare that 'written informed consent was obtained from the patient.

REFERENCES

1. Butterworth JF, Mackey DC, Wasnick JD. Morgan & Mikhail's clinical anesthesiology. New York: McGraw-Hill; 2013 Apr 1.
2. Rebmann C. Anesthesia for Pediatric General Surgery. In: A Guide to Pediatric Anesthesia 2020 (pp. 315-333).
3. Sbaraglia F, Familiari P, Maiellare F, Mecarello M, Scarano A, Del Prete D, Lamacchia R, Antonicelli F, Rossi M. Pediatric anesthesia and achalasia: 10 years' experience in peroral endoscopy myotomy management. *Journal of Anesthesia, Analgesia and Critical Care*. 2022 Dec;2(1):1-7.
4. Du T. Anesthesia for Hypertrophic Pyloric Stenosis. In *Anesthesiology* 2018 (pp. 403-411).
5. Schwartz MR, Li YM. Pediatric Emergency Surgeries. *Pediatric Anesthesia: A Guide for the Non-Pediatric Anesthesia Provider Part I*. 2022 Apr 11:256.
6. Pogorelić Z, Zelić A, Jukić M, Llorente Muñoz CM. The safety and effectiveness of laparoscopic pyloromyotomy using 3-mm electrocautery hook versus open surgery for treatment of hypertrophic pyloric stenosis in infants. *Children*. 2021 Aug 13;8(8):701.
7. Costanzo CM, Vinocur C, Berman L. Postoperative outcomes of open versus laparoscopic pyloromyotomy for hypertrophic pyloric stenosis. *Journal of Surgical Research*. 2018 Apr 1;224:240-4.
8. Sharabiani BA, Sheikhzadeh D, Akbari S, Arjmand N, Parsay S. Intravenous Bolus Fentanyl vs. Rectal Acetaminophen in Outcome and Quality of Anesthesia in Infants Undergoing Pyloromyotomy: A Randomized Clinical Trial.
9. Staerke RF, Lunger F, Fink L, Sasse T, Lacher M, von Elm E, Marwan AI, Holland-Cunz S, Vuille-dit-Bille RN. Open versus laparoscopic pyloromyotomy for pyloric stenosis. *Cochrane database of systematic reviews*. 2021(3).
10. Ismail I, Elsherbini R, Elsaied A, Aly K, Sheir H. Laparoscopic vs. open pyloromyotomy in treatment of infantile hypertrophic pyloric stenosis. *Frontiers in Pediatrics*. 2020 Aug 21;8:426.
11. Toomey V, Randolph A, Bourgeois F, Graham D. Variation in intravenous acetaminophen use in pediatric hospitals: priorities for standardization. *Hospital Pediatrics*. 2021 Jul;11(7):734-42.
12. van den Bunder FA, van Heurn E, Derikx JP. Comparison of laparoscopic and open pyloromyotomy: Concerns for omental herniation at port sites after the laparoscopic approach. *Scientific reports*. 2020 Jan 15;10(1):1-6.
13. Yung A, Thung A, Tobias JD. Acetaminophen for analgesia following pyloromyotomy: does the route of administration make a difference?. *Journal of pain research*. 2016;9:123.
14. Peter SD, Holcomb III GW, Calkins CM, Murphy JP, Andrews WS, Sharp RJ, Snyder CL, Ostlie DJ. Open versus laparoscopic pyloromyotomy for pyloric stenosis: a prospective, randomized trial. *Annals of surgery*. 2006 Sep;244(3):363.

1.