

Original Research Article

Qualitative expression of Sox2 and Oct4 in Oral submucous fibrosis: An Immunohistochemical study

Abstract:

Background: This stemness markers has proved its ability in tumorigenicity, tumor metastasis and even distant recurrence after chemotherapy in different types of cancer. Also, it has shown its evidence in pre-malignant conditions such as OSMF (Oral Submucous Fibrosis) where according to Lazarevic et al. even the surgical margins of oral cancer did show the presence of stem cell markers such as Sox2 and Oct4.

Aim:

Establishing the relationship of Sox2 and Oct4 markers with potentially malignant disorder, OSMF. Correlation between the said markers and the clinical and histopathological classification.

Material and Methods:

40 archival tissue samples of OSMF were clinically and histopathologically classified using Khanna and Andrade classification. Immunohistochemical analysis for Sox2 and Oct4 was performed on paraffin-embedded tissue sections on 20 histopathologically confirmed cases of oral submucous fibrosis each.

Results:

The resulting data were analyzed using the SPSS software version 20.0. The significance of the parameters was tested by the Pearson's Chi-square test ($P \leq 0.05$ as statistically significant). The immunohistochemical results showed that Sox2 and Oct4 could be detected in the basal and supra basal layers in OSMF. Although no significant difference was noted in the expression of Sox2 and Oct4 with increasing grades of oral submucous fibrosis

Conclusion:

The results obtained from this study shows a contingency between the Sox2 and Oct4 marker with OSMF. These results need to be further investigated and further verified with inclusion of a greater number of cases.

Introduction:

OSMF is categorized as a potentially malignant disorder and is an eviscerating disease commonly subjected to the Indian subcontinent and Southeast Asia. The contributing factors are chewing of areca nut, pan masala, betel quid, gutkha etc.^{1,2} OSMF is occasionally

preceded by, or associated with, the formation of vesicles, it is always associated with a juxtaepithelial inflammatory reaction followed by fibroelastic change of the lamina propria and epithelial atrophy that leads to stiffness of the oral mucosa and causes trismus and an inability to eat.³ Although it is not known how many oral squamous cell carcinomas arise from precursor lesions and how many develop from apparently normal oral mucosa. It is widely accepted that a dysplastic lesion carries a decisively greater risk of malignant transformation than a non-dysplastic one and various reports have been published regarding malignant transformation of oral potentially malignant disorders. The malignant potential of OSF was first described by Paymaster in 1956, and the rate has been estimated to be 7- 13%. Even though the mechanisms of malignant transformation have not been clear up to date⁴

With profound significance to alleviate many diseases for which there is no effective treatment, stem cells have seen a dramatic rise in literature in the medical field in recent years. Stem cells are special human cells which have the ability to develop into different ranges of cell types. There is increasing evidence that the growth and spread of cancer is driven by a small subpopulation of cancer cells, defined as cancer stem cells (CSCs). They possess the ability to initiate neoplasms and sustain tumor self-renewal; identification and isolation of CSCs constitute a major experimental challenge.⁵

The transcription factors like Oct4 (Octamer-binding transcription factor 4), Sox2 (Sex determining region SRY homolog box 2) and Nanog play essential roles in maintaining pluripotency and self-renewal of embryonic stem cells. Its role in reprogramming, is used to create induced pluripotent stem cells (iPSCs) along with , Klf4 and c-MYC has also been studied by various researchers.⁶ This stemness marker has proved its ability in tumorigenicity, tumor metastasis and even distant recurrence after chemotherapy in different types of cancer. Also, it has shown its evidence in pre-malignant conditions such as OSMF

(Oral Submucous Fibrosis) where according to Lazarevic et al. even the surgical margins of oral cancer did show the presence of stem cell markers such as Sox2 and Oct4.^{6,7}

With this background, the study focuses on the relationship of Sox2 and Oct4 markers with potentially malignant disorder, OSMF.

Material and methods:

Patients and tissue samples: The study was conducted in the Department Of Oral and Maxillofacial Pathology and Microbiology, D.Y Patil Dental College, Navi Mumbai, on archival tissue samples which were submitted for the histopathological evaluation. Study samples consisted of 30 histopathologically confirmed cases of Oral submucous fibrosis. The samples were fixed in 10% neutral-buffered formalin and embedded in paraffin wax to obtain 3 μ sections for immunohistochemistry procedure. Ethical approval from the institutional review board was obtained for this study.

Immunohistochemistry with Sox2 and Oct4: Three-micrometer-thick sections from archival formalin-fixed paraffin-embedded tissues were placed on poly-L-lysine-coated slides for immunohistochemistry. Sox2 and Oct4 immunoexpression was analysed by the immunohistochemical examination with the antibody 15 and 10 slides each. Lung squamous cell carcinoma and normal oral mucosa served as the positive control. Positive staining for both Sox2 and Oct4 was seen as localization in both membrane and cytoplasm within the cell in the form of crisp brown color.

Assessment of immune scoring: The IHC results were independently evaluated by two observers, blinded to clinical data. Sox2 and Oct4 staining was evaluated as the percentage of cells with nuclear staining in the samples and graded accordingly. The number of positively stained cells were expressed as a percentage of the total number of cells: grade 1: less than

5% positive cells, grade 2: 6-25% positive cells, grade 3: 26-50% positive cells and grade 4 more than 50% positive cells.

Statistical analysis: Statistical analysis was performed using the Statistical Package for the Social Sciences (SPSS) software by descriptive and inferential statistics. Descriptive statistics were used for demographic data and summarized as mean with standard deviation of the markers used. The data collected were first visualized to confirm their normal distribution. The descriptive statistics like frequency distribution of data was calculated. The significance of the parameters was tested by Pearson's Chi square test. The 95% confidence interval and 5% level of significance was used for analysis of data. A $P \leq 0.05$ was considered statistically significant.

Results:

Oral submucous fibrosis cases selected for Sox2 and Oct4 immunohistochemical expression were between the age range of 25 years to 40 years with 66.7% and 100% male preponderance for Sox2 and Oct4 respectively. The immunohistochemical results showed that Sox2 and Oct4 could be detected in the basal layer of normal oral mucosa and basal and supra basal layers in OSMF. Sox2 (Figure 1) and Oct4 (Figure 2) exhibited nuclear staining, respectively. The immunohistochemical expression of both Sox2 and Oct4 was found to increase from normal oral mucosa to oral submucous fibrosis.

OSMF was classified according to Khanna and Andrade classification into 4 different grades namely, very early, early, moderately advanced and advanced. Comparison between the histological grading given by the observers and this classification was done.⁸

Assessment of Sox2 immunohistochemical expression in 15 OSMF study cases

Based on the classification, the cases selected for Sox2 were graded as follows, 6.70% very early, 40% early, 40% moderately advanced and 13.3% advanced. Combining the histological staging by 2 observers and grading discussed earlier, 6.7% showed grade 1, 40% grade 2, 33.3% grade 3 and 20% grade 4. Chi square value was observed as 0.291 and p value of 0.962. (Table 1)

			<i>Grade 1</i>	<i>Grade 2</i>	<i>Grade 3</i>	<i>Grade 4</i>	<i>Total</i>
Group	Observers	Count	1	6	5	3	15
		% within Group	6.7%	40.0%	33.3%	20.0%	100.0%
			Very early	Early	Moderately advanced	Advanced	
	Clinical H/P	Count	1	6	6	2	15
		% within Group	6.7%	40.0%	40.0%	13.3%	100.0%
			Count	2	12	11	5
		% within Group	6.7%	40.0%	36.7%	16.7%	100.0%
Total							
Chi square value: 0.291 p value: 0.962							

Table 1: Comparison of histological grading by observers and clinical and histological classification of OSMF in Sox2 expression

Assessment of Oct4 immunohistochemical expression in 10 OSMF study cases

Similarly, for Oct4 based on Khanna and Andrade classification cases were graded as follows, 0% very early, 30% early, 20% moderately advanced and 50% advanced. Combining the histological staging by 2 observers and grading discussed earlier Oct4 cases were graded as; 0% grade 1, 20% grade 2, 10% grade 3 and 70% grade 4. Chi square value was observed as 0.867 and p value as 0.648 (Table 2)

			<i>Grade 1</i>	<i>Grade 2</i>	<i>Grade 3</i>	<i>Grade 4</i>	<i>Total</i>
Group	Observers	Count	2	3	2	8	15
		% within Group	13.3%	20.0%	13.3%	53.3%	100.0%
			Very early	Early	Moderately advanced	Advanced	
	Clinical H/P	Count	2	4	3	6	15
		% within Group	13.3%	26.6%	20.0%	40%	100.0%
Total		Count	4	7	5	14	30
		% within Group	13.3%	23.3%	16.6%	46.6%	100.0%
Chi square value: 0.6286 p value: 0.8898							

Table 2: Comparison of histological grading by observers and clinical and histological classification of OSMF in Oct4 expression

Although no significant difference was noted in the expression of Sox2 and Oct4 with increasing grades of oral submucous fibrosis.

Discussion:

The pathogenesis of OSMF has been a debatorial problem^{9,10}. Since the normal oral mucosa has a layer of basal stem cells which shows an expansive range of mechanisms such as stemness/clonogenicity, it thereby maintains the epithelial homeostasis, stimulating in differentiation^{11,12}. Though there is not much clear evidence on the pathogenesis of OSMF, EMT (Epithelial- Mesenchymal Transition) has shown to be substantially correct. In this process, there is a biological transition of a polarized epithelial cell to mesenchymal configuration¹³. Considering the fact that EMT has gained immense contribution towards tumorigenesis, it has been classified into 3 types. Amidst all 3 types, Type III metamorphosed into tumor evince tumor formation, progression and metastasis of cancer cells¹⁴. The other 2 types namely type I and type II mainly target on organ development, formation of embryo and inflammation and wound healing respectively¹⁵.

As already reasoned out, the epithelial cell expression is analogously lesser than the mesenchymal cell expression and also an augmented rise in transcription factors are also noted. Among the various transcription factors, homeobox families belonging to the homeodomain transcription factor are the significant ones principally subsidising EMT pathways¹⁶.

Apart from the aforementioned results, a comprehensive study conducted by a group of researchers shows the expression of vacillating patterns of oral mucosal stem cell markers such as that of Sox2, Oct4, E-cadherin, c-MYC^{17,18}.

OSMF, a mucosal condition seen in those having the habit of areca nut chewing do not have any gender specificity. However, this decades old disease shows marked collagen destruction in conjunction with those having the habit of areca nut chewing. Arecoline, an alkaloid constituent of areca nut triggers the collagen production thus resulting in a juxta epithelial

inflammatory reaction followed by the fibro-elastic changes in the lamina propria layer leading to epithelial atrophy. Areca nuts consist of other alkaloids other than arecoline, such as arecaidine, arecolidine, guayacoline, and guacine.^{19,20,21,22} Apart from the alkaloid components, they also contain flavonoid components like tannins and catechins.²³ Development of such pre-cancerous conditions which then transforms into a malignancy have widely been investigated. Although there are different theories and concepts relating to the same, the recent and most advanced one encompass epigenetics. Epigenetics have its role in gene transcription where the regulatory proteins play a major role.²⁴ One such epigenetic control pathway which involves the miR-145 (microRNA-145) molecules was found to be of great significance. These miR-145 are non-coding protein RNA molecules which act as a tumor suppressor gene thereby inhibiting tumor metastasis, proliferation and invasion.²⁵ The self-renewing transcription factor Oct4 has shown its effect in upregulation due to the downregulation of miR-145 (microRNA-145) by arecoline along with SOX-2 marker^{26,27}. In recent years, an increasing number of studies have shown that the plasticity of epithelial stemness cells is key to maintaining epithelial regeneration, structural integrity, and homeostasis. Various studies have been conducted using Sox2 and Oct4 markers, the inference of which has been formulated in Table 3.

Author	IHC marker	Sample	Observation and Inference
Bin Qiao <i>et al</i>⁶	Sox2 and Oct4	Precancerous lesions n=20 OSCCs in primary site n=116 Corresponding	Immunohistochemical expression of Oct4 and Sox2 may contribute to the malignant transformation of oral mucosa

		epithelial non-cancer tissues adjacent to the OSCC n=20	
Changqing Xie et al ²⁸	Sox2, Bmi1 and Ki67	Normal oral mucosa n=10 OSMF n=81	The expression levels of SOX2 and Bmi1 showed an increasing trend in the progression of OSMF. Ki67, SOX2, and Bmi1 were highly expressed in OSMF tissues with dysplasia. Moreover, the three proteins were located at the epithelial and mesenchymal junctions, and their expression showed a positive correlation with each other
de Vicente et al., 2019 ²⁹	Sox2	Oral epithelial dysplasia n=55	SOX2 protein expression was found to significantly increase with the grade of dysplasia
Chiou S et al., 2008 ^{29,30}	Oct4 and NANOG	OSCC n=52	Elevated expression of OCT-4 and NANOG was observed to be positively associated with tumor progression and worse prognosis of oral cancer. On comparison of expression of OCT4 and NANOG with prognosis of OSCC patients,

			NANOG was found to be a better predictor for worse prognosis as compared to OCT4
Du L <i>et al.</i>, 2011²⁹⁻³¹	Sox2	Tongue squamous cell carcinoma n=82	SOX2 expression was significantly associated with large tumor size. Multivariate analysis of this study demonstrated that SOX2-positive expression was an independent prognostic indicator of unfavorable survival outcome
de Vicente <i>et al.</i>, 2019²⁹	Sox2	OSCC n=125	No correlation of expression of SOX2 with clinicopathologic prognostic factor was found. SOX2 was thought to be associated with early oral tumorigenesis rather than in tumor progression
Narges Ghazi <i>et al.</i> 32	Sox2 and Oct4	OSCC n=45 OED n=15	The role of SOX2 or OCT4 in oral mucosal carcinogenesis can be explained by increased expression of SOX2 and OCT4 in higher grades and the significant correlation of these genes with each other among OSCC specimens.

Present study	Sox2 and Oct4	OSMF n=30	The results obtained from this study shows a positive correlation between Sox2 and Oct4 markers with OSMF. Although no significant difference was noted in the expression of Sox2 and Oct4 with increasing grades of oral submucous fibrosis.
----------------------	---------------	-----------	-----------------------------------------------------------------------------------------------------------------------------------------------------------------------------------------------------------------------------------------------

Table 3: Details of observational studies on Sox2, Oct4 and other transcriptional factors in oral potentially malignant disorders and Oral Squamous cell carcinoma

Present study focuses on qualitative immunohistochemical expression of Sox2 and Oct4 in potentially malignant disorders, oral submucous fibrosis. Correlation between the said markers and the clinical and histopathological classification derived by Khanna and Andrade is also studied. However, no significant difference was noted in the expression of Sox2 and Oct4 with increasing grades of oral submucous fibrosis.

Conclusion:

Recent advances in tumor molecular biology have found a variety of useful biomarkers in cancer detection, monitoring of progression, prognosis estimation and inspection of therapeutic responses. Previous studies dealing with molecular carcinogenesis have identified cancer stem cell marker Sox2 and Oct4 involved in carcinogenesis. However, the role of these markers in oral submucous fibrosis is poorly understood. Therefore the aim of the present study was to evaluate immunohistochemical expression of Sox2 and Oct4 in OSMF.

To summate, the results obtained from this study shows a contingency between the Sox2 and Oct4 marker with OSMF. These results need to be further investigated and further verified with inclusion of a greater number of cases.

Figure legends:

Fig 1: Immunohistochemical expression Sox2 in OSMF cases

Fig 2: Immunohistochemical expression Oct4 in OSMF cases

Table legends:

Table 1: Comparison of histological grading by observers and clinical and histological classification of OSMF in Sox2 expression

Table 2: Comparison of histological grading by observers and clinical and histological classification of OSMF in Oct4 expression

Table 3: Details of observational studies on Sox2, Oct4 and other transcriptional factors in oral potentially malignant disorders and Oral Squamous cell carcinoma

COMPETING INTERESTS DISCLAIMER:

Authors have declared that no competing interests exist. The products used for this research are commonly and predominantly use products in our area of research and country. There is absolutely no conflict of interest between the authors and producers of the products because we do not intend to use these products as an avenue for any litigation but for the advancement of knowledge. Also, the research was not funded by the producing company rather it was funded by personal efforts of the authors.

References:

1. Sharma M, Fonseca FP, Hunter KD, Radhakrishnan R. Loss of oral mucosal stem cell markers in oral submucous fibrosis and their reactivation in malignant transformation. *Int J Oral Sci*. 2020 Aug 21;12(1):23.
2. Ray JG, Chatterjee R, Chaudhuri K. Oral submucous fibrosis: A global challenge. Rising incidence, risk factors, management, and research priorities. *Periodontol 2000*. 2019 Jun;80(1):200–12.
3. Passi D, Bhanot P, Kacker D, Chahal D, Atri M, Panwar Y. Oral submucous fibrosis: Newer proposed classification with critical updates in pathogenesis and management strategies. *Natl J Maxillofac Surg*. 2017 Jul;8(2):89–94.
4. Ekanayaka RP, Tilakaratne WM. Oral submucous fibrosis: review on mechanisms of malignant transformation. *Oral Surg Oral Med Oral Pathol Oral Radiol*. 2016 Aug;122(2):192–9.
5. de Vicente JC, Donate-Pérez Del Molino P, Rodrigo JP, Allonca E, Hermida-Prado F, Granda-Díaz R, et al. SOX2 Expression Is an Independent Predictor of Oral Cancer Progression. *J Clin Med Res [Internet]*. 2019 Oct 21;8(10). Available from: <http://dx.doi.org/10.3390/jcm8101744>
6. Qiao B, He B, Cai J, Yang W. The expression profile of Oct4 and Sox2 in the carcinogenesis of oral mucosa. *Int J Clin Exp Pathol*. 2014;7(1):28–37.
7. Milosevic M, Lazarevic M, Toljic B, Simonovic J, Trisic D, Nikolic N, et al. Characterization of stem-like cancer cells in basal cell carcinoma and its surgical margins. *Exp Dermatol*. 2018 Oct;27(10):1160–5.
8. Reshma V, Varsha BK, Rakesh P, Radhika MB, Soumya M, D’Mello S. Aggrandizing oral submucous fibrosis grading using an adjunct special stain: A pilot study. *J Oral Maxillofac Pathol*. 2016 Jan 1;20(1):36.
9. Ray JG, Chatterjee R, Chaudhuri K. Oral submucous fibrosis: A global challenge. Rising incidence, risk factors, management, and research priorities [Internet]. Vol. 80, *Periodontology 2000*. 2019. p. 200–12. Available from: <http://dx.doi.org/10.1111/prd.12277>
10. Sharma M, Shetty SS, Radhakrishnan R. Oral Submucous Fibrosis as an Overhealing Wound: Implications in Malignant Transformation [Internet]. Vol. 13, *Recent Patents on Anti-Cancer Drug Discovery*. 2018. p. 272–91. Available from: <http://dx.doi.org/10.2174/1574892813666180227103147>
11. Rodini CO, Lopes NM, Lara VS, Mackenzie IC. Oral cancer stem cells - properties and consequences [Internet]. Vol. 25, *Journal of Applied Oral Science*. 2017. p. 708–15. Available from: <http://dx.doi.org/10.1590/1678-7757-2016-0665>
12. Jones KB, Klein OD. Oral epithelial stem cells in tissue maintenance and disease: the first steps in a long journey [Internet]. Vol. 5, *International Journal of Oral Science*. 2013. p. 121–9. Available from: <http://dx.doi.org/10.1038/ijos.2013.46>
13. Kalluri R, Weinberg RA. The basics of epithelial-mesenchymal transition [Internet]. Vol. 119, *Journal of Clinical Investigation*. 2009. p. 1420–8. Available from: <http://dx.doi.org/10.1172/jci39104>

14. Zeisberg M, Neilson EG. Biomarkers for epithelial-mesenchymal transitions [Internet]. Vol. 119, *Journal of Clinical Investigation*. 2009. p. 1429–37. Available from: <http://dx.doi.org/10.1172/jci36183>
15. Sharma M, Shetty SS, Radhakrishnan R. Oral Submucous Fibrosis as an Overhealing Wound: Implications in Malignant Transformation [Internet]. Vol. 13, *Recent Patents on Anti-Cancer Drug Discovery*. 2018. p. 272–91. Available from: <http://dx.doi.org/10.2174/1574892813666180227103147>
16. Wang Y, Liu J, Ying X, Lin PC, Zhou BP. Twist-mediated Epithelial-mesenchymal Transition Promotes Breast Tumor Cell Invasion via Inhibition of Hippo Pathway [Internet]. Vol. 6, *Scientific Reports*. 2016. Available from: <http://dx.doi.org/10.1038/srep24606>
17. Wang Y, Liu J, Ying X, Lin PC, Zhou BP. Twist-mediated Epithelial-mesenchymal Transition Promotes Breast Tumor Cell Invasion via Inhibition of Hippo Pathway [Internet]. Vol. 6, *Scientific Reports*. 2016. Available from: <http://dx.doi.org/10.1038/srep24606>
18. Sharma M, Fonseca FP, Hunter KD, Radhakrishnan R. Loss of oral mucosal stem cell markers in oral submucous fibrosis and their reactivation in malignant transformation [Internet]. Vol. 12, *International Journal of Oral Science*. 2020. Available from: <http://dx.doi.org/10.1038/s41368-020-00090-5>
19. Website [Internet]. Available from: <http://dx.doi.org/10.1038/ijos.2013.46>
20. Chen P-H, Mahmood Q, Mariottini GL, Chiang T-A, Lee K-W. Adverse Health Effects of Betel Quid and the Risk of Oral and Pharyngeal Cancers. *Biomed Res Int*. 2017 Dec 11;2017:3904098.
21. Sharan RN, Mehrotra R, Choudhury Y, Asotra K. Association of betel nut with carcinogenesis: revisit with a clinical perspective. *PLoS One*. 2012 Aug 13;7(8):e42759.
22. Gupta B, Johnson NW. Systematic review and meta-analysis of association of smokeless tobacco and of betel quid without tobacco with incidence of oral cancer in South Asia and the Pacific. *PLoS One*. 2014 Nov 20;9(11):e113385.
23. Chang Y-C, Yang S-F, Tai K-W, Chou M-Y, Hsieh Y-S. Increased tissue inhibitor of metalloproteinase-1 expression and inhibition of gelatinase A activity in buccal mucosal fibroblasts by arecoline as possible mechanisms for oral submucous fibrosis. *Oral Oncol*. 2002 Feb;38(2):195–200.
24. Babashah S, Soleimani M. The oncogenic and tumour suppressive roles of microRNAs in cancer and apoptosis [Internet]. Vol. 47, *European Journal of Cancer*. 2011. p. 1127–37. Available from: <http://dx.doi.org/10.1016/j.ejca.2011.02.008>
25. Small EM, Frost RJA, Olson EN. MicroRNAs add a new dimension to cardiovascular disease. *Circulation*. 2010 Mar 2;121(8):1022–32.
26. Lu Y, Chopp M, Zheng X, Katakowski M, Buller B, Jiang F. MiR-145 reduces ADAM17 expression and inhibits in vitro migration and invasion of glioma cells [Internet]. Vol. 29, *Oncology Reports*. 2013. p. 67–72. Available from: <http://dx.doi.org/10.3892/or.2012.2084>

27. Sachdeva M, Mo YY. Abstract 2350: MicroRNA-145 suppresses cell invasion and metastasis by directly targeting mucin 1 [Internet]. *Tumor Biology*. 2010. Available from: <http://dx.doi.org/10.1158/1538-7445.am10-2350>
28. Xie C, Feng H, Zhong L, Shi Y, Wei Z, Hua Y, et al. Proliferative ability and accumulation of cancer stem cells in oral submucous fibrosis epithelium. *Oral Dis* [Internet]. 2020 Apr 8; Available from: <http://dx.doi.org/10.1111/odi.13347>
29. de Vicente JC, Rodríguez-Santamarta T, Rodrigo JP, Allonca E, Vallina A, Singhania A, et al. The Emerging Role of NANOG as an Early Cancer Risk Biomarker in Patients with Oral Potentially Malignant Disorders. *J Clin Med Res* [Internet]. 2019 Sep 3;8(9). Available from: <http://dx.doi.org/10.3390/jcm8091376>
30. Chiou S-H, Yu C-C, Huang C-Y, Lin S-C, Liu C-J, Tsai T-H, et al. Positive correlations of Oct-4 and Nanog in oral cancer stem-like cells and high-grade oral squamous cell carcinoma. *Clin Cancer Res*. 2008 Jul 1;14(13):4085–95.
31. Du L, Yang Y, Xiao X, Wang C, Zhang X, Wang L, et al. Sox2 nuclear expression is closely associated with poor prognosis in patients with histologically node-negative oral tongue squamous cell carcinoma [Internet]. Vol. 47, *Oral Oncology*. 2011. p. 709–13. Available from: <http://dx.doi.org/10.1016/j.oraloncology.2011.05.017>
32. Ghazi N, Aali N, Shahrokhi V-R, Mohajertehran F, Saghravanian N. Relative Expression of SOX2 and OCT4 in Oral Squamous Cell Carcinoma and Oral Epithelial Dysplasia. *Rep Biochem Mol Biol*. 2020 Jul;9(2):171–9.

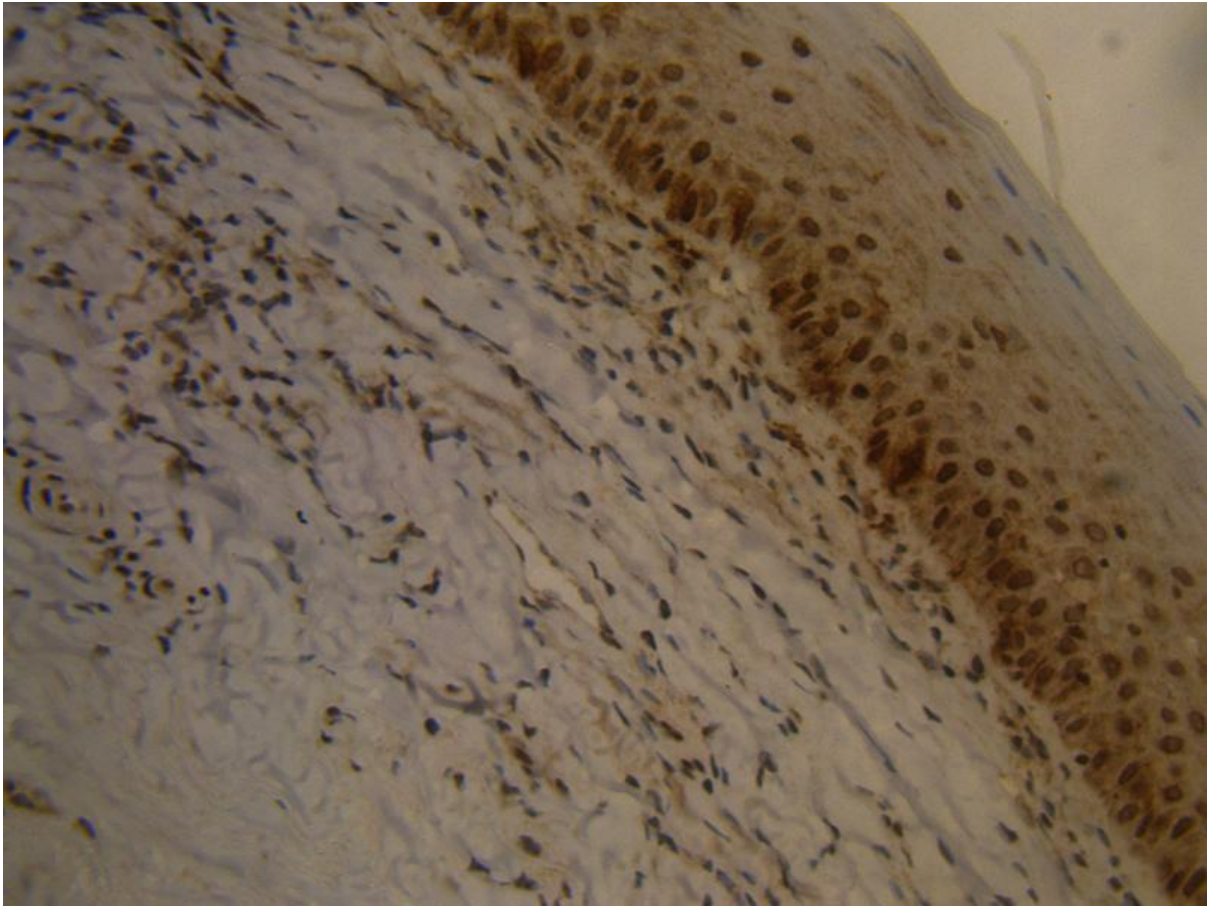
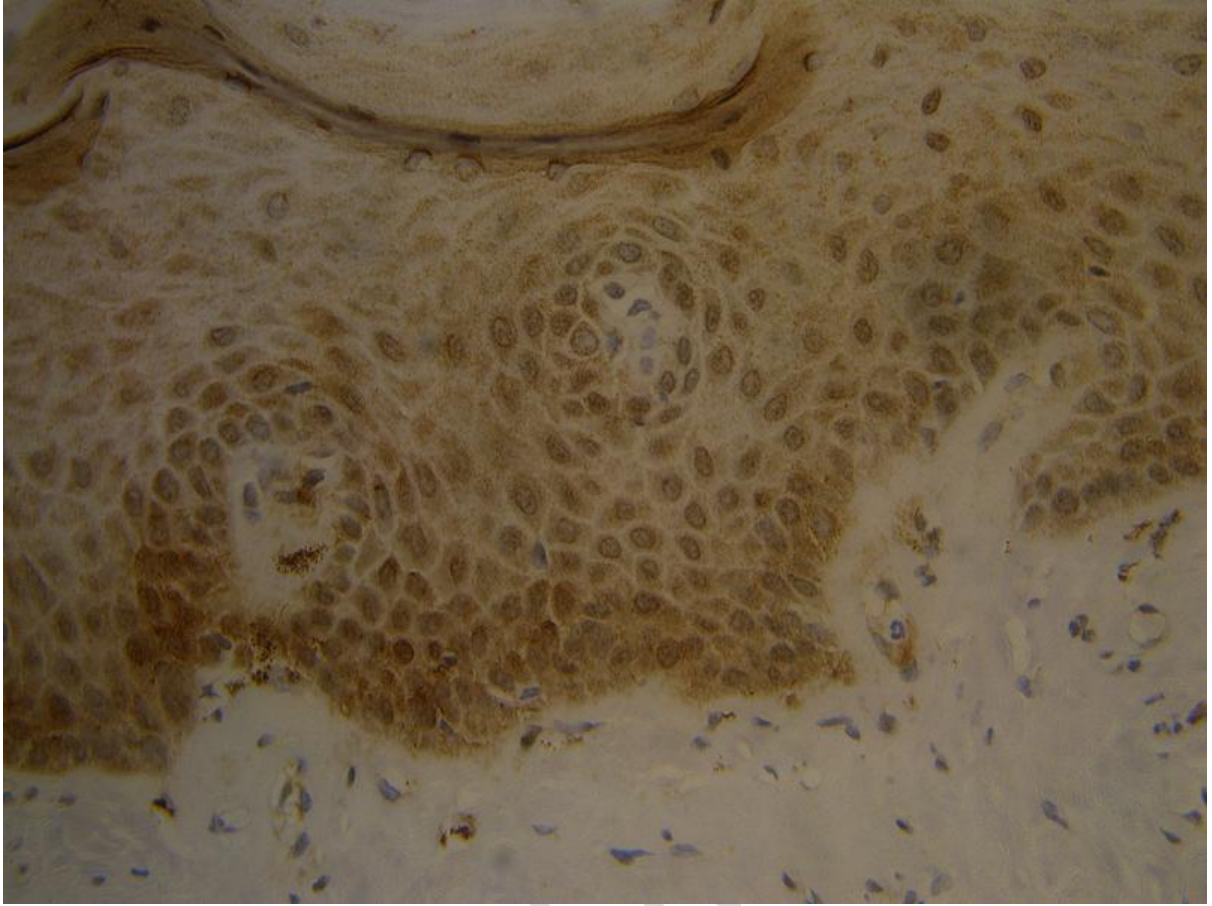


Fig 1: Immunohistochemical expression Sox2 in OSMF cases
Fig 2: Immunohistochemical expression Oct4 in OSMF cases

UNDER REVIEW



UNDER PEEL