

DIAGNOSTIC DILEMNA : A CASE OF ISOLATED FOOT FROP PRESENTING TO THE ORTHOPAEDIC OUTPATIENT DEPARTMENT

ABSTRACT

Foot drop is a condition in which the patient is unable to or has difficulty performing dorsiflexion of the ankle joint. The causes of said condition are Lower motor neuron disease or Upper motor neuron disease with the former being much more common than the latter. We hereby present a case of a 41 year old male who presented to the Outpatient Department with complaints of difficulty in walking and weakness of the left foot since the past 4 months. Neurological examination showed 1/5 power of the left ankle dorsiflexors along with the presence of ankle clonus on the left side. Radiological investigations of the spine did not show any abnormality. Nerve conduction study of the lower limbs was also found to be normal. A plain CT scan of the brain showed the presence of a hyperdense lobulated mass on the right parietal lobe. Patient was referred to Neurosurgery after diagnosis was made where he underwent surgery for removal of the lesion. Patient's ankle dorsiflexion power improved to 4/5 three weeks post surgery.

INTRODUCTION

Foot drop is a condition in which the patient loses the ability to dorsiflex the foot at the ankle joint secondary to either a Lower motor neuron or an Upper motor neuron cause. It may be associated with Extensor Hallucis Longus weakness. The relatively common causes of foot drop include Intervertebral disc prolapse at L4-L5 level and common peroneal nerve neuropathy. UMN causes leading to isolated foot drop are rare and are thus likely to be missed. This might result in a delay in the treatment or misdiagnosis of the patient.

CASE PRESENTATION

A 41 year old male presented to the OPD with complaints of difficulty in walking and weakness of the left foot since 6 months. Patient started having difficulty in putting on and holding on to his slippers. Weakness was insidious in onset and progressive. He had no history of low back pain or numbness in the lower limbs. No history of trauma to the proximal aspect of left leg. On clinical examination, he had a high stepping gait on the left side. The tone of the lower limb muscles was normal. Sensation over bilateral lower limbs was intact and equal. On the left side, the power of ankle dorsiflexion was 1/5 and of the Extensor Hallucis Longus was 3/5. Power in all other muscle groups was 5/5. Knee and ankle jerks were brisk bilaterally. Superficial plantar reflex showed flexor response on both sides. Ankle clonus seen on the left side. X-ray and MRI of the spine showed no abnormalities. The patient further underwent a Nerve conduction study of both lower limbs which was unremarkable. On doing a Plain CT scan of the brain, a large, hyperdense, lobulated, extra axial parasagittal lesion was seen in the right parietal lobe.

DISCUSSION

Foot drop can be caused due to Central and Peripheral causes. Central causes are relatively rare and most often the cause of foot drop is peripheral. Some common peripheral conditions are Lumbar radiculopathy at L4-L5 intervertebral disc level , common peroneal nerve injury, sciatic nerve affection or iatrogenic injury to the nerves.

Upper motor neurons are found in the brainstem and cerebral cortex and synapse with the Lower motor neurons at the anterior horn of the spinal cord. These central causes can take the form of tumours, compression of the spinal cord, infarcts or demyelinating plaques. Tumours are typically found in the parasagittal region and commonly comprise of meningiomas, gliomas or astrocytomas. These tumours have mass effect over the medial part of the motor homunculus which controls the motor activity of the foot and ankle and cause symptoms in this manner.

Narenthiran, Ganesalingam et al. published that only 18 cases of central foot drop have been reported in English language literature out of which 6 have been parasagittal meningiomas with the other causes being gliomas, cerebral contusions, abscess or demyelinating plaque.

CONCLUSION

Foot drop caused due to central lesions are relatively rare and this might result in the misdiagnosis or delay in the treatment . In conclusion , it is advisable to look for central lesions as a cause of foot drop when the common causes have been ruled out or if the symptoms are atypical or a combination of Lower motor neuron and Upper motor neuron features.

CASE ILLUSTRATION

FIG 1: CT scan report 1

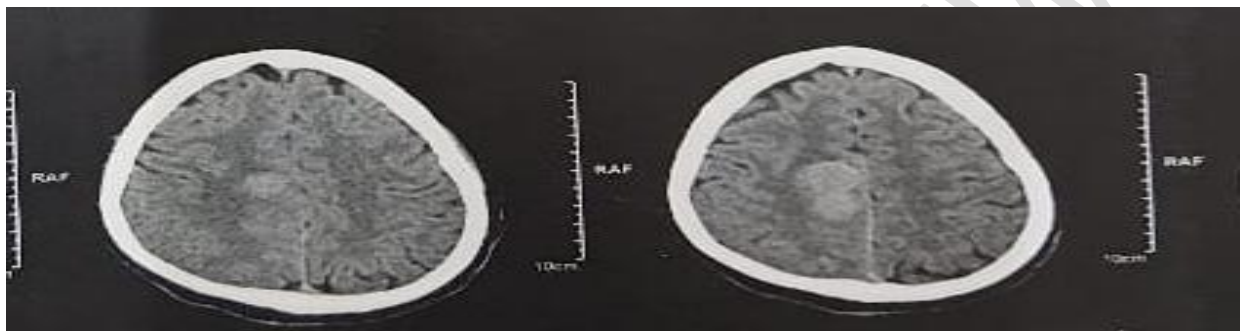
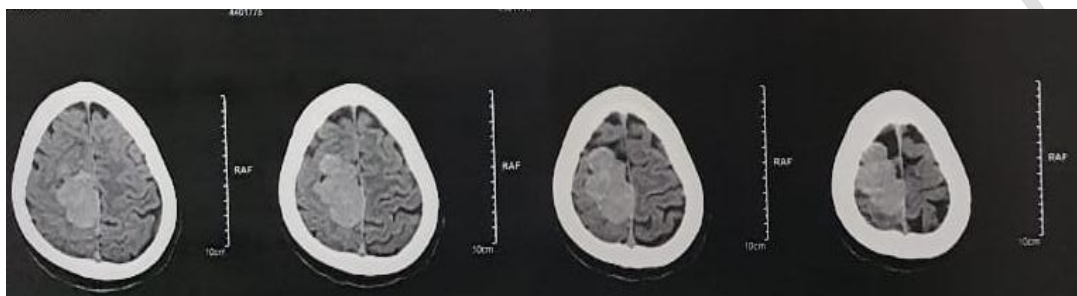


FIG 2: CT scan report 2



REFERENCES

1. Narenthiran, Ganesalingam et al. "Clinical features of central isolated unilateral foot drop: A case report and review of the literature." *Surgical neurology international* vol. 2 27. 14 Mar. 2011, doi:10.4103/2152-7806.77594
2. Westhout, Franklin D et al. "Central causes of foot drop: rare and underappreciated differential diagnoses." *The journal of spinal cord medicine* vol. 30,1 (2007): 62-6. doi:10.1080/10790268.2007.11753915
3. Carolus AE, Becker M, Cuny J, Smektala R, Schmieder K, Brenke C. The Interdisciplinary Management of Foot Drop. *Dtsch Arztebl Int.* 2019 May 17;116(20):347-354. doi: 10.3238/arztebl.2019.0347. PMID: 31288916; PMCID: PMC6637663.
4. Tural S, Konya D, Sun IH, Gercek A, Ozgen S, Pamir NM. Foot drop: the first sign of an intracranial tumor? *J Clin Neurosci.* 2007 May;14(5):490-2. doi: 10.1016/j.jocn.2006.01.028. PMID: 17386371.
5. Adams RD, Victor M: Principles of neurology. 3rd ed. New York: McGraw-Hill pp90-96, 1985