

**PREVALENCE OF DENTURE STOMATITIS AMONG PATIENTS
VISITING PRIVATE DENTAL HOSPITAL IN CHENNAI - AN
INSTITUTIONAL STUDY**

Running Title: An Institutional study based on the prevalence of denture stomatitis among patients visiting private Dental hospitals in Chennai .

ABSTRACT :

Aim: The aim of the study was to assess the prevalence of denture stomatitis among visiting private dental colleges in Chennai .

Introduction: Denture stomatitis is the inflammation of the denture bearing mucosa mostly affecting elderly population. The classical signs of denture stomatitis are burning sensation , bad taste , discomfort and sometimes they are asymptomatic. It occurs mostly under the upper denture due to less salivary gland , high retention, poor cleansing activity of the tongue .

Materials and method: This is a descriptive study which was performed under a university setting in which the data of patients who were diagnosed with denture stomatitis in the department of oral medicine at a private dental college in Chennai, India from June 2019-February 2021 was collected by reviewing patient records and the analysis of data of n =5,35,951 was done. The parameters such as age of the patient , gender of the patient , site of lesion and clinic type were noted in the study. The collected data was compiled , reviewed , tabulated and imported to spss software (version 22.0) for statistical analysis.

Results and discussion: The prevalence of denture stomatitis is about 30.58% and more common among the age group of 70-79 years and had a more female prediction. The most common site of denture stomatitis was the upper arch (80%) and most of the patients had undergone treatment in Undergraduate clinics (86.78%) .

Conclusion : Thus the knowledge of prevalence of denture stomatitis and correlation with various parameters is essential in dental practices for improving clinical performance.

Keywords: Denture stomatitis, denture, prevalence, innovative technology, novel method

INTRODUCTION:

The term denture stomatitis refers to the inflammation of the denture-bearing mucosa which affects mostly an elderly population of denture wearers(1) . The alternative name for this condition, "denture sore mouth", indicates it is painless and asymptomatic. The appearance of affected mucosa is red (erythematous) , swollen (edematous) and also has petechial hemorrhage (pin-points of bleeding). This usually occurs beneath an upper denture. It is accompanied by angular cheilitis, which is inflammation of the corners of the mouth, and is seen in association with *Candida albicans*. Stomatitis rarely develops under a lower denture. The affected mucosa is sharply defined with the shape of the covering denture. Patients complain of burning sensation, discomfort, or bad taste, but in most cases they are unaware of the problem(2). The etiology of the disease is multifactorial and factors associated with the development of denture stomatitis include denture trauma, continuous denture wearing, salivary flow, denture cleanliness, nocturnal wearing , denture base material, age of denture, smoking, dietary factors, and pH of denture plaque. Other factors include xerostomia (dry mouth), diabetes or a high carbohydrate diet and even human immunodeficiency virus (HIV) can rarely be an underlying factor. Poorly fitting dentures also cause pressure on the mucosa and mechanical irritation which lead to the similar clinical appearance, but this is rare .

The Newton classification of denture-related stomatitis into three types based on severity. Type one may represent an early stage of the condition, while type two is the most common and type three is uncommon. Type 1 is Localized inflammation or pinpoint hyperemia, Type 2 is More diffuse erythema (redness) involving part or all of the mucosa which is covered by the denture and Type 3 is Inflammatory nodular/papillary hyperplasia usually on the central hard palate and the alveolar ridge.

Yeast infection of the oral mucosa is a common condition predominantly affecting either a denture-wearing elderly population or those of all ages with prior local disturbance of the oral environment or systemic illness(3). Yeast cells have the capability to adhere to the denture and form colonies over the oral surfaces including mucosa and acrylic dentures and their co-aggregate with other bacteria. *Candida* species are increasingly associated with biomaterial-related infections at both the oral and systemic levels that are characterized by the formation of biofilms on these surfaces leading to clinically refractory disease. Dental appliances such as dentures , appliances have the potential to alter the oral microbiota(4). A microbial plaque composed of bacteria , yeasts , debris which is formed on the fitting surface of the denture and on the mucosa which is covered. Over a period of time , this plaque may be colonized by

Candida species. The local environment under a denture is more acidic due to less exposure to cleansing action of tongue and less salivary flow since lesser salivary glands are present in the upper arch, which favors high chance of Candida enzymatic activity and causes inflammation in the mucosa.

The diagnosis is by the clinical appearance, and swabs are taken from the surface of the denture. The most important feature of this treatment is to improve the denture hygiene, i.e. no nocturnal usage of denture, cleaning and disinfecting it, and storing it overnight in an antiseptic solution. The prevalence of oral mucosal lesions associated with wearing removable dentures decreases with age and affects women more than men. Therefore, it was hypothesised that oral hygiene is not only the reason for these lesions and that age of the denture also has an influence on denture stomatitis. Our team has extensive knowledge and research experience that has translated into high quality publications (5),(6),(7),(8),(9),(10),(11),(12),(13),(14),(15),(16),(17),(18),(19),(20),(21),(22),(23),(24). The main aim of this study is to assess the prevalence of denture stomatitis among patients visiting private dental hospitals in Chennai.

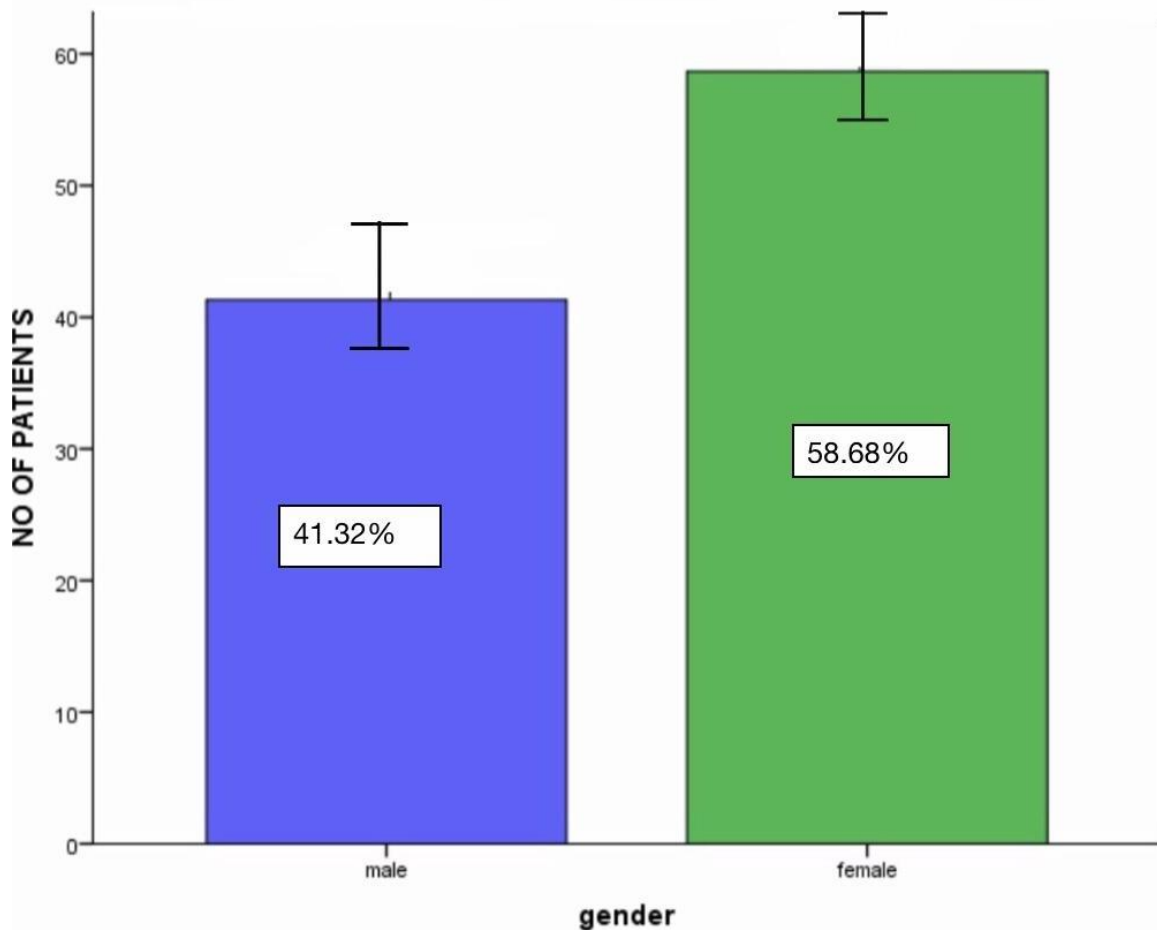
MATERIALS AND METHOD

This was a descriptive study which was performed in a university setting where the required data of patients who were diagnosed with denture stomatitis between 20-80 years of age reported to private dental college and hospitals, Chennai, India from June 2019- February 2021. The data was collected by reviewing the patient records and cross verified using photographs, reviewed by a reviewing expert and the data were tabulated in Microsoft Excel. The sample size of the study who were diagnosed as denture stomatitis was found to be n = 455 among 5,35,951 patients. The ethical approval was obtained from the institutional ethical committee (ethical approval number : (SDC/SIHEC/2021/DIASDATA/O619-0320)). The tabulated data was imported to spss software (statistical package for social studies) version 22.0 (IBM corporation) for statistical analysis. Collection of data was done by simple random sampling methods within the university to minimise sampling bias. There is a high internal validity and low external validity in our study. The study included patients diagnosed with denture stomatitis. Improper and incomplete data, repeated data, were excluded from the study. The parameters such as age of the patient, gender of the patient, site of lesion and

clinic type were noted in the study . Chi square test was used to compare the groups ($p < 0.05$) was considered significant and the results were interpreted .

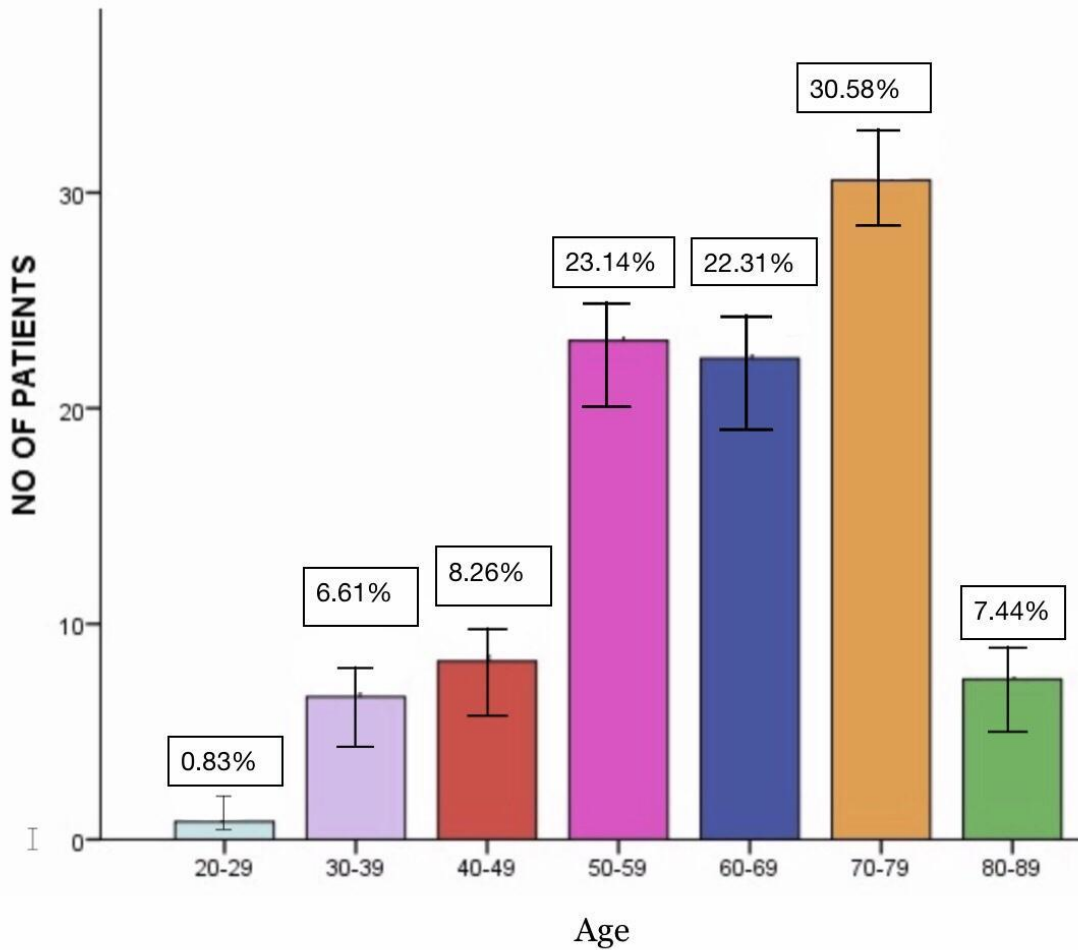
RESULTS :

The current study shows the prevalence of denture stomatitis among patients visiting private Dental hospitals in Chennai. Out of $n=455$ patients who had denture stomatitis , 41.3 % were males and 58.6% were females(fig1) .The age group of the patients , 0.83% were in the age group of 20-29 years , 6.6% were in the age group of 30-39% years , 8.26% were in the age group of 40-49 years ,23.14% were in the age group of 50-59 years , 22.31 % were in the age group of 60-69 years, 30.58 % were in the age group of 70-79 years ,7.44 % were in the age group of 70-79 years , 0.83% were in the age group of 80-89 years (fig 2) . The correlation between the site of denture stomatitis and gender of the patients in that , 36.36% of the male and 53.72% of females had lesions in the upper arch , 0.83% of male and 1.65% of female had lesion in lower arch and 4.13% of male and 3.31% of female had lesion in both arches (fig 3) . 86.78% had treatment in Undergraduate clinics and 13.22% were treated in Postgraduate clinics (fig 4) .



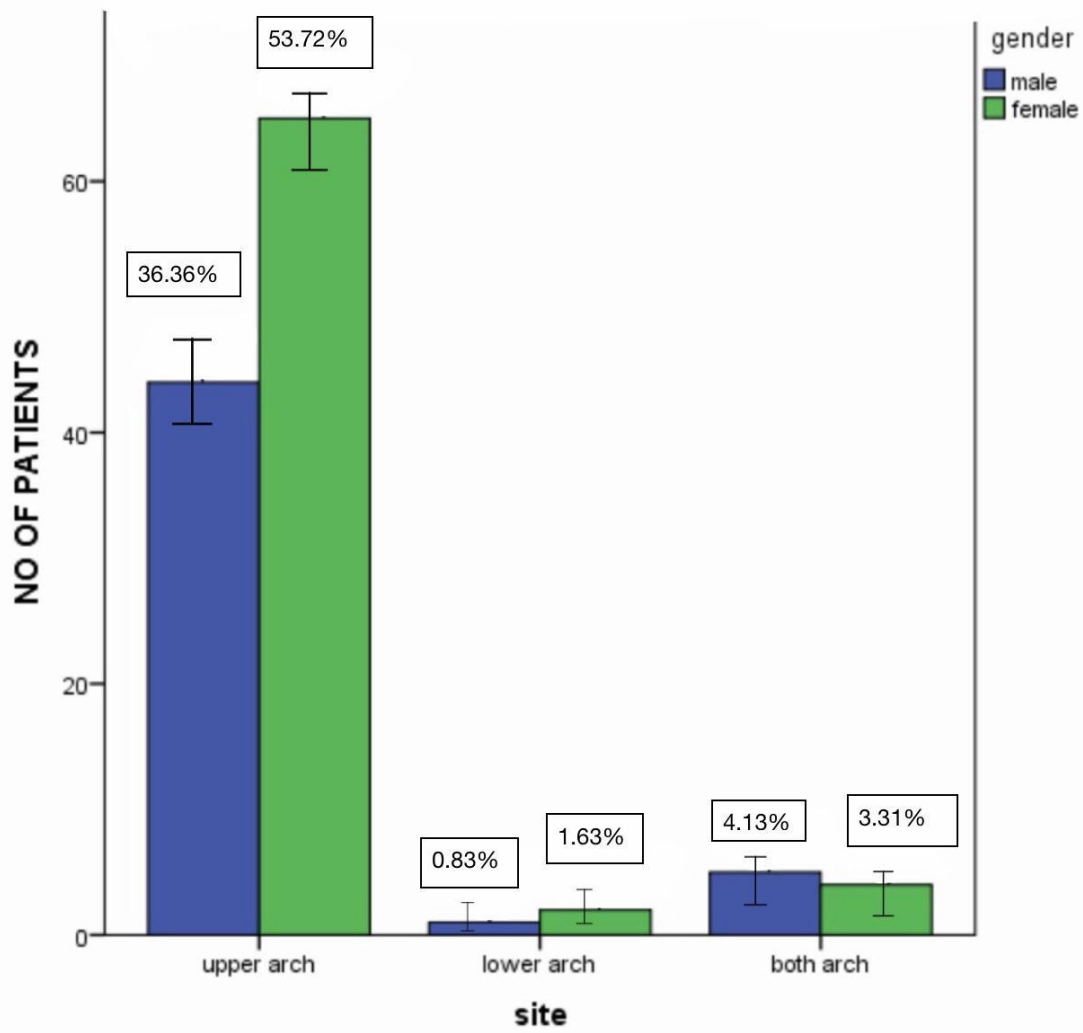
Error bar 95% of ci

Figure 1 : The bar graph depicts the prevalence of denture stomatitis between different genders of the patients visiting the outpatient department of general medicine at a private dental hospital in Chennai . The percentage of the number of patients is plotted along the y axis and the gender of the patient is plotted along the x-axis . blue colour denotes male and green colour denotes female . There is a high prevalence of denture stomatitis among the females . However, this is not statistically significant (chi square test , $p=0.314$; $p> 0.05$, not significant) .



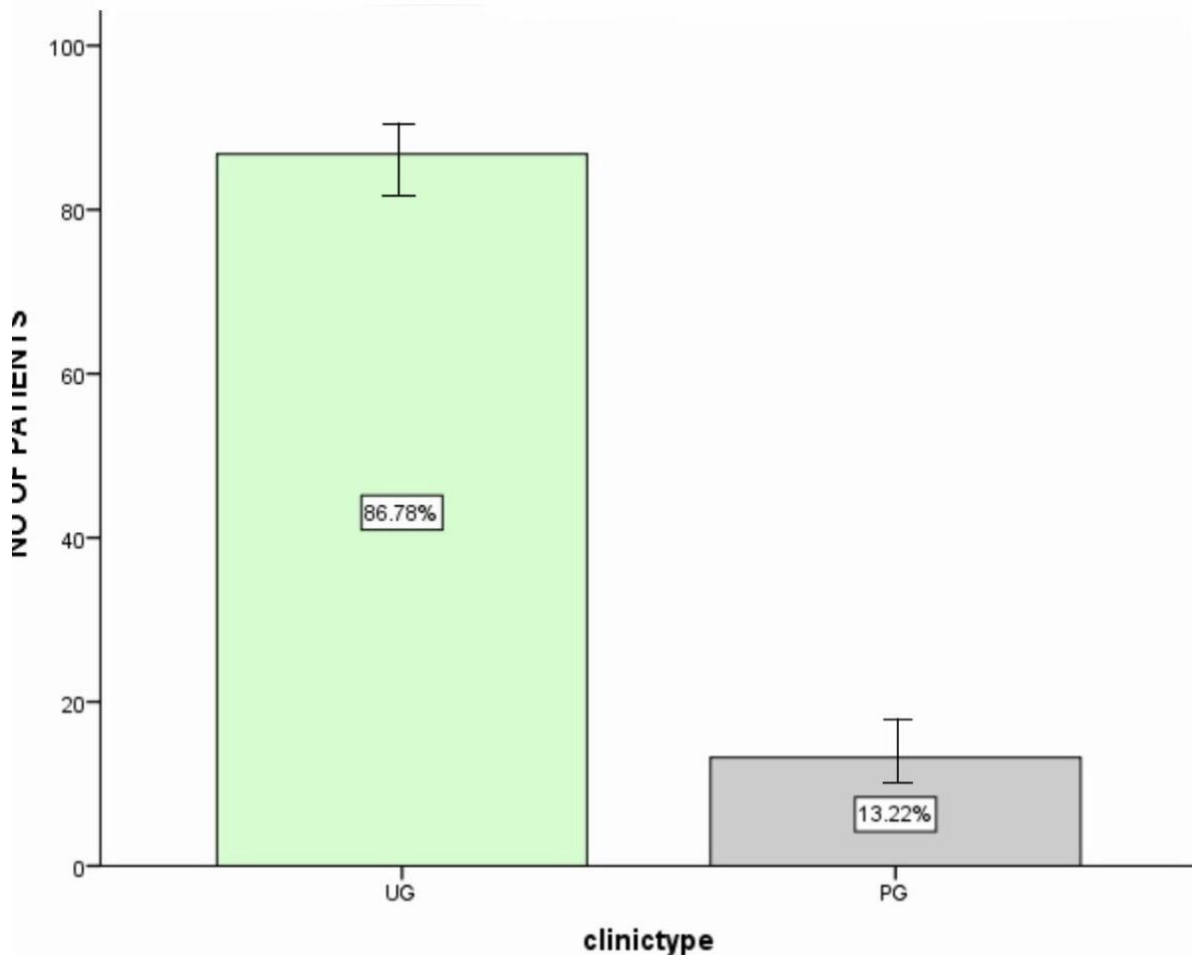
Error bar 95% of ci

Figure 2: The bar graph depicts the prevalence of denture stomatitis between different age groups of the patients visiting the outpatient department of general medicine at a private dental hospital in Chennai . The percentage of the number of patients is plotted on y axis and the age group of the patient is plotted along the x-axis . Light blue colour denotes age group of 20-29 years , lavender colour denotes age group of 30-39 years , red colour denotes age group of 40-49, pink colour denotes age group of 50-59 , dark blue colour denotes age group of 60-69, orange colour denotes age group of 70-79 and green colour denotes age group of 80-89 .However, this is not statistically significant (chi square test , $p=0.561$; $p> 0.05$, not significant) .There is a high prevalence of denture stomatitis among the age group of 70-79 years.



Error bar 95% of ci

Figure 3 : The bar graph depicts the association between the site of lesion of denture stomatitis between male and female patients visiting the outpatient department of general medicine at a private dental hospital in Chennai . The percentage of the number of patients is plotted on y axis and site of lesion of denture stomatitis is plotted along the x-axis. Blue colour denotes male and green colour denotes female. There is statistically significant between gender of the patient and site of lesion included in the present study with chi square value -22.34 and $p=0.03$ ($p<0.05$), hence statistically significant, providing that there is a higher prevalence of denture stomatitis is seen in the upper arch for males (53.72%) .



Error bar 95% of ci

Figure 4 : The bar graph depicts the prevalence of denture stomatitis treated among different clinics visiting the outpatient department of general medicine at a private dental hospital in Chennai . The percentage of the number of patients is plotted on y axis and the clinic where the patient is plotted along the x-axis . Light green colour denotes Undergraduate clinic and grey colour denotes Post graduate clinic. However, this is not statistically significant (chi square test , $p=0.432$; $p> 0.05$, not significant) .There is a high prevalence of denture stomatitis treated among the undergraduate clinics .

DISCUSSION :

The prevalence of denture stomatitis and the associated risk factors differ in the various

studies, mainly because of differences in research methodology (age of the study group, dental status of the study group, Dental School patients or community population, institutionalised or non-institutionalised patients, different method of assessment of various factors and statistical analysis, subjectivity of classification)(25). The prevalence of denture stomatitis in the present study was only 0.08%. The rate of incidence is lesser which might be attributed to wrong diagnosis of stomatitis as other systemic manifestation or other oral blisters. In a study done by Geering et al, the rate of incidence of the denture stomatitis was higher to 25 % among the other oral mucosal lesions(26). This increased rate is due to poor fitting denture, poor oral hygiene, increased candida infection in old age people. In this study denture stomatitis was more prevalent among the age group of 70-79 years, with certainty of 30.58% (chi square test, $p=0.561$; $p>0.05$) were affected (fig2). Age was not related to any type of denture stomatitis as many authors agree(27), whereas others report lower prevalence with increasing age(28). Smoking was more frequent in denture stomatitis patients. MacEntee et al also observed a significant association between tobacco use and denture-induced lesions in a group of Canadians older than 75 years of age and Shulman et al found an association between smokers of >15 cigarettes/day and stomatitis. The histopathological alterations caused by smoking could increase tissue vulnerability to the condition. In this study the denture stomatitis was more predominant in the female patient rather than male, with the measure of 41.3 % were male and 58.6% were female (chi square test, $p=0.314$; $p>0.05$) (fig1) which was contra indicated by the study done by mc et al(26), this could be related to the increased frequency of smoking among men, particularly in older age. MacEntee et al. also reported an increased prevalence of denture-induced lesions (stomatitis, hyperplasia, angular cheilitis) in men. However, most authors reported that denture stomatitis was more frequently observed in women but those findings were not always statistically significant(29). Around 13.22 % of the patients were treated in the postgraduate clinic (chi square test, $p=0.432$; $p>0.05$) (fig 4). Our study results were in accordance with previous literature which point out postgraduates are experts in treating patients exclusively, this is due to the fact the post graduates are well versed in treating patients and also have vast knowledge about the subject compared to the undergraduates. This might be a contributing factor for lesser incidence of denture stomatitis among the patients treated in post graduate clinics (26). However, under effective training and knowledge on how to handle and manage patients, undergraduates can also be skilled in treating and managing patients.

The most important factor associated with denture stomatitis in the present study was the continuous wearing of the denture. The most common site of denture stomatitis is the upper

arch where 36.36% of them were male and 53.72% of them were female (chi square test , $p=0.03$; $p<0.05$) (fig3) . None of the participants who rarely wore their dentures presented with denture stomatitis. This finding is supported by many researchers. Although the cause of denture stomatitis seems to be multifactorial there were some primary risk factors involved, such as denture trauma and candidal infection, both associated with continuous denture-wearing(30).In this study, poor retention of the maxillary denture, causing increased movement during function was associated with increased prevalence of denture stomatitis. Continuous denture-wearing also increases the exposure to yeasts existing on the fitting surface of the prosthesis(31). The reduced saliva flow under the fitting surface of the denture cannot adequately clean the area and increases the presence of microorganisms. The tongue cannot perform its cleaning action whereas the elevation of the temperature under the denture could also increase the microorganism population.Despite several advances in material science, still there is a huge prevalence of denture stomatitis. Special emphasis should be placed on the instructions to these patients on the use and maintenance of their dentures and the necessity for regular dental check ups.

The study was geographically limited and predominantly considered of the South Indian population. Data which were unclear were excluded thereby reducing the sample size . Within the limit of the study, it was found that prevalence of denture stomatitis is more in the age group of 70-79 years with more female prediction. To ascertain the results of this study and to increase the level of significance, the sample size and the geographic area of coverage should be extended to all parts of south India. Conducting a multicentered study with an extended geographic area and a wide range of population in the future we can get better results . Establishing the proper diagnosis is a necessary condition for the effective treatment for the denture stomatitis. Thus this knowledge of prevalence of denture stomatitis and correlation with various parameters is essential in a dental practice for clinical performance.

CONCLUSION

Denture stomatitis is the oral mucosal lesion caused due to wearing of dentures usually involving *Candida* species. Less common forms of denture stomatitis may be due to mechanical trauma or an allergic contact reaction. The early recognition of denture stomatitis provides an alert to the clinician with valuable diagnostic assets, this can be achieved by thorough examination of the oral cavity in such patients is of almost importance. Finally

,establishing the proper diagnosis is an essential condition for effective treatment of the underlying diseases. In addition to topical or system anti fungal treatment,denture stomatitis requires excellent oral hygiene and replacement of any poor fitting dentures.

COMPETING INTERESTS DISCLAIMER:

Authors have declared that no competing interests exist. The products used for this research are commonly and predominantly use products in our area of research and country. There is absolutely no conflict of interest between the authors and producers of the products because we do not intend to use these products as an avenue for any litigation but for the advancement of knowledge. Also, the research was not funded by the producing company rather it was funded by personal efforts of the authors.

REFERENCE :

1. Bergendal T. Treatment of Denture Stomatitis: A Clinical, Microbiological and Histological Evaluation. 1982. 37 p.
2. Karim JFA, University of Sulaimani, Kareem SAL, University of Sulaimani. A Clinical Study on Denture Stomatitis in a Group of Denture Wearers in Sulaimani Governorate [Internet]. Vol. 10, Journal of Zankoy Sulaimani - Part A. 2007. p. 35–41. Available from: <http://dx.doi.org/10.17656/jzs.10161>
3. Moraes GS, Albach T, Ramos IE, Kopacheski MG, Cachoeira VS, Sugio CYC, et al. A novel acrylic resin palatal device contaminated with *Candida albicans* biofilm for denture stomatitis induction in Wistar rats. *J Appl Oral Sci.* 2021 Apr 19;29:e20200865.
4. Bajunaid SO, Baras BH, Balhaddad AA, Weir MD, Xu HHK. Antibiofilm and Protein-Repellent Polymethylmethacrylate Denture Base Acrylic Resin for Treatment of Denture Stomatitis. *Materials* [Internet]. 2021 Feb 25;14(5). Available from: <http://dx.doi.org/10.3390/ma14051067>
5. Princeton B, Santhakumar P, Prathap L. Awareness on Preventive Measures taken by Health Care Professionals Attending COVID-19 Patients among Dental Students. *Eur J Dent.* 2020 Dec;14(S 01):S105–9.
6. Mathew MG, Samuel SR, Soni AJ, Roopa KB. Evaluation of adhesion of *Streptococcus mutans*, plaque accumulation on zirconia and stainless steel crowns, and surrounding gingival inflammation in primary molars: randomized controlled trial. *Clin Oral Investig.* 2020 Sep;24(9):3275–80.

7. Sridharan G, Ramani P, Patankar S, Vijayaraghavan R. Evaluation of salivary metabolomics in oral leukoplakia and oral squamous cell carcinoma. *J Oral Pathol Med*. 2019 Apr;48(4):299–306.
8. R H, Hannah R, Ramani P, Ramanathan A, Jancy MR, Gheena S, et al. CYP2 C9 polymorphism among patients with oral squamous cell carcinoma and its role in altering the metabolism of benzo[a]pyrene [Internet]. Vol. 130, *Oral Surgery, Oral Medicine, Oral Pathology and Oral Radiology*. 2020. p. 306–12. Available from: <http://dx.doi.org/10.1016/j.oooo.2020.06.021>
9. Antony JVM, Ramani P, Ramasubramanian A, Sukumaran G. Particle size penetration rate and effects of smoke and smokeless tobacco products - An invitro analysis. *Heliyon*. 2021 Mar 1;7(3):e06455.
10. Sarode SC, Gondivkar S, Sarode GS, Gadbail A, Yuwanati M. Hybrid oral potentially malignant disorder: A neglected fact in oral submucous fibrosis. *Oral Oncol*. 2021 Jun 16;105390.
11. Hannah R, Ramani P, WM Tilakaratne, Sukumaran G, Ramasubramanian A, Krishnan RP. Author response for “Critical appraisal of different triggering pathways for the pathobiology of pemphigus vulgaris—A review” [Internet]. Wiley; 2021. Available from: <https://publons.com/publon/47643844>
12. Chandrasekar R, Chandrasekhar S, Sundari KKS, Ravi P. Development and validation of a formula for objective assessment of cervical vertebral bone age. *Prog Orthod*. 2020 Oct 12;21(1):38.
13. Subramanyam D, Gurunathan D, Gaayathri R, Vishnu Priya V. Comparative evaluation of salivary malondialdehyde levels as a marker of lipid peroxidation in early childhood caries. *Eur J Dent*. 2018 Jan;12(1):67–70.
14. Jeevanandan G, Thomas E. Volumetric analysis of hand, reciprocating and rotary instrumentation techniques in primary molars using spiral computed tomography: An in vitro comparative study. *Eur J Dent*. 2018 Jan;12(1):21–6.
15. Ponnulakshmi R, Shyamaladevi B, Vijayalakshmi P, Selvaraj J. In silico and in vivo analysis to identify the antidiabetic activity of beta sitosterol in adipose tissue of high fat diet and sucrose induced type-2 diabetic experimental rats. *Toxicol Mech Methods*. 2019 May;29(4):276–90.
16. Sundaram R, Nandhakumar E, Haseena Banu H. Hesperidin, a citrus flavonoid ameliorates hyperglycemia by regulating key enzymes of carbohydrate metabolism in streptozotocin-induced diabetic rats. *Toxicol Mech Methods*. 2019 Nov;29(9):644–53.
17. Alsawalha M, Rao CV, Al-Subaie AM, Haque SKM, Veeraraghavan VP, Surapaneni KM. Novel mathematical modelling of Saudi Arabian natural diatomite clay. *Mater Res Express*. 2019 Sep 4;6(10):105531.
18. Yu J, Li M, Zhan D, Shi C, Fang L, Ban C, et al. Inhibitory effects of triterpenoid betulin on inflammatory mediators inducible nitric oxide synthase, cyclooxygenase-2, tumor necrosis factor-alpha, interleukin-6, and proliferating cell nuclear antigen in 1, 2-

dimethylhydrazine-induced rat colon carcinogenesis. *Pharmacogn Mag.* 2020;16(72):836.

19. Shree KH, Hema Shree K, Ramani P, Herald Sherlin, Sukumaran G, Jeyaraj G, et al. Saliva as a Diagnostic Tool in Oral Squamous Cell Carcinoma – a Systematic Review with Meta Analysis [Internet]. Vol. 25, *Pathology & Oncology Research*. 2019. p. 447–53. Available from: <http://dx.doi.org/10.1007/s12253-019-00588-2>
20. Zafar A, Sherlin HJ, Jayaraj G, Ramani P, Don KR, Santhanam A. Diagnostic utility of touch imprint cytology for intraoperative assessment of surgical margins and sentinel lymph nodes in oral squamous cell carcinoma patients using four different cytological stains. *Diagn Cytopathol.* 2020 Feb;48(2):101–10.
21. Karunagaran M, Murali P, Palaniappan V, Sivapathasundharam B. Expression and distribution pattern of podoplanin in oral submucous fibrosis with varying degrees of dysplasia – an immunohistochemical study [Internet]. Vol. 42, *Journal of Histotechnology*. 2019. p. 80–6. Available from: <http://dx.doi.org/10.1080/01478885.2019.1594543>
22. Sarode SC, Gondivkar S, Gadail A, Sarode GS, Yuwanati M. Oral submucous fibrosis and heterogeneity in outcome measures: a critical viewpoint. *Future Oncol.* 2021 Jun;17(17):2123–6.
23. Raj Preeth D, Saravanan S, Shairam M, Selvakumar N, Selestin Raja I, Dhanasekaran A, et al. Bioactive Zinc(II) complex incorporated PCL/gelatin electrospun nanofiber enhanced bone tissue regeneration. *Eur J Pharm Sci.* 2021 May 1;160:105768.
24. Prithiviraj N, Yang GE, Thangavelu L, Yan J. Anticancer Compounds From Starfish Regenerating Tissues and Their Antioxidant Properties on Human Oral Epidermoid Carcinoma KB Cells. In: *PANCREAS*. LIPPINCOTT WILLIAMS & WILKINS TWO COMMERCE SQ, 2001 MARKET ST, PHILADELPHIA ...; 2020. p. 155–6.
25. Kossioni AE. The prevalence of denture stomatitis and its predisposing conditions in an older Greek population [Internet]. Vol. 28, *Gerodontology*. 2011. p. 85–90. Available from: <http://dx.doi.org/10.1111/j.1741-2358.2009.00359.x>
26. Geering AH, Kundert M, Kelsey CC. *Complete Denture and Overdenture Prosthetics*. 1993. 262 p.
27. Scully C. Denture-related stomatitis [Internet]. *Oral and Maxillofacial Medicine*. 2013. p. 264–7. Available from: <http://dx.doi.org/10.1016/b978-0-7020-4948-4.00040-4>
28. Araujo CB, Ribeiro AB, Fortes CV, Bueno FL, De Wever B, Oliveira VC, et al. Effect of local hygiene protocols on denture-related stomatitis, biofilm, microbial load, and odor: A randomized controlled trial. *J Prosthet Dent [Internet]*. 2021 Mar 15; Available from: <http://dx.doi.org/10.1016/j.prosdent.2020.12.018>
29. Uludamar A, Özyeşil AG, Ozkan YK. Clinical and microbiological efficacy of three different treatment methods in the management of denture stomatitis [Internet]. Vol. 28, *Gerodontology*. 2011. p. 104–10. Available from: <http://dx.doi.org/10.1111/j.1741-2358.2009.00354.x>

30. Gendreau L, Loewy ZG. Epidemiology and Etiology of Denture Stomatitis [Internet]. Vol. 20, Journal of Prosthodontics. 2011. p. 251–60. Available from: <http://dx.doi.org/10.1111/j.1532-849x.2011.00698.x>
31. Yarborough A, Cooper L, Duqum I, Mendonça G, McGraw K, Stoner L. Evidence Regarding the Treatment of Denture Stomatitis [Internet]. Vol. 25, Journal of Prosthodontics. 2016. p. 288–301. Available from: <http://dx.doi.org/10.1111/jopr.12454>

UNDER PEER REVIEW