

Study Protocol

DIAGNOSIS OF GENITAL TUBERCULOSIS BY CARTRIDGE BASED NUCLEIC ACID AMPLIFICATION TEST IN SUBFERTILE WOMEN OF RURAL HOSPITAL

Abstract

Tuberculosis has serious extra-pulmonary manifestations that are sometimes difficult to diagnose and thus left untreated. One such manifestation is female - genital tuberculosis (FGTB). Any diagnostic test is not efficient enough to prove the evidence of female genital tuberculosis. High level of clinical examination, detailed history of the patient, systemic examination, a series of tests to document *M. tuberculosis* as well as imaging techniques for characteristic structural changes are essential for the diagnosis.

There exists lot of diagnostic dilemma for genital tuberculosis in the available literature. no single test is found confirmatory except for wet culture and histopathological positivity, which may become paucibacillary extrapulmonary sites and time consuming too. cartridge based nucleic acid amplification test [CBNAAT] being a molecular test may be rapid and promising to diagnose these lesions.

The diagnostic value of CBNAAT in detection of female genital tuberculosis seems to be limited, although it has a high positive predictive value.

INTRODUCTION-

Extrapulmonary TB (EPTB) has many forms out of which common form being genitourinary Tb spread worldwide (27%) with genital TB alone accounting for 9 % of all EPTB cases.[1]

A survey by the ICMR, shows evidence which states that prevalence of Female genital tuberculosis in India has been raised from 19 % in 2011 year to 30% in 2015 year. For diagnosis and management of FGTB, a multicentric ICMR research team is working on making a nation wide applicable algorithm.[2,3]

Tb has serious extra-pulmonary manifestations that are sometimes difficult to diagnose and thus left untreated. One such manifestation is female - genital tuberculosis (FGTB), which was first identified by MORGAGNI in 1744 while performing an autopsy on a female who later died, the cause being Tuberculosis peritonitis[4,5,6].

Any diagnostic test is not efficient enough to prove the evidence of female genital tuberculosis. High level of clinical examination, detailed history of the patient, systemic examination, a series of tests to document *M. tuberculosis* as well as imaging techniques for characteristic structural changes are essential for the diagnosis.

WHO guidelines for EPTB:

Diagnosis of EPTB should be done with following the criteria along **with evidence of active EPTB:**

1. Culture-positive specimen OR

2. Positive histology OR

3. Positive clinical proof consistent ^[2].

X-ray chest, tuberculin skin test (TST), erythrocyte sedimentation rate (ESR), and blood count tests to rule out a Tuberculi focus elsewhere in the body with a proper clinical examination. Hysterosalpingography (HSG) and ultrasonography are two imaging procedures that can be used to diagnose FGTB (USG). HSG focuses on the internal structure of the female genital canal as well as tubal patency, whereas ultrasonography assesses ovarian, uterine, and extrapelvic involvement all at once. The laparoscopic findings may range from a normal appearance to tubercles on the surface, fimbrial tubal block, tubal beading, peri-tubal adhesions, peri-ovarian adhesions, tubo-ovarian mass, hydrosalpinx, and stiff tubes.

The specimen's histopathology describes probable Tuberculosis infection characteristics, as well as granulomatous caseous lesions. Tuberculosis is depicted by the presence of classic caseous with granulomas and gigantic epithelioid cells; however, these lesions can also be seen in fungal illnesses, systemic lupus erythematosus, syphilis, leprosy, rheumatoid arthritis, pneumoconiosis, and sarcoidosis.

The late secretory phase of the menstrual cycle is the most accurate period for endometrial sampling which is required for the diagnosis of large cells and tubercles.

AFB smear staining of endometrial tissue is a quick test that requires only 10 organisms per millilitre to be positive.

The minimum time to positive in LJ medium cultures is 4-8 weeks. When endometrial samples were analysed, Thangappah et colleagues found that AFB smear positive results and culture positive results were 8.3 percent and 5.2 percent, respectively, among the 72 infertile women studied. [6] The positive effect in LJ medium and BACTEC for premenstrual symptoms was demonstrated by Goel et al. The proportions of the samples were 1.83 percent and 8.8 percent, respectively. [10]

PCR is a fast molecular- method for demonstrating nucleic-acid amplification sequences unique to Mycobacteria tuberculosis and other various mycobacteria in people with FGTB. PCR tests take 8-12 hours to complete and can identify 10 bacilli/ml, even dead bacilli. Although PCR has a higher sensitivity than micro-culture and histopathological report, and its specificity in diagnosing FGTB can be as high as 100 percent, it also produces false positive results, thus it cannot be used alone. Methods for diagnosing tuberculosis have been well researched and are currently in use. Nucleic-acid amplification tests (NAAT) give results in a few hours, as established in the literature with the use of amplification equipment.

The diagnosis of genital TB necessitates a high level of suspicion as well as a multimodal inquiry technique. Despite numerous technological advancements, the issue of catching this age-old disease persists.

In this study, we want to see how effective the CBNAAT molecular approach is at diagnosing genital TB in subfertile women who visit the Acharya Vinoba Bhawe Rural Hospital's infertility clinic.

RATIONALE

There exists lot of diagnostic dilemma for genital tuberculosis.in the available literature .no single test is found confirmatory except for wet culture and histopathological positivity,which may become paucibacillary extrapulmonary sites and time consuming too.'CBNAAT' being a molecular test may be rapid and promising to diagnose these lesions.

Research question: Population: subfertile women of rural hospital

Intervention: CARTRIDGE BASED NUCLEIC ACID AMPLIFICATION TEST [CBNAAT]

Comparison:with other available diagnostic modalities

Outcome: POSITIVE CASES WITH CBNAAT

HYPOTHESIS: CBNAAT has better sensitivity and specificity in diagnosing extrapulmonary genital TB.

AIM-

This study aimed to evaluate the role of CBNAAT a molecular test in diagnosing genital TB amongst subfertile women of the rural hospital.

OBJECTIVES-

1.To conduct Cartridge based nucleic acid amplification test CBNAAT test in subfertile women attending infertility clinic.

- 2.To conduct detailed clinical examination and perform other routine investigations for diagnosing genital tuberculosis.
- 3.To analyze positivity of CBNAAT in selected population.

UNDER PEER REVIEW

METHODOLOGY-

Study design and population:

An **observational prospective, tertiary care centre based study** will be conducted on sample size of population of *100 subfertile* who meets inclusion and exclusion criteria of this study after a elaborate history and clinical examination all patients will undergo investigations including pelvic sonogram, histopathological study, and CBNAAT at wardha test tube baby centre at AVBRH,sawangi.

Inclusion criteria-

- 1.All the consecutive women visiting infertility clinic and willing to undergo endometrial biopsy.
- 2.Women with unexplained infertility.

Exclusion criterion-

Women experiencing infertility due to following causes-

- 1.infertility due to sexual disorders.
- 2.Infertility due to proven anovulation in pervious cycles.
- 3.Infertility due to endocrine dysfuction.
- 4.previous history of pelvic surgeries.
- 5.Proven history of endometriosis.
- 6.Infertility due to male factors only.

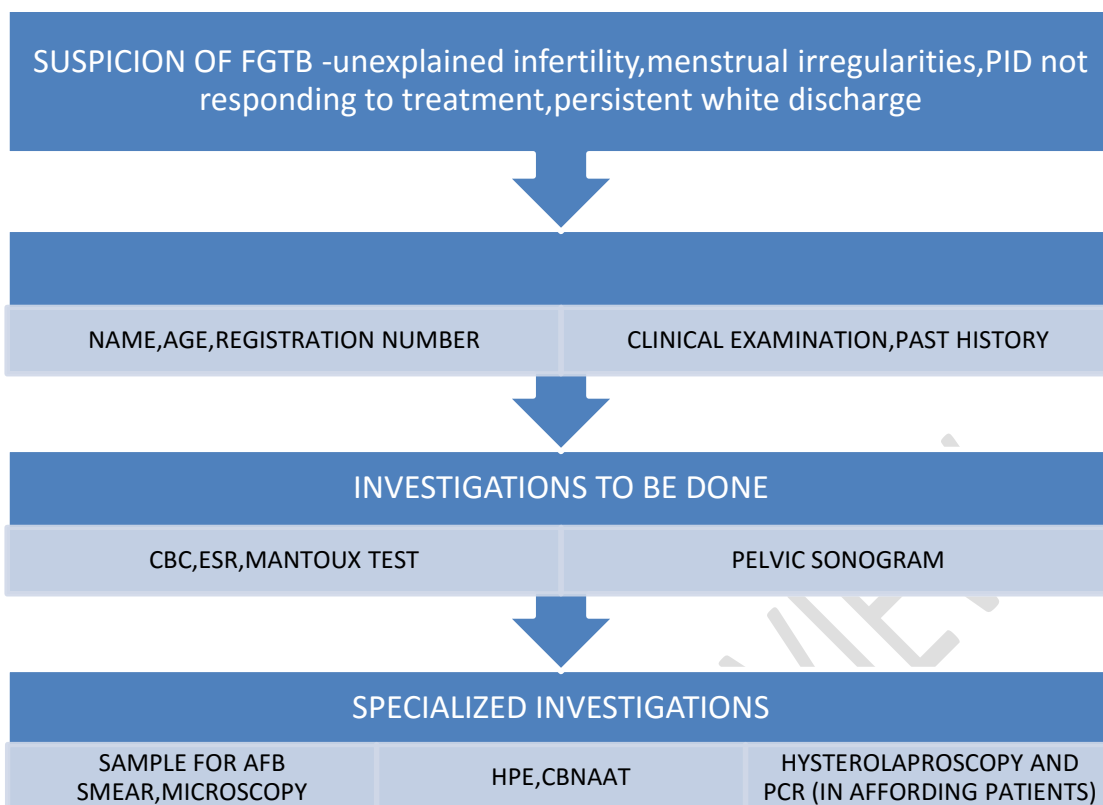
Patients will undergo routine tests (CBC, ESR, TST), after which endometrial tissue samples will be collected aseptically and mounted for AFB smear, histopathological tests, and CBNAAT, a cartridge-based nucleic acid amplification test that detects Tuberculous bacilli as well as testing for Rifampicin resistance. It's simple, quick, and inexpensive, and it doesn't require any technological expertise. Due to the use of disposable closed cartridges that prevent cross contamination, it may detect tuberculosis in under two hours and deliver accurate results. TST is employed in areas with low resources for cultural facilities.

The procedure will only be done after obtaining informed written consent from the participants and the study adheres to STROBE guidelines.

After collecting and analysing the data, the diagnostic tests used, such as pelvic USG, histopathologic examination, and CBNAAT positivity, as well as laproscopy and PCR of endometrial aspirate for patients who can afford it, will be compared for accurately diagnosing female genital tuberculosis [FGTB] by calculating sensitivity, specificity, positive predictive value, and negative predictive value; after that, these modalities will be compared for accurately diagnosis.

On basis of which reliability and accuracy of the tests will be observed.

Fig. 1. SUSPICION OF FGTB



Sample size 100 calculated by-

$$N = \frac{Z^2 \cdot P \cdot (1-P)}{D^2}$$

Z42 is the level of significance at 5% i.e. 95%

Confidence interval = 1.96

P=prevalence of FGTB in India =1-19% = 4% =0.04

D=derived error of margin =4% =0.04

$$n = \frac{(1.96)^2 \times 0.04 \times (1-0.04)}{(0.04)^2}$$

=92.19 approx 100 patients needed for the study.

Software to be used SPSS 22.0 Version,Graphpad Prism 7.0 Ver

Statistical analysis to be done -sensitivity,specificity,negative predictive value,positive predictive value

Study design:Prospective observational study

Power of the test :80%

Level of significance :5%

RESULTS:

The diagnostic value of CBNAAT in detection of female genital tuberculosis seems to be limited,although it has a high positive predictive value.

The various diagnostic modalities for genital tuberculosis available for genital tuberculosis, will be compared with diagnostic value of CBNAAT.

Cartridge Based Nucleic Acid Amplification Test is a easy, cost effective and quite accurate and rapid test for detection of tuberculosis especially Pulmonary Tuberculosis. So to use it for detection of genital Tuberculosis will prove beneficial. This study aims to establish that Cartridge Based Nucleic Acid Amplification Test **has better sensitivity and specificity in diagnosing extrapulmonary genital Tuberculosis as compared to other conventional diagnostic tests.**

SCOPE, LIMITATIONS, IMPLICATIONS

Despite ATT treatment, the majority of females acquire vaginal tuberculosis, which leads to infertility. The conception rate for such women is low (19.2%), and the live birth rate is much lower (7%). The sole therapeutic option left for such women is IUI and embryo transfer [IVF-ET] in females whose endometrium has not been affected and has a pregnancy rate of 16.6% in every embryo transfer. If patient's fallopian tubes are damaged even after ATT, but the endometrium of the uterus responds to treatment and they have no endometrial adhesions or mild adhesions that may be removed hysteroscopically, IVF-ET is recommended. If they have endometrial TB, which destroys the endometrium and causes microscopic capillaries of the uterus to shrivel, they should consider surrogacy or adoption. [7,8]

REFERENCES-

1. Golden MP, Vikram HR. Extrapulmonary tuberculosis: An overview. *Am Fam Physician*. 2005;72:1761–8.
2. World Health Organization. WHO global tuberculosis report 2018. Geneva: WHO; 2018.
3. Grace GA, Devaleen DB, Natrajan M. Genital tuberculosis in females. *Indian J Med Res*. 2017;145:425–36.
4. Welfare; 2018. Central TB Division, Directorate General of Health Services. India TB. Report: Revised National Tuberculosis Control Programme: Annual status report.
5. Pesut D, Stojisic J. Female genital tuberculosis - a disease seen again in Europe. *Vojnosanit Pregl*. 2007;64:855–8.
6. Thangappah R, Paramasivan C N, Narayanan S. Evaluating PCR, culture & histopathology in the diagnosis of female genital tuberculosis. *Indian J Med Res* 2011;134:40-6
7. Sharma JB: Tuberculosis and obstetric and gynaecological practice. In: Studd J, TAN SL, Chervenak FA, (editors), *Progress in Obstetric and Gynaecology Philadelphia : Elsevier* 2008;18:395-427
8. Neonakis IK, Gitti Z, Krambovitis E, Spondidos DA. Molecular diagnostic tools in mycobacteriology. *J Microbiol Methods* 2008;75:1-11
9. Rakesh Arora and J.B Sharma. Female genital tuberculosis - a diagnostic and therapeutic challenge. *Indian J Tuberc* 2014;61:98-102
10. Geetika goel, khatuja ritu et al. Role of newer methods of diagnosing genital Tb in infertile women *Indian journal of pathology and microbiology* 2013; vol 56:155-157

UNDER PEER REVIEW

UNDER PEER REVIEW