

# Original Research Article

## **LIP PRINTS ANALYSIS - AN OBSERVATIONAL STUDY**

**Running title:** Analysis of lip print

### **ABSTRACT:**

#### **AIM:**

The aim of the present study is to determine the lip prints among undergraduate dental students.

#### **INTRODUCTION:**

Human identification is a universal process based on scientific principles mainly involving fingerprinting. Uniqueness is a strong point used in the analysis of fingerprints to convince the court of law. Even the lip prints are unique for an individual and can be used for identification purposes. Thus lip prints can be used to verify the presence or absence of a person at the scene of crime. The aim of this study is to analyse lip prints among undergraduate dental students.

#### **MATERIALS AND METHODS:**

The study group consisted of 50 females. The materials used were lipstick, a brush for applying the lipstick, and magnifying lens. Lipstick was applied evenly on the vermilion border of the lips and the pattern was studied.

#### **RESULTS:**

This study of lip print pattern of 50 females revealed the following observation:

No two lip prints matched each other establishing the uniqueness of lip prints and type 2 (branched Y shaped grooves) is most commonly seen.

#### **CONCLUSION:**

This study showed that lip prints are unique for an individual and hold potential promise as a supplementary tool in forensic odontology.

**KEY WORDS:** Innovative technique, Forensics, identification, lip prints, patterns, novel method.

## **INTRODUCTION:**

Fingerprints, postmortem reports, and late DNA Fingerprinting have been successful in personnel identification in the field of forensic science. Just like these methods lip prints can be instrumental in identifying a person and can be used to verify the presence or absence of a person at the scene of crime(1)(2). The wrinkles and grooves on labial mucosa called as sulci labiorum forms a characteristic pattern called as lip prints and the study of which is called cheiloscopy. This is unique to an individual just like fingerprints(3) and does not change during the life of the person(4). It can be obtained at the crime scene from clothing, glasses, cigarettes, windows and doors. Lip prints are invariable and permanent. Fischer was the first anthropologist to describe the furrows on the red part of the human lips. The use of lip prints was first studied as early as in 1932 by Edmond Locard, one of France's greatest criminologists. Apart from identifying and evidential use lip prints may also be used in detection work being the source of tactical and criminalistic information. Research studies and information regarding the use of lip prints as evidence in personnel identification and criminal investigation in forensic dentistry are very much scanty but exist as a methodology in forensic dentistry. Lemoyne Snyder in his book homicide investigation written in 1950 mentions the possible use of lip prints in the identification of the individual(5).

1. Lip print identification is acceptable within the forensic science community as a means of positive identification .
2. Lip print identification methodology although rarely used is very similar to fingerprint and is an accepted form of scientific comparison.

3. There is no dissent in the forensic science community with regard to other methodologies used or the fact that lip prints provide a positive identification.

Lip prints are unaltered from six week of intrauterine life till death. It can be visibly seen with naked eyes. Our team has extensive knowledge and research experience that has translate into high quality publications (6),(7),(8),(9),(10),(11),(12),(13),(14),(15),(16),(17),(18),(19),(20),(21),(22),(23),(24), (25)

The prime objective of the present study is to determine the lip prints of the undergraduate dental students.

## **MATERIALS AND METHODS:**

The study sample comprised 50 students of a private dental college(50 females aged around 18-20 years). Care was taken to select individuals having no lesions on the lips ,lip scars, lip deformities and individuals with known hypersensitivity to lipsticks were not included in the study.

A Dark coloured smudge free red lipstick was applied with a single stroke evenly on the vermilion border. The subjects were asked to rub both the lips to spread the lipstick. After about two minutes a lip impression was made on the paper. This served as the permanent record.Lateral parts of both upper and lower lips were not used in the study as they had very fine lip grooves and some exhibited immediate tapering.This impression was subsequently visualised with the use of magnifying lenses. The number of lines and furrows present, their length, branching and combinations were noted.The lip prints were coded keeping in account the name of the respective individuals.

In this study we followed the classification of patterns of the lines on the lips proposed by Tsuchihashi.(figure 1)

1. **TYPE 1** - clear cut vertical grooves that run across the entire lips.
2. **TYPE 1'** - similar to type 1 but do not cover the entire lip.
3. **TYPE 2** - Branching y shaped grooves.
4. **TYPE 3** - Criss cross pattern, reticular grooves.
5. **TYPE 4** - undetermined.

**FIGURE 1:**

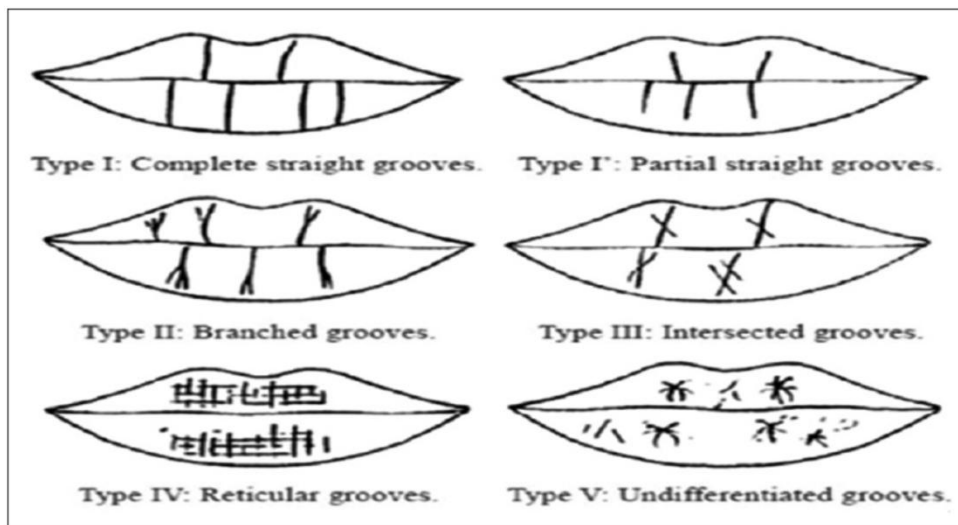


Figure 1 represents the classification of lip prints by Tsuchihashi

**FIGURE 2 :**

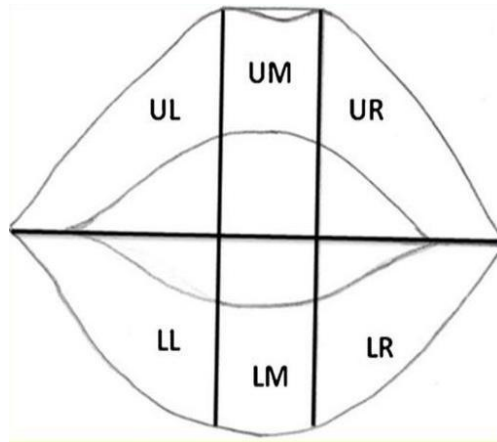


Figure 2 represents the zones of the lips

For classification the middle part of the upper and lower lips was taken as the study area. Since this fragment is almost always visible in any trace the determination of the pattern depends on numerical superiority of properties of the lines on this study area. The results obtained were verified from the coded data collected at the beginning of the study. The Data was transferred to the excel sheet and was analysed using SPSS software version 23.

## RESULTS:

The study of lip print pattern of 50 females revealed the following observation:

8% of the students are in the age 17, 48% of the students are in the age 18, 32% of the students are in the age 19 and 12% of the students are in the age of 20.(figure 5).26% of the students showed type 1 lip print,8% of the students showed type 1' lip print, 64% of the students showed type 2 lip print and 2% of the students showed type 5 lip print.(figure 6).

1. Type 2(branched reticular grooves) is most commonly seen.
2. According to the present study among 50 female students,30 samples had type 2, 10 samples had type 1, 5 samples had 1' and one sample had type 4.
3. No two lip prints matched each other thus establishing the uniqueness of lip prints.

**FIGURE 3:**



Figure 3 represents type 2 lip print

**FIGURE 4:**



Figure 4 represents type 1 lip print

**FIGURE 5:**

UNDER PEER REVIEW



Figure 5 represents type 5 lip print

**FIGURE 6:**



Figure 6 represents type 1'lip print

REVIEW

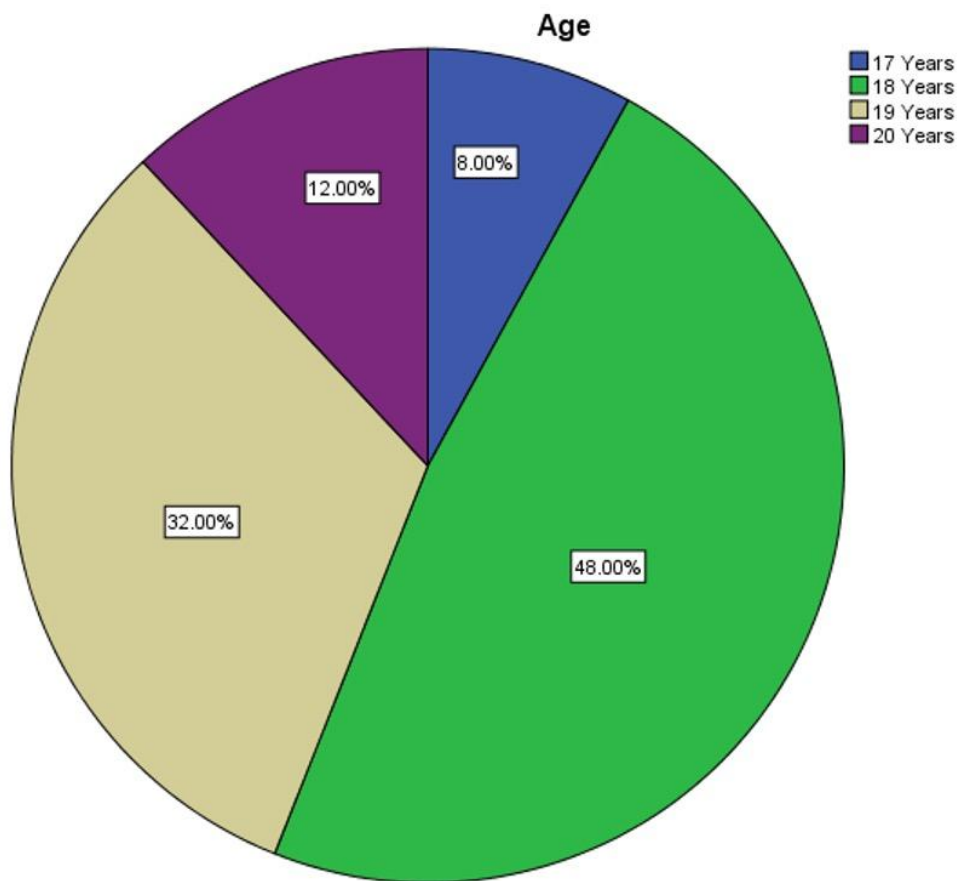


Figure 7: The above pie chart represents the percentage distribution of age among the study sample. Blue colour represents 17 years, green colour represents 18 years, yellow colour

represents 19 years and violet colour represents 20 years. 8% of the students are in the age 17, 48% of the students are in the age 18, 32% of the students are in the age 19 and 12% of the students are in the age of 20.

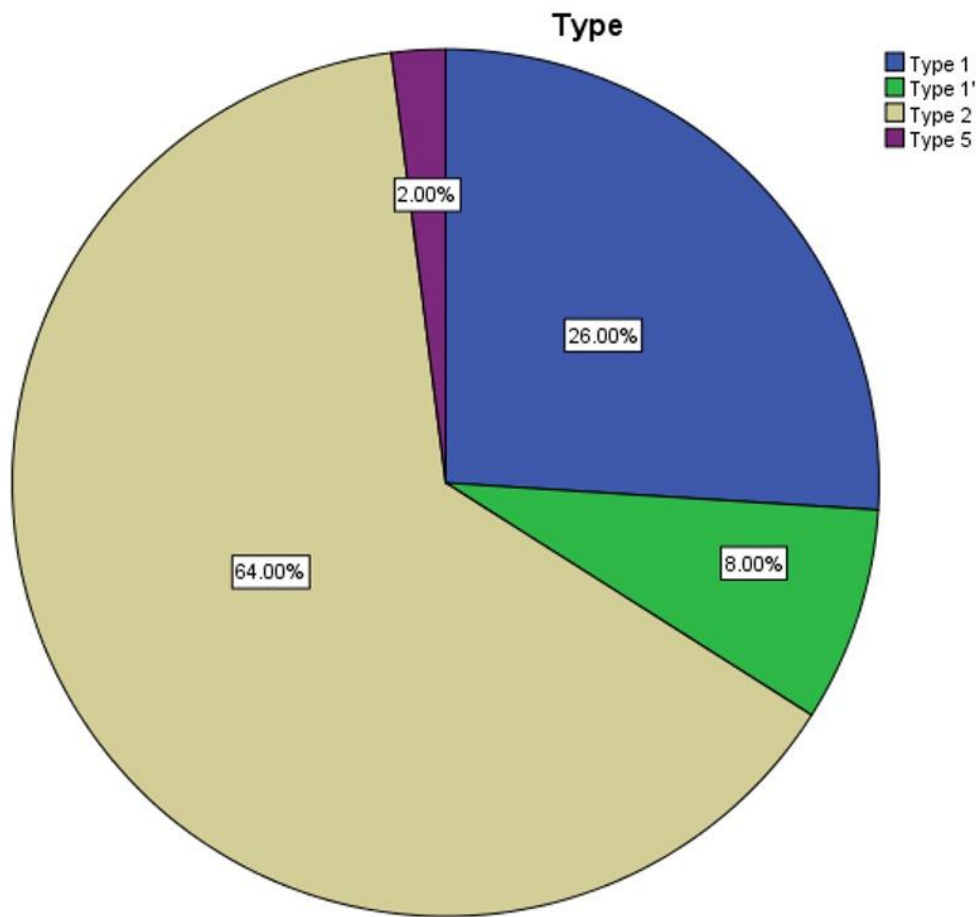


FIGURE 8: The above pie chart represents the percentage distribution of types of lip prints identified in the study sample. blue colour represents type 1, green colour represents type 1', yellow colour represents type 2 and violet colour represents type 5. 26% of the students

showed type 1 lip print,8% of the students showed type 1' lip print, 64% of the students showed type 2 lip print and 2% of the students showed type 5 lip print.

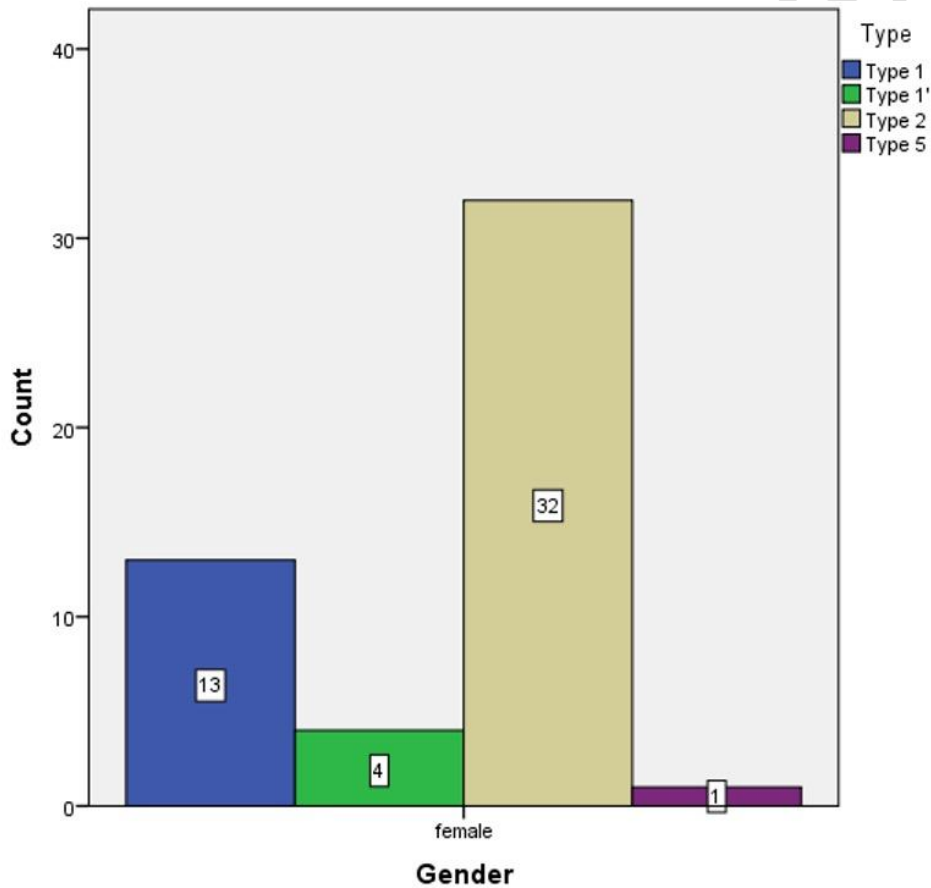


FIGURE 9: The above bar graph represents the association of lip prints between type 2 and type 1 in females which is showing more accurate prints than the type 5 and type 1'. Blue colour represents type, one green colour represents type one dash, beige colour represents type two and

violet colour represents type five. In this out of 50 samples majority of the samples showed type 2 lip print (branched y shaped grooves).

## **DISCUSSION:**

Lip prints are very useful in forensic investigation and personal identification. They are considered to be the most important forms of transfer evidence and are analogous to finger prints(26)(27).In the present study 50 females who are around the age group of 17-20 years were taken and their pattern of lip prints was studied.26% of the students showed type 1 lip print,8% of the students showed type 1' lip print, 64% of the students showed type 2 lip print and 2% of the students showed type 5 lip print. It is also found that no two lip prints matched each other.

Lip prints are usually left at crime scenes and can provide a direct link to the suspect. In recent years lipsticks have been developed that do not leave any visible trace after contact with surfaces such as glass, clothing, cutlery or cigarettes(4). These lip prints are characterised by their permanent nature and referred to as persistent lip prints. Although invisible lip prints can be determined using materials such as aluminium powder and magnetic powder(5)(28) the use of lipsticks is not indispensable for leaving lip prints. The edges of lips have sebaceous glands with sweat glands in between. Thus the secretion of oil and moisture from these enable development of latent fingerprints analogous to latent fingerprints(29)(30). In a previous study it is stated that type 1 and type 1' lip prints are dominant in females (31).lip morphology do not vary significantly between the genders but the pattern varies.Even though the lines and furrows are present both in the upper lip and the lower lip from one corner of the mouth to the other corner, only the middle portion of the lip is taken into account since this portion is visible in any traces. In this study we studied a particular pattern on the basis of numerical superiority of types of lines present that are vertical, intersected, branched or reticular. If more than one pattern predominates it is taken as undetermined(type 5). In the present study type 2 is found to be dominant in females which is in accordance with a similar study done by Neha bansal,et al in a study sample of 2500 females and 2500 males stated that Type I, I', II lip print pattern was most predominant in females.(32). It is found in the study that lip prints are unique to each individual and a similar study done by Amrita ,et al in a study sample of 200 medical students also stated the same.(33)

The limitations of the study is Lip prints usually recover from minor trauma but surgery and pathosis can alter the pattern of the grooves . As the sample size is less it does not represent the entire population. Future studies can be done in different age groups and comparing both the genders as lip prints can be used in gender determination. Sample size can be increased for more accurate results.

## **CONCLUSION:**

The present study is able to convey that type 2 lip print is predominant in females and lip prints are unique for an individual. Though the result obtained by the present study isn't convinced to be an infallible method nevertheless it does seem to go one step closer to the truth that lip prints hold potential promise as a supplementary tool alongside with other modes in forensic odontology. Research studies and knowledge regarding the use of lip prints as evidence in personal identification and criminal investigation in forensic dentistry are considered scanty, but exist as a methodology in forensic dentistry .Studying in depth and establishing further facts and truth in lip prints will certainly help as useful evidence in forensic dentistry

## **REFERENCES:**

1. Utsuno H, Kanoh T, Tadokoro O, Inoue K. Preliminary study of post mortem identification using lip prints. *Forensic Sci Int*. 2005 May 10;149(2-3):129–32.
2. Adamu L. Comparative Study of Fingerprints and Lip Prints. 2018.
3. Murgod S. Lip Prints and Inheritance of Cleft Lip and Cleft Palate [Internet]. *JOURNAL OF CLINICAL AND DIAGNOSTIC RESEARCH*. 2014. Available from: <http://dx.doi.org/10.7860/jcdr/2014/7865.4575>
4. Maheshwari TNU. Infallible concepts of lip prints [Internet]. Vol. 1, *International Journal of Forensic Odontology*. 2016. p. 25. Available from: <http://dx.doi.org/10.4103/2542-5013.194274>
5. Tsuchihashi Y. Studies on personal identification by means of lip prints [Internet]. Vol. 3, *Forensic Science*. 1974. p. 233–48. Available from: [http://dx.doi.org/10.1016/0300-9432\(74\)90034-x](http://dx.doi.org/10.1016/0300-9432(74)90034-x)
6. Wu F, Zhu J, Li G, Wang J, Veeraraghavan VP, Krishna Mohan S, et al. Biologically

- synthesized green gold nanoparticles from Siberian ginseng induce growth-inhibitory effect on melanoma cells (B16). *Artif Cells Nanomed Biotechnol.* 2019 Dec;47(1):3297–305.
7. Chen F, Tang Y, Sun Y, Veeraraghavan VP, Mohan SK, Cui C. 6-shogaol, a active constituents of ginger prevents UVB radiation mediated inflammation and oxidative stress through modulating Nrf2 signaling in human epidermal keratinocytes (HaCaT cells). *J Photochem Photobiol B.* 2019 Aug;197:111518.
  8. Li Z, Veeraraghavan VP, Mohan SK, Bolla SR, Lakshmanan H, Kumaran S, et al. Apoptotic induction and anti-metastatic activity of eugenol encapsulated chitosan nanopolymer on rat glioma C6 cells via alleviating the MMP signaling pathway [Internet]. Vol. 203, *Journal of Photochemistry and Photobiology B: Biology.* 2020. p. 111773. Available from: <http://dx.doi.org/10.1016/j.jphotobiol.2019.111773>
  9. Babu S, Jayaraman S. An update on  $\beta$ -sitosterol: A potential herbal nutraceutical for diabetic management. *Biomed Pharmacother.* 2020 Nov;131:110702.
  10. Malaikolundhan H, Mookkan G, Krishnamoorthi G, Matheswaran N, Alsawalha M, Veeraraghavan VP, et al. Anticarcinogenic effect of gold nanoparticles synthesized from *Albizia lebbek* on HCT-116 colon cancer cell lines. *Artif Cells Nanomed Biotechnol.* 2020 Dec;48(1):1206–13.
  11. Han X, Jiang X, Guo L, Wang Y, Veeraraghavan VP, Krishna Mohan S, et al. Anticarcinogenic potential of gold nanoparticles synthesized from *Trichosanthes kirilowii* in colon cancer cells through the induction of apoptotic pathway. *Artif Cells Nanomed Biotechnol.* 2019 Dec;47(1):3577–84.
  12. Gothai S, Muniandy K, Gnanaraj C, Ibrahim IAA, Shahzad N, Al-Ghamdi SS, et al. Pharmacological insights into antioxidants against colorectal cancer: A detailed review of the possible mechanisms. *Biomed Pharmacother.* 2018 Nov;107:1514–22.
  13. Veeraraghavan VP, Hussain S, Balakrishna JP, Dhawale L, Kullappan M, Ambrose JM, et al. A Comprehensive and Critical Review on Ethnopharmacological Importance of Desert Truffles: *Terfezia claveryi*, *Terfezia boudieri*, and *Tirmania nivea* [Internet]. *Food Reviews International.* 2021. p. 1–20. Available from: <http://dx.doi.org/10.1080/87559129.2021.1889581>
  14. Sathya S, Ragul V, Veeraraghavan VP, Singh L, Niyas Ahamed MI. An in vitro study on hexavalent chromium [Cr(VI)] remediation using iron oxide nanoparticles based beads. *Environmental Nanotechnology, Monitoring & Management.* 2020 Dec 1;14:100333.
  15. Yang Z, Pu M, Dong X, Ji F, Priya Veeraraghavan V, Yang H. Piperine loaded zinc oxide nanocomposite inhibits the PI3K/AKT/mTOR signaling pathway via attenuating the development of gastric carcinoma: In vitro and in vivo studies. *Arabian Journal of Chemistry.* 2020 May 1;13(5):5501–16.
  16. Rajendran P, Alzahrani AM, Rengarajan T, Veeraraghavan VP, Krishna Mohan S. Consumption of reused vegetable oil intensifies BRCA1 mutations. *Crit Rev Food Sci Nutr.*

2020 Oct 27;1–8.

17. Barma MD, Muthupandiyan I, Samuel SR, Amaechi BT. Inhibition of Streptococcus mutans, antioxidant property and cytotoxicity of novel nano-zinc oxide varnish. Arch Oral Biol. 2021 Jun;126:105132.
18. Samuel SR. Can 5-year-olds sensibly self-report the impact of developmental enamel defects on their quality of life? Int J Paediatr Dent. 2021 Mar;31(2):285–6.
19. Samuel SR, Kuduruthullah S, Khair AMB, Shayeb MA, Elkaseh A, Varma SR. Dental pain, parental SARS-CoV-2 fear and distress on quality of life of 2 to 6 year-old children during COVID-19. Int J Paediatr Dent. 2021 May;31(3):436–41.
20. Tang Y, Rajendran P, Veeraraghavan VP, Hussain S, Balakrishna JP, Chinnathambi A, et al. Osteogenic differentiation and mineralization potential of zinc oxide nanoparticles from Scutellaria baicalensis on human osteoblast-like MG-63 cells [Internet]. Vol. 119, Materials Science and Engineering: C. 2021. p. 111656. Available from: <http://dx.doi.org/10.1016/j.msec.2020.111656>
21. Yin Z, Yang Y, Guo T, Veeraraghavan VP, Wang X. Potential chemotherapeutic effect of betalain against human non-small cell lung cancer through PI3K/Akt/mTOR signaling pathway. Environ Toxicol. 2021 Jun;36(6):1011–20.
22. Veeraraghavan VP, Periadurai ND, Karunakaran T, Hussain S, Surapaneni KM, Jiao X. Green synthesis of silver nanoparticles from aqueous extract of Scutellaria barbata and coating on the cotton fabric for antimicrobial applications and wound healing activity in fibroblast cells (L929). Saudi J Biol Sci. 2021 Jul;28(7):3633–40.
23. Mickymaray S, Alfaiz FA, Paramasivam A, Veeraraghavan VP, Periadurai ND, Surapaneni KM, et al. Rhaponticin suppresses osteosarcoma through the inhibition of PI3K-Akt-mTOR pathway. Saudi J Biol Sci. 2021 Jul;28(7):3641–9.
24. Teja KV, Ramesh S. Is a filled lateral canal – A sign of superiority? [Internet]. Vol. 15, Journal of Dental Sciences. 2020. p. 562–3. Available from: <http://dx.doi.org/10.1016/j.jds.2020.02.009>
25. Theertha M, Sanju S, Priya VV, Jain P, Varma PK, Mony U. Innate lymphoid cells: Potent early mediators of the host immune response during sepsis. Cell Mol Immunol. 2020 Oct;17(10):1114–6.
26. Bai JKS, Prakash AR, Reddy AVS, Rajinikanth M, Sreenath S, Kumar Reddy KVK. Correlative study on lip prints, fingerprints, and mandibular intercanine distance for gender determination. J Forensic Dent Sci. 2018 Sep;10(3):143–50.
27. Identification of Latent Lip Prints in Forensics - Review [Internet]. Indian Journal of Forensic Medicine & Toxicology. 2020. Available from: <http://dx.doi.org/10.37506/ijfmt.v14i4.12372>

28. Castelló A, Alvarez-Seguí M, Verdú F. Luminous lip-prints as criminal evidence. *Forensic Sci Int.* 2005 Dec 20;155(2-3):185–7.
29. Ball J. The current status of lip prints and their use for identification. *J Forensic Odontostomatol.* 2002 Dec;20(2):43–6.
30. Eddy J. *Lipsology: The Art and Science of Reading Lip Prints.* 2014.
31. Krishnan RP, Thangavelu R, Rathnavelu V, Narasimhan M. Gender determination: Role of lip prints, finger prints and mandibular canine index. *Exp Ther Med.* 2016 Jun;11(6):2329–32.
32. M. M, T. K. A STUDY OF RELATIVE CORRELATION BETWEEN THE PATTERN OF FINGER PRINTS AND LIP PRINTS [Internet]. Vol. 3, *Journal of Evolution of Medical and Dental Sciences.* 2014. p. 12768–72. Available from: <http://dx.doi.org/10.14260/jemds/2014/3694>
33. Rastogi P, Parida A. Lip prints – an aid in identification [Internet]. Vol. 44, *Australian Journal of Forensic Sciences.* 2012. p. 109–16. Available from: <http://dx.doi.org/10.1080/00450618.2011.610819>