

Branches of a rotten tree- trending variants of covid-19 and their oral manifestations

ABSTRACT :

Coronavirus was first distinguished in the city of Wuhan, China, in late 2019 however the flare-up spread rapidly across the globe in the primary long stretches of 2020. It was announced a worldwide pandemic by the WHO on 11 March 2020. WHO's present approaches and defends are as yet viable against viral strains found since the episode started. The Delta variety of the Covid, which causes COVID-19, causes a greater number of diseases and spreads speedier than prior variations of the infection. The Delta variation is profoundly infectious, over 2x as infectious as past variations. On November 24, 2021, another variation of COVID-19, B.1.1.529, was accounted for to the planet Health Organization (WHO). On November 26, 2021, WHO named the B.1.1.529 Omicron and arranged it as a Variant of Concern (VOC). The Omicron variation probably will spread more effectively than the primary SARS-CoV-2 infection and the way effectively Omicron spreads contrasted with Delta stays obscure. Acute Corona viral infection, along with related treatment approaches, might cause negative oral health effects. The spectrum of COVID-19 symptoms on the oral cavity has been deemed of broad and current interest since the prevalence of clinical manifestations is unclear.⁽⁶⁾ As well as establishing general wellbeing and contamination control measures to forestall or decrease SARS-CoV-2 transmission, inoculation to forestall SARS-CoV-2 disease in networks all through the world is basic to forestalling this worldwide pandemic⁽¹⁾.

INTRODUCTION

The disorder caused by serious intense respiratory condition, Corona infection sickness (COVID-19), has devastatingly affected the global population, occurring in over 3.8 million fatalities all-inclusive and arising as the foremost major worldwide wellbeing calamity since the 1918 influenza pandemic.⁽¹⁾ Multiple original types of concern have created since the start of the SARS-CoV-2 pandemic, including Alpha(B.1.1.7)Beta(B.1.351); and Gamma (P.1) and Delta(B.1.617.2), which are connected with more noteworthy contagiousness and seriousness⁽¹⁾. While India looked to air the increase contained the pandemic's devastating impacts throughout February 2021, beginning in early April, both incidence and therefore the number of deaths that have happened has increased dramatically, which are linked to The Indian variations of the covid-19 virus (B.1.617.2), also referred to as the delta variant or UK variant, are being transmitted within the community⁽²⁾. Because of its capacity to evade resistance, the delta VoC's greater transmissibility was linked with, among other things, a superior, virulent freight longer period of infectiousness⁵, and increase incidence of reinfection, leading to the delta VoC quickly becoming the worldwide prevalent variation. a brand new covid-19 variation of apprehension omicron,⁽⁴⁾ was announced on November 25, 2021, roughly 23 months after the primarily recorded case of COVID-19 and after a worldwide anticipated 260 million cases and 52 million deaths⁽³⁾. On November 24, 2021, the WHO received the primary report of this variant from South Africa⁽⁵⁾. In South Africa, the epidemiological situation marked by three

different peak in reported cases, the foremost recent of which was dominated by the Delta type⁽⁵⁾. It's uncertain if Omicron is more contagious than other variations, like Delta. . COVID-19 has infected around 11,301,800 persons during the outbreak in December 2019. The spectrum of SARS-CoV2 symptoms on the rima oris has been deemed of wide and up to date attention since the prevalence of clinical manifestations is unclear. COVID-19 within the mouth can cause taste changes, ambiguous oral crustations, desquamative gingivitis, petechiae, and associated entity like candidiasis⁽⁶⁾. The goal of this review paper is to clarify the severity of those novel variations of concern and their oral symptoms very well.

EPIDEMIOLOGY : Since the primary instances of COVID-19 were accounted for in Wuhan, Hubei Province, China, in December 2019, and the World Health Organization announced COVID-19 an overall pandemic in March 2020, the profoundly infectious irresistible ailment has spread to 223 nations, coming about in north of 178 million cases and 3.8 million passings.⁽¹⁾ Disease and genuine infection can influence individuals, all things considered. Patients north of 60 years of age and those with basic clinical comorbidities (corpulence, cardiovascular sickness, persistent renal illness, diabetes, constant lung infection, smoking, malignant growth, strong organ or hematopoietic undeveloped cell relocate patients) are bound to secure serious COVID-19 contamination⁽¹⁾.

DELTA VARIANT: This virulent form was first discovered in India in October 2020, and since then, the rate of contagion and fatality has skyrocketed. A research using epidemiological modelling revealed that the delta variation had a transmission rate that is 1.1 to 1.4 times higher than the other variant circulating in South Asia's largest country (India).⁽²⁾ While the delta variation is causing an issue for the medical services business on many levels, one more change in its genome has brought about the development of the K417N "Delta Plus" variation (B.1.617.2.1 or AY.1), which is additionally from India (2)

OMICRON VARIANT: On November 11, 2021, the primary sequenced omicron case was accounted for in Botswana, and a couple of days after the fact, one more sequenced case was found in a traveler from South Africa in Hong Kong. Cases are on the ascent in South Africa, as per early epidemiological information, as are PCR tests that miss the S-quality objective.⁽⁷⁾ Although omicron is thought to be profoundly contagious, regardless of whether it is more so than delta is obscure. In any case, fundamental information shows that it is quickly growing, in spite of nonstop delta-variation transmission and significant normal protection from the delta variety.

PATHOGENESIS:

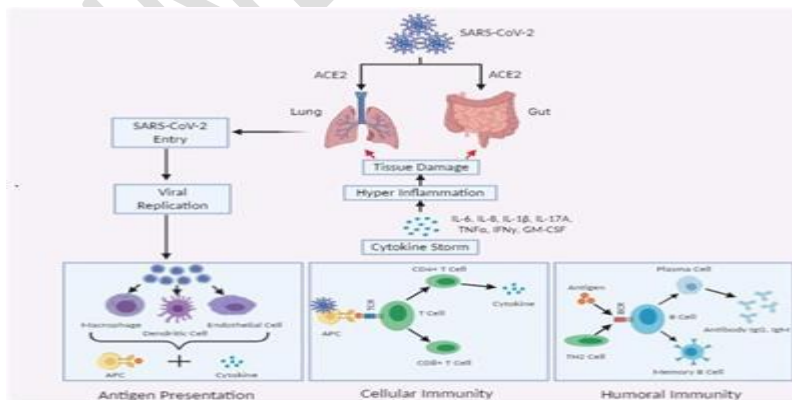


Fig. 1. Pathogenesis of SARS-COV2

DELTA VARIANT :

- SIGNS AND SYMPTOMS –

- Sore throat
- Headache
- Fever
- Runny nose and cough

also loss of smell are more uncommon with the Delta variation contrasted with the first Covid strain

.Other symptoms of COVID-19 may include:

- Dyspnoea
- Chills
- Muscle spasm
- Changes in or loss of sense of taste
- [Fatigue](#)
- [Diarrhea](#)
- [Nausea](#)
- [Vomiting](#)
- Loss of appetite
- Congestion
- [Abdominal pain](#)
- Feeling unwell (malaise)

.OMICRON VARIANT:

SIGNS AND SYMPTOMS: The symptoms of infection include :

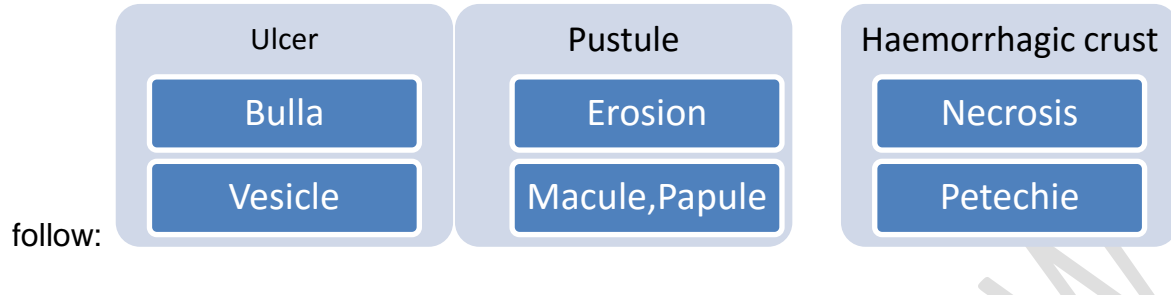
Weakness
, headache,
pain in the throat.

, tiredness

low grade fever and

Fig. 2. Oral manifestation

ORAL MANIFESTATIONS: Oral manifestations of covid 19 and its variants are as



Aphthous stomatitis, herpetiform lesions, candidiasis, vasculitis, Kawasaki-like, EM-like, mucositis, drug eruption, necrotizing periodontitis, angina bullosalike, angular cheilitis, atypical Sweet syndrome, and Melkersson-Rosenthal syndrome were all suggested diagnoses for the lesions (15).

Aphthous-like lesions- On both keratinized and nonkeratinized mucosae, aphthous-like lesions developed as many shallow ulcers with erythematous halos and yellow white pseudo membranes. Mouth lesions developed immediately with systemic symptoms in one patient, whereas oral lesions emerged between 2 and 10 days in other individuals. Younger individuals with moderate contagion had aphthous-like lesions without necrosis, but older patients with immunosuppression and severe infectivity had this entity with necrosis and hemorrhagic crusts more commonly.⁽¹⁵⁾

Herpetiform/zosteriform lesions - numerous sore, one-sided, encircling yellowish gray ulcers with a reddish border appeared on either side of keratinized and nonkeratinized mucosa in herpetiform eruptions. Systemic symptoms directed by, or followed the appearance of those lesions.⁽¹⁵⁾

Ulcer and erosion: On the tongue, surface, and labial mucosa, ulcerative or erosive lesions showed as throbbing crustations with uneven boundaries. Lesions developed 4 to 7 days after the beginning of systemic symptoms, while in one case, lesions emerged 3 days before the beginning of systemic symptoms and recovered 5 to 21 days later.⁽¹⁵⁾

White/red plaques: Patients with affirmed or suspected COVID-19 have announced white and red spots or plaques on the dorsum of their tongue, gingiva, and sense of taste. Candidiasis because of long haul anti-infection prescription, deteriorating of general wellbeing, and an absence of oral cleanliness are on the whole potential reasons for white or red patches or plaques.⁽¹⁵⁾

EM-like lesions: In patients with cutaneous objective injuries in the furthest points, EM-like sores happened as rashes, desquamative gum disease, erythematous macules, disintegrations, and serious cheilitis with hemorrhagic crusts. Injuries happened 7–24 days following the start of foundational manifestations and vanished in 2–4 weeks.⁽¹⁵⁾

Melkerson-Rosenthal syndrome

A 51-year-old woman gave discomfort, one-sided lip edema, fissured tongue, and right facial loss of motion, as indicated by the report. She had Melkersson-Rosenthal condition four years earlier, which had precipitously settled with no return.⁽¹⁵⁾

Kawasaki-like disease In COVID19 patients with Kawasaki-like ailment (KawaCOVID), oral injuries like cheilitis, glossitis, and erythematous and enlarged tongue (red strawberry tongue) created. Rather than direct infection impacts on the skin and oral mucosa, the long inertness between the beginning of fundamental side effects (respiratory or gastrointestinal) and the beginning of oral or cutaneous indications could be because of a postponed hyperactivation reaction of the framework and optional arrival of intense fiery cytokines.⁽¹⁵⁾

Petechiae

Petechiae have been seen on the lower lip, sense of taste, and oropharynx mucosa in a couple of examinations. Patients with petechiae had a more limited inactivity time than those with both petechiae and retinal sores. Petechiae have been connected to thrombocytopenia brought about by COVID19 disease or the suggested medication.⁽¹⁵⁾

Nonspecific lesions (mucositis) A few examinations have shown erythematousviolaceous macules, patches, papules, and plaques on the tongue, lip mucosa, surface, and oropharynx. Mucositis in COVID19 patients can be brought about by thrombotic vasculopathy, vasculitis, or excessive touchiness to COVID19.⁽¹⁵⁾

Postinflammatory pigmentation

One instance of pigmentation inside the associated and interpapillary gingiva in a 40-year-elderly person was accounted for. Expanded degrees of fiery cytokines, (for example, interleukin 1 [IL1] and cancer putrefaction factor [TNF]) and arachidonic corrosive metabolites (prostaglandins) brought about by the creation of substantial cell factor (SCF) and fundamental fibroblast protein (bFGF) by basal layer keratinocytes cause postinflammatory pigmentations⁽¹⁵⁾

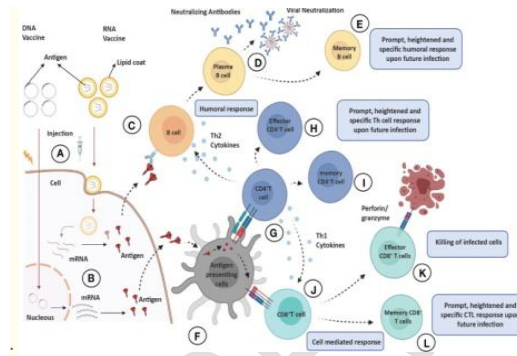


Fig.3. VACCINE POTENTIAL

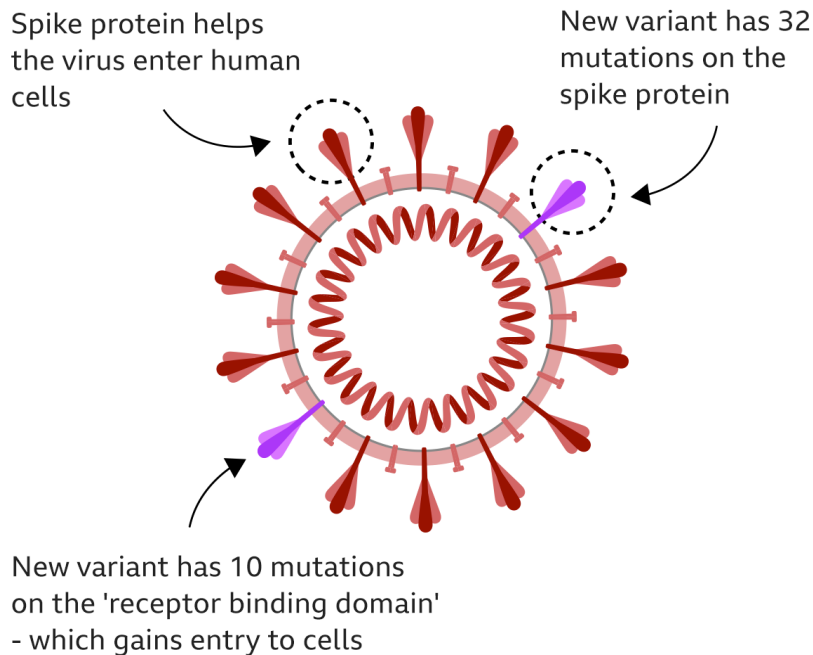
COVID-19 might benefit greatly from the information gained from efforts to create vaccines for SARS and MERS. This information aids in the creation of COVID-19 vaccines that are both safe and efficacious. There are three types of antiviral vaccine development strategies: i) 1st-generation vaccines, such as protein subunit and vector-based vaccines; and ii) 2nd-generation vaccines, such as nucleic acid and nanomaterial-based vaccines⁽¹⁰⁾.

Delta variant: - On account of most current inoculations, the delta variant has recently been shown to be restricting to immunization produced immunity⁽²⁾. When contrasted with the alpha form, the delta rendition diminished the adequacy of antibodies from Oxford-AstraZeneca and Pfizer-BioNTech by around

6.2 and 2.9 occasions, separately ⁽⁸⁾.

Omicron variant

More mutations may make it spread faster



Source: South Africa Centre for Epidemic Response and Innovation

BBC

Early indications suggest that existing immunizations may not be as effective against Omicron.

South African scientists have seen an increase in the number of patients who have caught Covid numerous times.

This indicates that the variation may be better at avoiding some of the protection provided by immunizations or previous infection.

However, there is no conclusive evidence that Omicron is more contagious, and even if it is, there is no indication that it causes more serious disease. Clinical examinations have found diminishing viability for specific inoculations in transmission circumstances where the beta variety is unmistakable, yet inconsistent discoveries on whether COVID-19 antibodies have consistently saved taking off effectiveness for every one of the four variations going before omicron Previous modifications have brought down immunization adequacy; for instance, in the United Kingdom, the D614G type of the ChAdOx1 immunization was 70% proficient in forestalling contaminations in the facility, yet only 10% for the beta form.

IS THEOMICRON VARIANT LESS DANGEROUS THAN DELTA?

The coronavirus Omicron strain is quickly spreading in South Africa and gaining momentum in various regions all over the globe. However, preliminary evidence from South Africa suggests that this variation may induce less severe COVID-19 instances than the Delta version.

- Experts believe the Omicron variety appears to produce symptoms that are comparable to those of other coronavirus variants, including fever, cough, and shortness of breath. Muscle pains are also familiar.
- However, not everyone who has been diagnosed with Omicron has had a substantial loss of taste and smell.
- So yet, Omicron symptoms appear to be modest, according to experts.
- However, scientists warn that this might aid viral transmission by preventing individuals from being tested and thereby inadvertently transmitting the infection.

CONCLUSION:

The coming catastrophic situation, which is being driven by a combined onslaught by delta and omicron variants, is worsening the COVID-19 pandemic in South-Asian countries, convincing international public health experts that it is a high priority. (2)The development of COVID-19 treatments and vaccines is still in its early stages; nonetheless, tremendous progress has been made in the scientific domain, ranging from complete genome sequencing of Corona virus to the start of clinical trials using COVID-19 vaccinations. Despite massive international efforts to limit this infection, the virus has spread to pandemic proportions. Outbreaks of coronaviruses can cause not only significant human deaths, but also worldwide economic disruption, interrupting industrial supply chains and lowering market demand. As a result, collaboration among numerous institutions, researchers, governments, and pharmaceutical firms is unavoidable if the present COVID-19 epidemic and future outbreaks are to be avoided (13). Because of the pandemic's worldwide scope, multiple international regulatory and scientific authorities have collaborated to develop and exchange important safety and effectiveness data for innovative vaccines⁽¹⁴⁾. The counteraction and treatment of this profoundly infectious respiratory infection need a multidisciplinary and interprofessional procedure including doctors from numerous specialities, attendants, drug specialists, general wellbeing trained professionals, and government authorities.⁽¹⁾

References:

- 1.Aleem A, Akbar Samad AB, Slenker AK. Emerging Variants of SARS-CoV-2 And Novel Therapeutics Against Coronavirus (COVID-19). 2021 Jul 18. In: StatPearls [Internet]. Treasure Island (FL): StatPearls Publishing; 2021 Jan-. PMID: 34033342.
- 2.Bari MS, Hossain MJ, Akhter S, Emran TB. Delta variant and black fungal invasion: A bidirectional assault might worsen the massive second/third stream of COVID-19 outbreak in South-Asia. Ethics Med Public Health. 2021 Dec;19:100722. doi: 10.1016/j.jemep.2021.100722. Epub 2021 Sep 4. PMID: 34514076; PMCID: PMC8416648.

3.WHO coronavirus (COVID-19) dashboard.

<https://covid19.who.int/>

Date: 2021

Date accessed: November 29, 2021

4.Update on omicron. Nov 28, 2021.

<https://www.who.int/news/item/28-11-2021-update-on-omicron>

Date accessed: November 30, 2021

5.Classification of Omicron (B.1.1.529): SARS-CoV-2 Variant of Concern

6.Amorim Dos Santos J, Normando AGC, Carvalho da Silva RL, Acevedo AC, De Luca Canto G, Sugaya N, Santos-Silva AR, Guerra ENS. Oral Manifestations in Patients with COVID-19: A Living Systematic Review. *J Dent Res*. 2021 Feb;100(2):141-154. doi: 10.1177/0022034520957289. Epub 2020 Sep 11. PMID: 32914677.

7.GISAID

Tracking of variants.

<https://www.gisaid.org/hcov19-variants/>

Date: 2021

Date accessed: November 30, 2021

8. Mlcochova P., Kemp S., Dhar M.S., Papa G., Meng B., Mishra S., et al. SARS-CoV-2 B. 1.617. 2 Delta variant emergence and vaccine breakthrough. *Research Square*. 2021 doi: 10.21203/rs.3.rs-637724/v1. [[CrossRef](#)] [[Google Scholar](#)]

9.Khan WH, Hashmi Z, Goel A, Ahmad R, Gupta K, Khan N, Alam I, Ahmed F, Ansari MA. COVID-19 Pandemic and Vaccines Update on Challenges and Resolutions. *Front Cell Infect Microbiol*. 2021 Sep 10;11:690621. doi: 10.3389/fcimb.2021.690621. PMID: 34568087; PMCID: PMC8461057.

10.Soleimanpour S, Yaghoubi A. COVID-19 vaccine: where are we now and where should we go? *Expert Rev Vaccines*. 2021 Jan;20(1):23-44. doi: 10.1080/14760584.2021.1875824. Epub 2021 Feb 17. PMID: 33435774; PMCID: PMC7898300.

11.Abdool Karim SS, de Oliveira T. New SARS-CoV-2 variants: clinical, public health, and vaccine implications. *N Engl J Med* 2021; 384: 1866–68

12.<https://www.healthline.com/health-news/omicron-symptoms-how-they-compare-with-other-coronavirus-variants>

13.Ahn DG, Shin HJ, Kim MH, Lee S, Kim HS, Myoung J, Kim BT, Kim SJ. Current Status of Epidemiology, Diagnosis, Therapeutics, and Vaccines for Novel Coronavirus Disease 2019 (COVID-19). *J Microbiol Biotechnol*. 2020 Mar 28;30(3):313-324. doi: 10.4014/jmb.2003.03011. PMID: 32238757.

14.Sultana J, Mazzaglia G, Luxi N, Cancellieri A, Capuano A, Ferrajolo C, de Waure C, Ferlazzo G, Trifirò G. Potential effects of vaccinations on the prevention of COVID-19: rationale, clinical evidence, risks, and public health considerations. *Expert Rev Vaccines*. 2020 Oct;19(10):919-936. doi: 10.1080/14760584.2020.1825951. Epub 2020 Oct 6. PMID: 32940090.

15.Iranmanesh B, Khalili M, Amiri R, Zartab H, Aflatoonian M. Oral manifestations of COVID-19 disease: A review article. *Dermatol Ther*. 2021 Jan;34(1):e14578. doi: 10.1111/dth.14578. Epub 2020 Dec 13. PMID: 33236823; PMCID: PMC7744903.

16. dos Santos JA, Normando AG, da Silva RL, et al. Oral mucosal lesions in a COVID-19 patient: new signs or secondary manifestations? *Int J Infect Dis.* 2020;9.

.17. Putra BE, Adiarto S, Dewayanti SR, Juzar DA. Viral Exanthem with “pin and needles sensation” on extremities of COVID-19 patient. *Int J Infect Dis.* 2020;96:355-358.

18. Brandão TB, Gueiros LA, Melo TS, et al. Oral lesions in patients with SARS-CoV-2 infection: could the oral cavity be a target organ? *Oral Surg Oral Med Oral Pathol Oral Radiol.* 2020.

UNDER PEER REVIEW