

### **Ocular Trauma in Pediatric Population**

#### **Abstract**

Pediatric ocular trauma is main challenge for ophthalmologists. It is most important cause of monocular blindness. Thus, it is a main problem in public health management. This study is aimed to determine the clinical characteristics and visual consequences of ocular trauma. The ocular trauma with further complications can result in blindness. An immediate evaluation of the potential damage may be impossible because of vitreous hemorrhage or may be ill-advised because of hyphema or damage to other ocular or orbital structures. Books like Comprehensive Ophthalmology by Dr. A K Khurana and various articles, WHO (World Health Organization) website, etcetera were referred for this review article. The trauma in pediatric age groups are more prevalent than that in adult age groups. Also, male gender is more prone to such injuries than that of females. This study concludes the fact that trauma to eyes is main cause of ocular morbidity which can be avoided by simple measures. First aid and early treatment can cause significant decrease in loss of vision due to ocular trauma. Thus, a little awareness in parents and guardians can help in decreasing the vision loss and blindness in pediatric population. Eye injury if occurred in closed eye, causes contusion or lamellar laceration and if that happens in an open eye, then it can lead to rupture, perforation or penetrating injury to the eyeball. Trauma to eyes is main cause of ocular morbidity which can be avoided by simple measures. First aid and early treatment can cause significant decrease in loss of vision due to ocular trauma. Thus, a little awareness in parents and guardians can help in decreasing the vision loss and blindness in pediatric population.

**Keywords :** Ocular trauma, pediatric, monocular blindness, consequences, trauma, accident, ocular complications.

#### **Introduction**

The eyeball is composed of a dense, elastic supporting membrane. The anterior most part of membrane is transparent and is termed as cornea. The remaining part is opaque and is termed as makichan@jichi.ac.jp

Shinji Makino

Department of Ophthalmology, Jichi Medical University, 3311-1 Yakushiji, Tochigi, Shimotsuke 329-0498, Japan

A Case of Extrusion of a Solid Silicone Tire Migrating  
through the Superior Rectus Muscle with *Aeromonas hydrophila*  
Infection following a Scleral Buckling Procedure

Case Reports in Ophthalmological Medicine

Volume 2012, Article ID 167164, 3 pages

drlws@163.net

Wensheng Li

Eye Hospital, Wenzhou Medical College, 270 Xueyuan Road, Zhejiang, Wenzhou 325027,  
China

Combined Anterior Sclera Staphylectomy and Vitrectomy with  
Anterior Sclera Staphyloma and Vitreous Hemorrhage Occurring  
38 Years after Cataract Surgery

Case Reports in Ophthalmological Medicine

Volume 2011, Article ID 340859, 3 pages

chowers@hadassah.org.il

Itay Chowers

Department of Ophthalmology, Hebrew University-Hadassah Schools of Medicine and  
Dental Medicine, P.O. Box 12000,

Jerusalem 91120, Israel

Scleral Buckle Extrusion Associated with Phthisis

Case Reports in Ophthalmological Medicine

Volume 2011, Article ID 942946, 2 pages. The foremost part of sclera is covered by  
conjunctiva which is reflected from its surface to lids. The midpoint on extreme convexities  
of the anterior and posterior curvature of the globe of eye are termed as anterior pole and  
posterior pole respectively.

The eye is protected from direct injury by the eyelids, eyelashes and the projecting margins  
of the orbit{1}. Even so, the eye can be injured by variety of agents such as chemicals, heat,  
different kind of radiations and mechanical trauma. Children are more prone to these kind of  
injuries because of their immature functioning. The midpoint on extreme convexities of the  
anterior and posterior curvature of the globe of eye are termed as anterior pole and posterior  
pole respectively. Types of eye injury includes chemical injuries, mechanical injuries,  
contusion injury, penetrating injury and penetrating injury with retention of foreign bodies.  
Eye injury if occurred in closed eye, causes contusion or lamellar laceration and if that  
happens in an open eye, then it can lead to rupture, perforation or penetrating injury to the  
eyeball. Various studies have shown the complications of these types of injuries but still this  
is not a public health issue till now. Various studies have shown the complications of these  
types of injuries but still this is not a public health issue till now. This might be due to the fact  
that trauma is not considered as a public health problem. The injury can be prone to infection

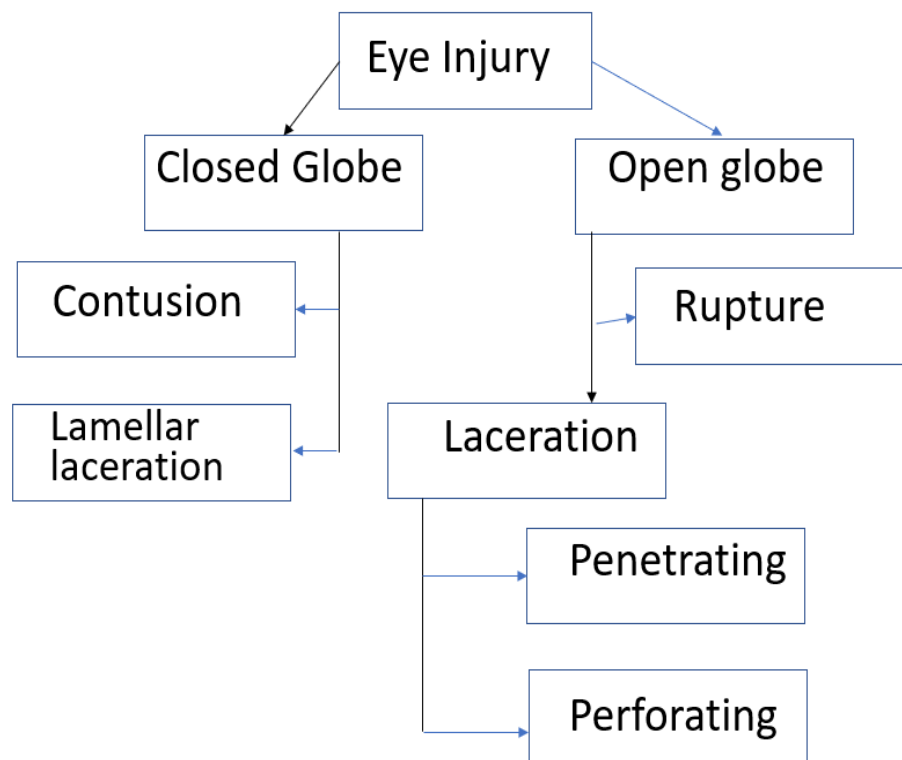
and if associated with retention of foreign bodies, the chances of infection increases more than that of penetrating injury. Eye injury if occurred in closed eye, causes contusion or lamellar laceration and if that happens in an open eye, then it can lead to rupture, perforation or penetrating injury to the eyeball. Trauma to eyes is main cause of ocular morbidity which can be avoided by simple measures. First aid and early treatment can cause significant decrease in loss of vision due to ocular trauma. Thus, a little awareness in parents and guardians can help in decreasing the vision loss and blindness in pediatric population.

### **Method**

We conducted a comprehensive literature search on the PubMed and Scielo databases to identify studies that showed the ocular trauma is important cause of visual loss . For identification we used the terms ‘ocular injuries’, ‘pediatric population’, and ‘eye injury’. We limited our search to the English language articles.

### **Pathophysiology**

The eye is protected from direct injury by the eyelids, eyelashes and the projecting margins of the orbit. Even so, the eye can be injured by variety of agents such as chemicals, heat, different kind of radiations and mechanical trauma. Children are more prone to these kind of injuries because of their immature functioning. The midpoint on extreme convexities of the anterior and posterior curvature of the globe of eye are termed as anterior pole and posterior pole respectively. Types of eye injury includes chemical injuries, mechanical injuries, contusion injury, penetrating injury and penetrating injury with retention of foreign bodies. Eye injury if occurred in closed eye, causes contusion or lamellar laceration and if that happens in an open eye, then it can lead to rupture, perforation or penetrating injury to the eyeball. Eye injury if occurred in closed eye, causes contusion or lamellar laceration and if that happens in an open eye, then it can lead to rupture, perforation or penetrating injury to the eyeball{2}. Trauma to eyes is main cause of ocular morbidity which can be avoided by simple measures. First aid and early treatment can cause significant decrease in loss of vision due to ocular trauma. Thus, a little awareness in parents and guardians can help in decreasing the vision loss and blindness in pediatric population.



**Fig. 1. Types of eye injury**

**Clinical features**

**1. Chemical Injuries**

- Intense conjunctivitis
- Chemosis
- Circumferential limbal ischemia

**2. Mechanical Injuries**

- Immense pain.
- Irritation.
- Ulceration of conjunctival sac.
- Hypopyon{3}.

**3. Contusion**

- Abrasion of cornea.
- Opacities of cornea.
- Erosion of cornea.
- Rupture of globe.
- Iridocyclitis.
- Mydriasis.
- Hyphaema.
- Cataractous changes in lens.
- Dislocation of lens.
- Vitreous haemorrhage.

- Berlin edema.
  - Macular degeneration.
  - Haemorrhage of optic nerve sheath.
  - Traumatic Glaucoma.
4. Penetrating injuries
- Laceration of cornea.
  - Cataractous changes in lens.
  - Iridocyclitis.
  - Traumatic Glaucoma.

### **Diagnosis of an intraocular foreign body**

The diagnosis of an intraocular foreign body is extremely important, particularly as the patient is often unaware that a particle has entered the eye. In all suspicious cases, particularly those with a history of having used a hammer and chisel, a careful search must be made for a wound of entry, which may be very minute and difficult to find. If the particle has passed through the cornea, however, the most minute scar can always be seen on careful examination with the slit-lamp, but its detection in the sclera may be much more difficult or sometimes even impossible. Eye injury if occurred in closed eye, causes contusion or lamellar laceration and if that happens in an open eye, then it can lead to rupture, perforation or penetrating injury to the eyeball. Trauma to eyes is main cause of ocular morbidity which can be avoided by simple measures. First aid and early treatment can cause significant decrease in loss of vision due to ocular trauma. Thus, a little awareness in parents and guardians can help in decreasing the vision loss and blindness in pediatric population. The anterior segment of the eye must be thoroughly explored with the slit-lamp and the angle of the anterior chamber with the gonioscope. A hole in the iris or an opaque track through the lens is pathognomonic. These tracks, together with the position of the wound of entrance, are often valuable clues in localizing the foreign body. If the media are clear, the entire fundus must be similarly searched under full mydriasis. Radiography is indispensable for the discovered location of foreign bodies, which are radio-opaque. Caldwell and lateral views are commonly employed. Fortunately, these particles are usually metallic and many-although by no means all-can thus be demonstrated. Many methods of localization are available. One of the most useful methods involves the suturing of a metal ring at the limbus or the use of a contact lens which contains a radioactive ring, and taking X-ray photographs in the anteroposterior and lateral axes. The foreign body can then be located in terms of the meridian and the number of millimetres behind the limbus or corneal apex. A second method utilized is the computerized axial tomography (CAT) scan. The thinnest slices are used to localize a small foreign body with great accuracy. Suturing of a metal ring at the limbus or the use of a contact lens which contains a radioactive ring, and taking X-ray photographs in the anteroposterior and lateral axes. The foreign body can then be located in terms of the meridian and the number of millimetres behind the limbus or corneal apex.

### **Treatment**

1. *Chemical injuries*

Deleterious material should be removed and immediate irrigation should be done with normal saline. Corticosteroids reduces inflammation. Antibiotic ointment or drops should be used. Ascorbic acid and tetracyclins enhance collagen formation. Limbal cell transplant can be done.

2. *Mechanical injuries*

The mechanical injuries with foreign bodies should be cleaned immediately. Needs a follow up after the removal of foreign body. Mechanical injuries are more prone to infection and thus this trauma should be treated with more care as it can cause vision loss and other complications. Organic matter should be removed properly as more prone to infections.

### **Prevention**

- Wear protective eyewear during risky activities.
- Wear goggles when exposed to chemicals.
- Supervise child's use of tools.
- Eliminate hazards that may cause falls.
- Avoid certain children's toys.
- Don't allow children to use laser pointers.
- Wear protective eyewear during sports.
- Keep small children safe around dogs.
- Forgo backyard fireworks.
- Use caution when opening a Champagne bottle.

### **How to prevent further extent of injury**

- Don't touch, rub or apply pressure to the attention.
- Don't attempt to remove an object that appears stuck on the surface of the attention or an object that appears to possess penetrated the attention.
- Don't apply ointment or medication to the attention.
- Flush out any chemicals the attention has been exposed to with many clean water.
- Gently place a shield or gauze patch over the attention until you'll get medical attention.

### **Complications**

- Sympathetic ophthalmitis  
It is serious inflammation around eye after injury to the other. Almost always results due to penetrating injury{6}. Wounds involving the ciliary body and including its incarceration have been considered dangerous. The incarceration of iris and lens capsule also are more likely to line up sympathetic ophthalmitis than others. Sympathetic ophthalmitis very rarely occurs if actual suppuration has taken place in the exciting eye. It also can occur rarely following elective surgery for cataract or glaucoma where iris tissue has been left incarcerated within the wound. Sympathetic ophthalmia has also been reported after proton beam irradiation, Nd:YAG cyclophotocoagulation and cyclocryotherapy Children are particularly susceptible, but it occurs at any age. it always begins 4-8 weeks after the injury to the primary eye (the exciting eye) has taken place, rarely earlier{7}. The onset has been reported to occur as early as 9 days after the accident and should be delayed for several months or maybe years. Aetiology The aetiology of the condition is unknown but is considered to be an autoimmune, T cell-mediated disease. Uveal pigment can act as an allergen

and people who suffer from sympathetic diseases show a skin sensitivity to it. virus infection could also be the initiating factor and act by modifying uveal proteins to the extent that they become unusually antigenic or, by damaging the cells directly, uncover intracellular previously 'sequestered' antigens{8}. Pathologically, the microscopic features in both the exciting and therefore the sympathizing eyes are an equivalent. In the earliest stages, examination shows nodular aggregations of lymphocytes and plasma cells scattered throughout the uveal tract. The pigment epithelium of the iris and ciliary body proliferates to make nodular aggregations (Dalen-Fuchs nodules) and therefore the tissues become invaded by lymphocytes and epithelioid cells. The retina is additionally heavily infiltrated, especially within the neighbourhood of the vessels. within the later stages the infiltrate becomes diffuse and giant cells appear; actually, the condition is scarcely distinguishable from tuberculosis of the uveal tract, although caseation isn't present{9}. These are merely the signs of reaction to a comparatively mild sort of irritation Clinical features. There is always iridocyclitis within the exciting eye. Usually it's a plastic iridocyclitis which has been set up by injury and has not subsided within the course of 3 or 4 weeks rather than quietening down, the ciliary injection remains, there's lacrimation and therefore the eye is tender. Special attention should be directed to the presence or absence of keratic precipitates on theophthalmitis, the exciting eye may have passed into a quiescent state. The exciting eye, while showing evident traces of old iridocyclitis, should possess useful vision. In other cases the attention may have shrunk completely. The onset of sympathetic ophthalmitis within the second eye in such cases is then ushered in by return of irritation (ciliary injection, tenderness, etc.) in the shrunken globe. In sympathetic ophthalmitis, the plastic iridocyclitis differs clinically in no respect from this type of iridocyclitis thanks to other causes. In rare cases it manifests itself as a neuroretinitis or choroiditis. Prodromal symptoms are sensitivity to light and transient indistinctness of near objects thanks to weakness of accommodation. The prodromal symptoms may occur in intermittent attacks, cover a substantial period of your time. In other cases, the patient first seeks advice for photophobia and lacrimation, or defective vision within the uninjured eye (sympathetic irritation). In cases which are prone to develop this condition, the primary sign could also be the presence of keratic precipitates on the rear of the cornea or the presence of retrolenticular flare and cells, which are noticed at this early stage because they need been anticipated. On examination at this stage, there could also be lacrima- tion, slight ciliary injection, tenderness of the eyeball, as shown by the patient shrinking from an effort a examination, precipitates on the rear of the cornea and vitreous opacities; occasionally there's some oedema of the blind spot. When fully developed, all the signs and symptoms of granulomatous uveitis are present, varying in degree according to the severity of the case. The prognosis as to vision is usually doubtful, but if there's extensive deposition of plastic exudates within the pupillary area it becomes extremely grave. Cases showing little exuda- tion but a deep anterior chamber and keratic precipi- tates have a more favourable prognosis, but they'll at any moment become the severe plastic type{10}. There is usually vitritis, multiple yellow-white lesions within the peripheral fundus, Dalen-Fuchs nodules and papillitis. Sympathetic ophthalmitis sometimes takes 2 or more years to run its course. Treatment The treatment of sympathetic ophthalmitis demands great judgement In the first place, it's prophylactic. In every case of penetrating injury, with or without the retention of a foreign body, prophylactic and long-term treatment, including the topical and systemic administration of steroids, could also be adopted for a time. If the attention quiets down quickly it's unlikely to line up sympathetic inflam- mation. The chief

causes which prolong entanglement of the iris or membrane or lens in the wound. Every effort must therefore be made to obviate this. It must be remembered that children are more vulnerable to the disease than adults. Sympathetic unless it's already commenced at the time of operation. It is even harder to make a decision the course to adopt in those cases during which sympathetic ophthalmitis has already supervened. If the case is seen early, shortly after the onset of inflammation within the sympathizing eye, and if the injured or exciting eye has no useful vision, this useless eye should be excised directly as this definitely has a good effect upon the method within the sympathizing eye if performed early. At a later stage, there's no evidence to point out that it exerts any influence. The treatment of sympathetic iridocyclitis is that of iridocyclitis generally with the proviso that steroid preparations have a more dramatic effect than in most other ocular inflammations. At the earliest suggestion of inflammation, steroids should be given systemically in large doses-intravenous methylprednisolone 1 g followed by 100 mg of prednisone orally tapered off slowly{11}. This should be reinforced by the topical use of dexamethasone 0.1% drops and topical cycloplegics. In altogether cases, 15-20 mg of prednisone should be continued for several months lest relapses follow its cessation, and therefore the eye should be watched over a period of years. Daily doses of oral steroids are employed initially but later it should be possible to vary to alternate day steroid therapy. The use of steroids has completely altered the prognosis of this disease if such treatment is commenced early{12}. If, however, the uvea is heavily infiltrated, the outlook for vision is far less hopeful, the inflammation has taken a firm hold and therefore the less hopeful. Steroid-resistant cases or those with severe corticosteroid-related side-effects require immunosuppressive therapy{13-19}. Oral cyclosporin A specifically severe cases of sympathetic ophthalmitis T cell-mediated immuno-inflammation.

- Visual loss
- Monocular blindness
- Cataract
- Glaucoma
- Conjunctivitis
- Macular degeneration
- Commotion retinae
- Rupture of choroid
- Proliferative vitreoretinopathy{2}

### **Conclusion**

Trauma to eyes is main cause of ocular morbidity which can be avoided by simple measures. First aid and early treatment can cause significant decrease in loss of vision due to ocular trauma.

### **REFERENCES:**

- 1) Giovanazzo VJ. The ocular sequelae of blunt trauma. *Advances in ophthalmic plastic and reconstructive surgery.* 1987 Jan 1;6:107-14.
- 2) Waters T, Vollmer L, Sowka J. Proliferative vitreoretinopathy as a late complication of blunt ocular trauma. *Optometry-Journal of the American Optometric Association.* 2008 Apr 1;79(4):197-202.

- 3) Claes C, Zivojnovic R. Vitrectomy in ocular trauma. *Bulletin de la Société belge d'ophtalmologie*. 1995;258:169-88.
- 4) Cillino S, Casuccio A, Di Pace F, Pillitteri F, Cillino G. A five-year retrospective study of the epidemiological characteristics and visual outcomes of patients hospitalized for ocular trauma in a Mediterranean area. *BMC ophthalmology*. 2008 Dec;8(1):1-9
- 5) .Puodžiuvienė E, Jokūbauskienė G, Vieversytė M, Asselineau K. A five-year retrospective study of the epidemiological characteristics and visual outcomes of pediatric ocular trauma. *BMC ophthalmology*. 2018 Dec;18(1):1-9.
- 6) Yang CS, Wang AG, Shih YF, Hsu WM. Astigmatism and biometric optic components of diode laser treated threshold retinopathy of prematurity at 9 years of age. *Eye (Lond)* 2013;27:374–81 [PubMed]
- 7) Harvey EM, Dobson V, Miller JM. Prevalence of high astigmatism, eyeglass wear, and poor visual acuity among Native American grade school children. *Optometry and Vision Science*. 2006 Apr 1;83(4):206-12.
- 8) Ong E, Grice K, Held R, Thorn F, Gwiazda J. Effects of spectacle intervention on the progression of myopia in children. *Optometry and vision science: official publication of the American Academy of Optometry*. 1999 Jun 1;76(6):363-9.
- 9) Robaei D, Rose K, Kifley A, Mitchell P. Patterns of spectacle use in young Australian school children: Findings from a population based study. *J AAPOS* 2005;9(6):579-83.
- 10) Green DG, Powers MK, and Banks MS: Depth of focus, eye size and visual acuity. *Vision Res* 20:827, 1980.
- 11) Howland HC: Infant eyes: optics and accommodation. *Curr Eye Res* 2:217, 1982
- 12) Gullstrand A: The cornea. *In Helmholtz's Treatise on Physiological Optics, Volume I*, Southall JPC, editor. New York, Dover, 1962, p.320.
- 13) Farbrother JE. Spectacle prescribing in childhood: a survey of hospital optometrists. *Br J Ophthalmol* 2008; 92 (3):392-5. Epub 2008 Jan 22.
- 14) Mutti DO, Mitchell GL, Jones LA, Friedman NE, Frane SL, Lin WK, Moeschberger ML, Zadnik K. Refractive astigmatism and the toricity of ocular components in human infants. *Optometry and vision science*. 2004 Oct 1;81(10):753-61.
- 15) Kambala, Seema Sathe, Deepika Rathi, Anjali Borle, K. Rajanikanth, Tanvi Jaiswal, and Mithilesh Dhamande. "Evaluating the Color Stability of Ocular Prosthesis after Immersion in Three Different Immersion Media: An in Vitro Study." *JOURNAL OF INTERNATIONAL SOCIETY OF PREVENTIVE AND COMMUNITY DENTISTRY* 10, no. 2 (April 2020): 226–34. [https://doi.org/10.4103/jispcd.JISPCD\\_405\\_19](https://doi.org/10.4103/jispcd.JISPCD_405_19).
- 16) Khungar, Priyanka Naresh, Rohit Ashok Mistry, Sweta Kale Pisulkar, Trupti M. Dahane, Anjali Bhoyar Borle, and Surekha Dubey Godbole. "Prosthetic Rehabilitation of an Ocular Defect - A Case Report." *MEDICAL SCIENCE* 24, no. 103 (June 2020): 1061–66.
- 17) Sathe, Seema, Sweta Pisulkar, Sharayu Vinod Nimonkar, Vikram Belkhode, and Anjali Borle. "Positioning of Iris in an Ocular Prosthesis: A Systematic Review." *JOURNAL OF INDIAN PROSTHODONTIC SOCIETY* 20, no. 4 (December 2020): 345–52. [https://doi.org/10.4103/jips.jips\\_374\\_19](https://doi.org/10.4103/jips.jips_374_19).
- 18) Lohiya S, Pardasani R. Ocular Manifestations of Cytomegalovirus (CMV) - A Case Report. *JOURNAL OF EVOLUTION OF MEDICAL AND DENTAL SCIENCES- JEMDS*. 2021 Feb 1;10(5):319–22.

19) Singh KA, Taksande A. Diagnostic Accuracy of Red Reflex Test (RRT) for Early Detection of Ocular Abnormalities in Newborn. JOURNAL OF PHARMACEUTICAL RESEARCH INTERNATIONAL. 2021;33(32B):185–91.

UNDER PEER REVIEW