

## **Review on Digital orthodontics**

### **Abstract**

The field of orthodontics in its new era is venturing ahead to more up-to-date technological point of view. Digital technology has a significant effect on our lives ever since the modernization of mobile phones. The advances in technology have remodelled the diagnosis and treatment plan in the field of medicine. Digital workflows are currently increasing in the orthodontic practice and has touched every aspect of orthodontics - with transformations in the documentation, study casts, analysis of a dental malocclusion, smile designing, treatment planning and for fabrication of orthodontic appliances.

Three-dimensional imaging of the dentition, skeletal components and the face allows for treatment planning in three dimension and use of computer aided design (CAD) and computer aided manufacturing (CAM) for customization of orthodontic appliances. Software integration of digital models, 3D facial imaging and cone-beam computed tomography (CBCT) makes it possible to simulate the treatment plan and to attain a good communication with the patients. Recent advancement in digital videography has allowed the clinicians to capture patient's speech, oral and pharyngeal function, and smile at the same time.<sup>2</sup>

Effective and optimal tooth movement required for the patient can also be monitored with the digitalization. Moreover, this digital platform has created the advantage of accessing the patient's information from any location with the help of cloud based computing storage systems. These advancements have improved the efficiency, accuracy, consistency, and predictability of the treatment outcomes and have also led to progress in educational component and communication. The digitalization is bringing about a revolutionary change in the field of diagnosis and treatment planning, posing a challenge to clinical efficiency and knowledge.

### **KEY WORDS**

Digital Orthodontics, Digital Workflow, Digital Dental Models, Digital Radiography, CAD CAM, Orthodontics, Review

## **Introduction**

Orthodontics, the most computerized branch of dentistry, necessitates the careful acquisition and interpretation of a large amount of data in order to diagnose and formulate accurate plan treatment. Medical imaging has become an important tool in orthodontic treatment, research, and education. The employment of various evolutions in the area of orthodontics in learning the location of application malocclusions, growth and development , movement of teeth during rotation at different levels of the stomatognathic system has led to a more precise diagnosis and treatment planning.

Pretreatment diagnostic and treatment planning, as well as post-orthodontic assessment of dentoskeletal connections and face aesthetics , are all examples of how 3D imaging is used in orthodontics .The benefits of employing 3D models in orthodontics include three-dimensionally produced arch wires, research, and medicolegal applications.. Digital imaging techniques such as 2D CTscan, MRI, laser scanning, strephotogrametry, ,USG,e-models, digital imaging and smile analysis, and rapid prototyping[RPT].

Skeletal, facial, and dental diagnoses are all part of the orthodontic process. An orthodontist's primary responsibility is to realign various craniofacial components in anatomical and dynamic equilibrium in order to achieve aesthetically attractive results. However, we need information about the relationships between all of these in order to complete this procedure.in three spatial planes, components of the craniofacial complex The majority of traditional diagnostic tools are available. only show a two-dimensional image of the subject High-quality diagnostics are provided by modern technologies .Information in three dimensions to the orthodontist, assisting in the creation of the best treatment plan for the patient.[two] patients With the arrival of computers in dental and orthodontic offices, digital technology began to make its way into dental and orthodontic offices. Over the last three decades, digital photography and radiography, as well as technical breakthroughs, have ushered in the era of the 1970's.Digital dental models, for example, have mostly supplanted their analogue predecessors, paving the way for new possibilities.<sup>[5,6]</sup>

Other technologies are used in treatment planning.

## **TECHNOLGIES IN DIGNOSIS**

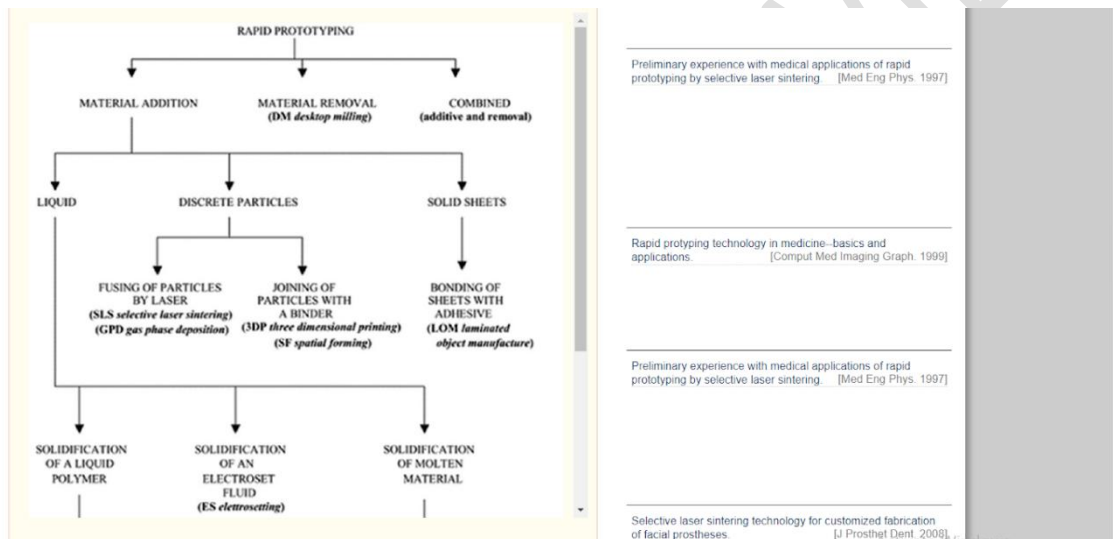
### **1 .RAPID PROTOTYPING [RPT]**

In the diagnosis and evaluation of the malocclusion in dentistry, necessitates the careful collecting and analysis of a huge amount of data in the evaluation of the patient. It's a collection of manufacturing technologies that allow Direct physical realisation of 3D computer models. This technology precisely transfers 3D computer data from a specific file format (STL file) to a physical model, layer by layer.

Before going into mass or large-scale manufacturing, every prototype should be evaluated, defect-corrected, and approved. . Prototypes can also be used for very specific or limited

purposes, which is when they are referred to as preseries models. Thanks to advances in information technology, three-dimensional models based on virtual prototypes may now be developed and built. Thanks to a method known as computer aided design, computers can now be utilised to generate highly detailed designs that can be studied from numerous perspectives (CAD). A computer-aided manufacturing (CAM) technique has been developed to turn virtual items created using CAD into physical objects. (1)**BRACKET MANUFACTURING BY RPT**

**Biglino G** et al. has given the application of rapid prototyping in therapeutic settings. CAD/CAM technology is used to combine the two previously separate activities of bracket manufacture and bracket positioning into a single unit. Brackets for lingual orthodontics are created using digital recording of the malocclusion. The brackets are then individually built and placed in the computer using rapid prototyping. The following figure shows rapid prototyping classification (1). The following are some of its uses: custom-made brackets for each patient's crown anatomy. [italics] On the 3D Biomodels, mock surgery procedures can be done, providing for the most precise input into management choices, pre-operative planning, and surgical method selection.



**Image 1. Rapid prototyping**

## 2.STEREO LITHOGRAPHY (SLA)

The stereolithography (SLA) technique is the most widely utilised RPT technique. Stereolithography (commonly known as SLA) is the earliest additive manufacturing technique, which uses an ultraviolet laser to turn liquid photopolymer into solid cross-sections. Despite

being the oldest technology, it remains the most important since no other additive manufacturing technique covers a wider range of applications for exceptionally precise and long-lasting prototypes of all shapes and sizes. This page gives a summary of the SLA process, as well as details on the elements that influence it and its uses. A sketch of the mechanical properties of the SLA processed parts is also included in the study, as well as an overview of current technological advancements and trends.(2)

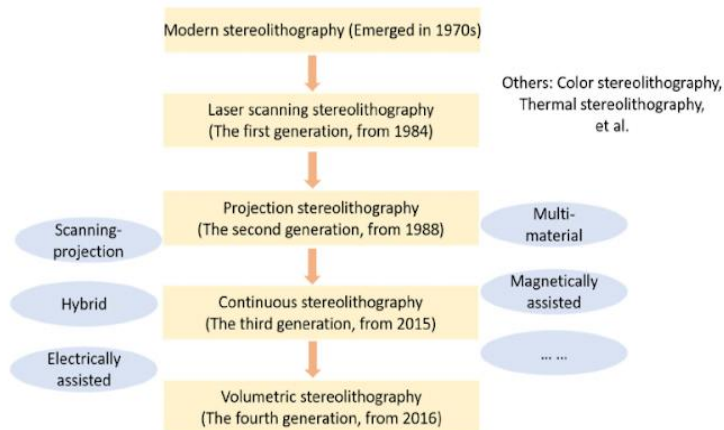



Image 2. STEREO LITHOGRAPHY

## 2 . SMILE ANALYSIS



Photographic: Dr Valerio Bini, Italy

Fig 1. Analysis of smile

### Smile Analysis with the SMILE MESH PROGRAMME

Hulsey utilised this process by hand first, then Ackerman updated and computerised it. A JPEG file is created from the frame that best portrays the patient's social smile. The grin image is then opened in SmileMesh , a tool that measures 15 different aspects of the smile. The difference between current orthodontic practise and that of our forefathers is that we can now dynamically visualise and quantify our patients' smiles, according to **Nitu Dubey, Nidhi Malik, Amit Prakash, and Sonali Rai** et al. The smile's focal lines are not a throwback; rather, they represent a reaffirmation of the value of physical diagnosis and an understanding of the soft tissues that both guide our treatment planning and limit our treatment response. She came to the conclusion that these characteristics are critical in today's grin analysis. (smile) <sup>(3)</sup>

## 3. DIGITAL PHOTOGRAPHY

Imaging is an important tool in orthodontics because it gives doctors a documented perspective of craniofacial and dental structures before, during, and after treatment. Alexander Wolcott, a New York City dentist who invented the camera in 1839, has permanently linked dentistry and photography in history. A benefit of digital photography

over traditional film is the ability to shoot an unlimited number of shots for no additional cost. Other benefits of digital photography include instant access to the photographs with the ability to delete them. Image integrity is not harmed as a result of ageing, abrasions or dust. Also film processing fees and simple storage, duplication, transmission, and retrieval.

Sharthy Kumar Sheety B –has demonstrated how it may be used in orthodontics, which is critical in patient diagnosis. Which has enable to assess the pre treatment appearance and post treatment appearance of the patient. Also for checking of ongoing treatment. Beneficial for the other people ongoing to plan the ortho treatment .

Because of the intrinsic versatility of digital photographs, a single image can be used for several purposes. This ability to increase communication through visualization empowers the physician in his connections with both patients and colleagues. • An image kept in a patient's record, for example, can be included in a communication to a referring doctor, emailed, printed, and delivered to the patient. It has been demonstrated that when patients understand their illnesses, they are more willing to accept treatment. Images taken before and after treatment can be effective marketing tools. These same photographs can also be utilised to make advertisements for local media such as newspapers, magazines, and even television commercials to promote practice . Orthodontic practise could benefit from the use of digital models. with current technology and future uses. They make exact measurements and visualisations of therapy outcomes possible . The ability to complete diagnostic setups quickly, achieve accurate bracket placement from the outset of therapy, and increase patient-clinician communication all benefit treatment.. In the end, this procedure results in better treatment quality and patient satisfaction.

One of the main reasons is the ease with which these cameras may be used, as well as the ability to duplicate or erase poor photographs on the fly. You don't have to wait till the film is developed to look at your images. Any flaws in digital photography can be easily corrected right away. •Direct digital photography, which turns photographs almost instantly into a digital file, has a number of advantages in dentistry, including the ability to see images almost immediately and the ability to retake images as needed.<sup>(4)</sup>

#### 4. 3D laser scanning

**Hajeer MY, Millett DT,** et.al and others have shown that 3D imaging can be done. Laser scanning gives 3D pictures for orthodontic, particularly orthognathic , treatment planning and evaluation in a less invasive manner. 3D laser scanners are also capable of creating digital models. However, there are several disadvantages to using this technology for 3D scanning. • Because the scanning technology is so slow that it generates distortion in the scanned image, patients should remain still for at least one minute as the scanner circles around their heads. Because of the risk of patient mobility and security issues when employing lasers, intraoral laser scanning to produce digital models is extremely difficult. Safety concerns, such as subjecting one eye to a laser beam is very dangerous. subjecting one eye to a laser beam is very dangerous important when working with children. Surface colour makes it difficult to detect landmarks because it is unable to capture soft tissue surface roughness.

A planar laser scanner is a tool for reconstructing three-dimensional (3D) things digitally. The length, width, and depth of an item can be determined by triangulating distances between the reflective laser beam and the scanned surface. The scanner's ease of use has expanded scientific and health research opportunities. A Minolta Vivid700 3D surface laser scanner was used to test the accuracy of making 3D object reproductions (Minolta

USA, Ramsey, NJ). A mathematically corrected tube, a dental study model, and a plaster facial model were used to exact match and consistency. (5)

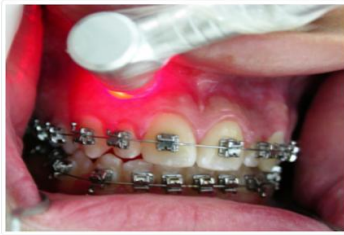

Fig 2 Laser scanning

## 5. Magnetic resonance imaging (MRI)

The resonance signal produced by the hydrogen nucleus is employed in MRI. As a result, it's basically water imaging in tissue. The technology of magnetic resonance imaging (MRI) is the greatest contrast-resolving medical imaging approach. In radio-stimulated cells, the energy released by hydrogen atoms is transferred to numbers, which are subsequently analysed on a computer and converted to images. In a magnetic field, radio waves are steered to the right area for investigation. Despite its recent history in TMJ research, MRI is widely regarded as the gold standard for TMJ imaging. MRI Signs and Symptoms

- TMJ and airway MRI imaging
  - Tonsillitis and adenoiditis (upper airway examination at its best)
  - Cleft lip and palate (cleft lip and palate)
  - Cysts, infections, and tumours are all things to be aware of.
  - Warnings and Restrictions
  - Patients who have pacemakers in their hearts.
  - Patients who have metal aneurysm clips in their brain.
- Even the tiniest movement of the clip might cause bleeding.

The majority of orthodontic patients are young and more sensitive to the detrimental effects of ionising radiation, according to Dr. Akash Shah's evaluation of the use of MRI in orthodontics. We must make every effort to limit the amount of ionising radiation our patients are exposed to. The use of MRI in orthodontic diagnosis and screening could be a significant step forward because it would prevent all ionising radiation exposure for patients, at least during the first screening and diagnosis. The ALARA concept will be completely implemented.

Jadhav et al did a study to evaluate facial soft tissue thickness in vertical and horizontal growth pattern in skeletal class I and II malocclusion using MRI. They concluded that maximum parameters showed increased values of FSTT with class II horizontal cases and decreased values with class II vertical growth cases. Average values were observed for class I cases for both genders. The FSTT data will aid in the planning and effectiveness of orthognathic surgery. Orthodontics alone or orthodontics in combination with orthognathic surgery could be used as treatment. When retraction of teeth is required in individuals with higher vertical dimension, caution should be exercised. The thickness of the soft tissue is

diminished. In addition, incisor retraction is required for a horizontal development pattern, resulting in better soft tissue follow-through. When the jaws must be adjusted using orthognathic surgery, Soft tissue must be treated with care during surgery. (figure

)<sup>(6)</sup>

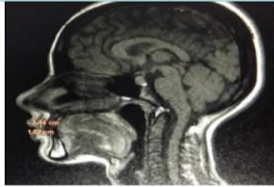


Figure No. 3 - representation of landmarks – PTA – A' and ULS – SLS' (Maxilla)

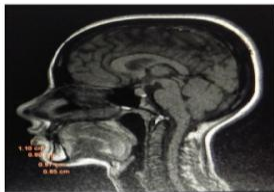


Figure No. 4 - representation of landmarks – LLS – LI', PTB – ILS', POG' and M – M'

## 7. Ultrasonography (USG)

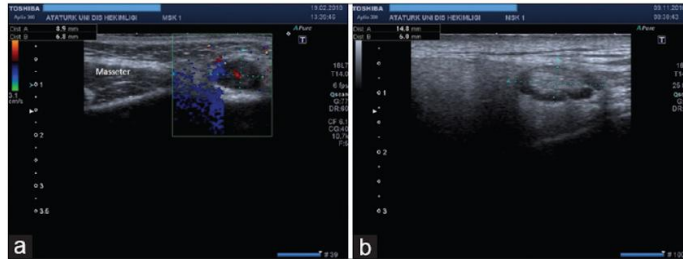
Ultrasound has recently become popular in dentistry for diagnostic procedures:

Ultrasound has found its way into orthodontics in a variety of ways-

1. The distinction between an infantile and an adult swallow
2. Condylar position imaging
3. Zygomatic fractures diagnosis
4. Determining the mass of the masseter muscle
5. Root resorption caused by orthodontics heals
6. Orthodontic tooth mobility is accelerated

**F.Cagalan** -has made a contribution In patients undergoing RPE, USG may be a valuable tool for assessing mid-palatal sutural openness. In medicine, USG is a diagnostic procedure that uses ultrasonography to view interior organs. The Curie brothers established the core concepts and applications of ultrasonography in 1880, while the Dussik brothers described USG imaging in 1937. Baum et al. published the first diagnostic USG findings in dentistry in 1963. Unlike X-rays, the sound waves employed in USG are not electromagnetic. As a result, this testing approach is free of X-ray and ionising radiation, and it can be utilised safely even in pregnant women and children. Ultrasound pictures are formed by transmitting ultrasound waves to the tissue through transducers, which use the piezoelectric effect to transform electrical energy into ultrasonic sound waves. Probes are the heads that carry the transducer in USG devices. Different viewing regions are formed depending on the shape, frequency, and arrangement of the probe. Low frequency is important in the USG concept.<sup>(7)</sup>

According to a report by the United States is a world leader in imaging technology, with a lot of research going on in the medical field. It's safe, quick, easy to transport, and inexpensive. In order to acquire information on the system's correct and suitable clinical application in dentistry, more study into the US's clinical uses in the dento-maxillofacial region is needed.<sup>(8)</sup>



**Fig 5. TECHNOLOGIES IN TREATMENT PLANNING**

### 1. Computerized cephalometry: tracing, superimposition and treatment planning

The two traditionally distinct processes are combined using cutting-edge CAD/CAM technology. . Because of this constraint, the position of the incisors was determined using a static rather than a dynamic record. When it comes to bracket manufacturing and bracket installation, there are a few things to consider. According to Mah et al., sophisticated methods of cone beam imaging techniques in orthodontics exist. Cone Beam Computed Tomography (CBCT) in Orthodontics: Advanced Usage have been presented by **Mah et al.** Manually recording and analysing a single cephalometric measurement takes a lengthy time .Cephalometric computer programmes frequently comprise hundreds of analyses, any of which can be run at the same time under the operator's control. The clinician's capacity to provide a more accurate diagnosis is enhanced by rapid access to such a broad range of data, while simultaneously saving countless hours of labour. It assists in the Treatment Planning And Superimposition. Growth and treatment prognosis, as well as a visible treatment goal .Prediction, planning, and tracing<sup>(9)</sup>

**Barbosa Guerra da Silva** et al. did a study showing how critical it is for an orthodontist to stay up to date on the progress of image-gathering technologies, which are critical for diagnosis, As a result, technology plays an important role in his patients' orthodontic treatment's effectiveness.<sup>(10)</sup>

For the below chart refer to the model analysis app <sup>(11)</sup>




Figure 1. Model Analysis App Home Screen

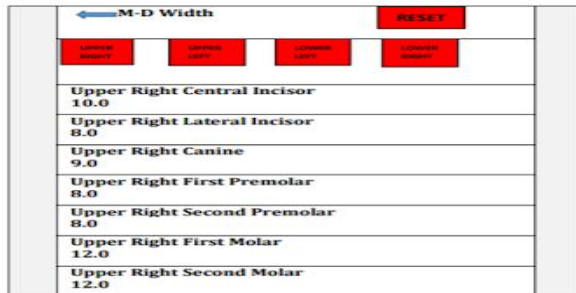


Figure 4. Screen for Entry of Vertical Dimension

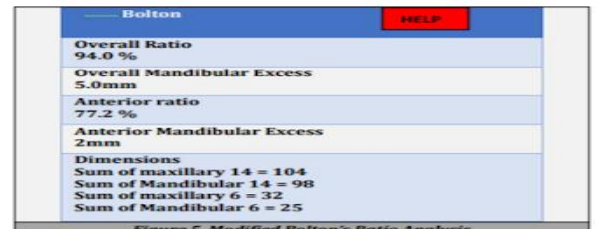

Figure 5. Modified Bolton's Ratio Analysis

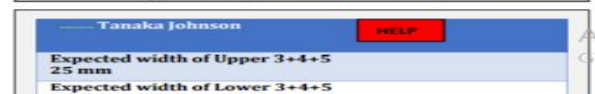

Fig 6. SOFTWARES IN TREATMENT PLANNING

There are various software's in treatment planning and they are as follows:

- DICOM
- ORTHOCAD
- DIGIGRAPH
- VISTADENT
- DOLPHIN
- NEMOCEPH
- SURESMILE

### 1. DICOM

DICOM (Digital Imaging and Communication in Medicine) is a protocol for sharing radiologic pictures and other medical data between processors and imaging equipment, as well as between equipment and software platforms from different manufacturers.

A DICOM image file includes an x-ray image or series of images (such as a numerous slice CBCT imaging study) as well as patient-related information from a "library" of pre-selected preset terminology (for example, patient name, identification number, and acquisition modality, to name a few). The DICOM library is vast, and it is reviewed on a regular basis to meet different identity demands. A DICOM-compliant image file mimics a stacked Photoshop or JPEG with the addition of a data'set' or metafile.

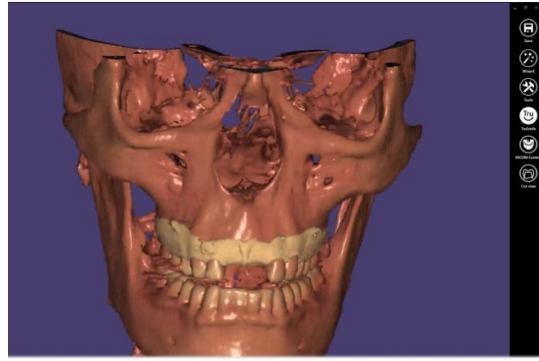


Fig 7. Digital Imaging and Communication in Medicine

## 2.DIGIGRAPH

### **Clinical/Graphic/research application**

- Software filters can be used to modify digital photographs

**G.M.doll** did a study was conducted to demonstrate that cephalometric evaluations of lateral cephalograms enable critical diagnostic as well as issues for targeted therapy Such radiographs, however, must be considered with caution. low dose of radiation. Cephalometry without radiation would be a major advance in orthodontic diagnosis. However, certain processing software research and development, as well as the development of a unique acoustic approach, are still needed. Cephalometric examination of lateral cephalograms can be used to make important conclusions about The diagnostic and treatment plan Such radiographs, on the other hand, should be taken with a minimal dose of radiation. You can now utilise a cephalometric approach based on distance estimates with the Digigraph 100. of produced sonic waves (Dolphin Imaging Systems Inc., USA). The purpose of this research was to see how well this method matched the requirements for orthodontic reliability and validity. In this study, 50 people were examined using both conventional and sonic cephalometry , with lateral cephalograms traced by hand and Jarabak analysis performed in both cases. A radiograph needed to assess was also provided for inputting lateral cephalograms into the Digigraph <sup>(12)</sup>

## 3.VISTADENT

The vistadent image control system gives you complete control over an image you've saved in the programme. Cut and paste, and also more advanced tools like the smile library, are all available for modifying.can be used to simply change images to indicate treatment objectives..

For the below figure <sup>(13)</sup>

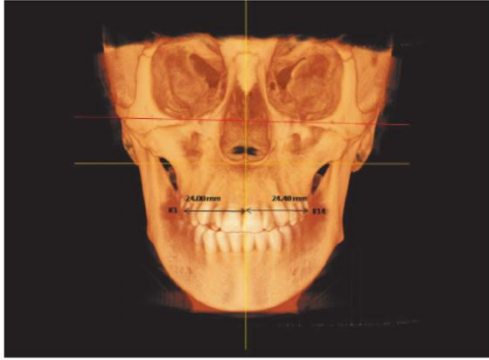


Fig 8. Vistadent

### 3.DOLPHIN

Dolphin's product line comprises software and services for every aspect of the practise, removing the time-consuming and inconvenient process of navigating different technology suppliers.

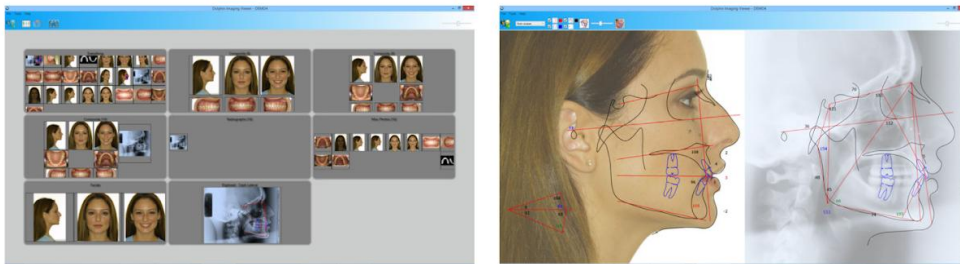


Fig 9. Dolphin's product line

: Although surgical soft tissue prediction is a good strategy, it is unknown how accurate it is in tow-jaw surgical operations, according to **Robert.. J.Peterson's** The goal of this study was to see how accurate In class III patients with maxillary progress, Dolphin Imaging's VTO soft tissue methodology was used. and mandibular damage, as well as to demonstrate the computer's efficacy under such challenging conditions. <sup>(14)</sup>

#### E-models in orthodontics

Orthodontics research models are important clinical data that are made up of precise plaster casts. reproduction

Digital models are also a great way to educate patients. It helps the clinician and the patients communicate more effectively. It may eliminate many of the drawbacks associated with utilising plaster models, and as a result, it is gaining popularity. This is done by scanning the imprint or plaster study models using a laser. After the scanning is completed, the digital models are created using (CAD/CAM) technology and transformed into a digital, three-dimensional image of the dentition. The digital models can be manipulated and viewed from all angles thanks to software. The software can also perform many types of model analysis. One of the many advantages of the digital model is that it minimises the amount of space required to store the models. The image can be easily retrieved and transmitted to other computers.

#### Model Analysis App

Study casts are very useful diagnostic tools. The study models depict the maxilla and mandibular dental arches in three dimensions. The maxillary and mandibular dental arches are examined in model analysis. In orthodontic diagnostic and therapeutic preparation, model analysis is a useful technique. because it examines the maxillary and mandibular dental arches in all three planes of space (transverse, vertical, and sagittal plane). Because therapy differs according on the severity of the crowding, space analysis using dental casts is required for this purpose. It also aids in bracket placement.

We created an Android app to make the mathematical computations needed to analyse orthodontic casts and bracket placement easier. Model Analysis App is a free Android app (an iPhone app is in the works) that may be downloaded Google Play ([play.google.com/store](https://play.google.com/store)) is a great place to start.or scanned with an Android phone using the QR code on this page. Missing tooth formulas, as well as a bracket MBT chart location have been introduced to the new edition.

The software does quick and precise mathematical calculations in the following areas:

1. Boltons ratio<sup>(1)</sup>
2. Boltons ratio for Vidarbha population (SM ratio) <sup>(2)</sup>
3. Modified Boltons ratio (ViVan ratio) <sup>(3)</sup>
4. Carey's Analysis
5. Ashley Howe's Analysis
6. Pont's Analysis
7. Tanaka Johnston
8. Peck and Peck index
9. Formula for missing Maxillary Central and Lateral Incisor (ViVan Formula)
10. Formula for missing Maxillary and Mandibular Canine (VM Formula)



14. Celik E, Polat-Ozsoy O, Toygar Memikoglu TU. Comparison of cephalometric measurements with digital versus conventional cephalometric analysis. The European Journal of Orthodontics. 2009 Jun 1;31(3):241-6.

15. Jadhav VV, Tiwari MM, Kamble R, Vasudevan SD, Daigavane P. Model Analysis Android App.

Journalif Evolution of Medical and Dental Sciences. 2020 Dec 14;9(50):3825-8.

UNDER PEER REVIEW