

Prevalence of the use of particulate graft versus block bone graft in ridge augmentation- A hospital based retrospective study

ABSTRACT

Aim: To assess the prevalence of the use of particulate graft versus block bone graft in ridge augmentation.

Introduction: Ridge augmentation is a process of replacing the lost bone of residual ridge by grafting natural or synthetic material. Dimensional changes in the alveolar ridge after extraction often compromises on achieving optimal implant stability and placement of implants in the right prosthodontic positions. These situations demand augmentation of the residual ridge to achieve successful implant placement and long-term survival.

Materials and Methods: Case sheets of thirty-eight patients who had underwent ridge augmentation procedure were analysed for the study. The collected data was statistically analysed using chi square test and the results were obtained. SPSS software was used for obtaining the results.

Results and Discussion: Majority of the participants in the study were around the age 15-30 years. Around 74% of the participants have undergone particulate bone graft rather than block bone graft. From the study it is proven that around 81% of the augmentation type are for the hard tissue.

Conclusion: Hence from the study it is proven that particulate graft is more commonly opted than block bone graft.

Keywords: Alveolar ridge, Bone grafting, Innovative technique, Particulate graft, Ridge augmentation

INTRODUCTION

Ridge augmentation is a process of replacing the lost bone of residual ridge by grafting natural or synthetic material [1]. Dimensional changes in the alveolar ridge after extraction often compromises on achieving optimal implant stability and placement of implants in the right prosthodontic positions [2]. These situations demand augmentation of the residual ridge to achieve successful implant placement and long-term survival [3,4]. Alveolar ridge augmentation can be completed with various types of bone augmentation materials (autogenous, allograft, xenograft, and alloplast). Currently, autogenous bone is labeled as the "gold standard" because of faster healing times and integration between native and foreign bone [5].

In patients with insufficient bone height and width, the successful placement of dental implants is difficult with regards to maintaining an ideal pathway and avoiding important anatomical structures [6]. Vertical and/or horizontal ridge augmentation may be necessary using various bone substitute materials and bone graft procedures [7]. However, effective one-wall reconstruction has been challenging due to its poor blood supply and insufficient graft stability. In this paper, the authors summarize current evidence-based

literature based on the author's clinical experience. Regarding bone substitutes, it is advantageous for clinicians to select the types of bone substitutes including autogenous bone [8]. The most important consideration is to minimize complications through principle-based ridge augmentation surgery.

A particulate graft consists of small bone particles placed strategically around a tooth site. Particulate grafting can be done before or during implant placement [9]. The block bone graft is another type of graft that we use. The block bone graft is necessary when there are large defects in the jawbone. To perform the block bone graft, we harvest a small block of bone from the back of the jaw. We place the block into the defect, then hold it in place with small titanium screws [9,10].

Vertical and/or horizontal ridge augmentation is a technique to reconstruct a one-wall defect that receives blood supply mainly from the recipient bone and little from the above soft tissue. The soft tissue could potentially be damaged during the flap elevation process and blocked using a barrier membrane [11]. Therefore, if a large amount of bone graft is performed vertically or horizontally, only some bone substitutes could be remodeled into viable bone tissue with the amount estimated to be within 3 mm [12]. The other areas would remain immature woven bone for a long period of time and be replaced by fibrous granulation tissue due to poor blood supply. Therefore, the healing process of ridge augmentation should be well-understood for successful dental implantation. Horizontal ridge augmentation has been known to have more stable results compared to vertical ridge augmentation [5]. Our team has extensive knowledge and research experience that has translate into high quality publications [13–25],[26–30] [31] [32]. Hence, the aim of the study is to assess the prevalence of particulate graft versus block bone graft in ridge augmentation.

MATERIALS AND METHODS

The study was conducted with the approval of the Institutional Ethics Committee. The survey was conducted in the month of May 2020. The study consisted of one reviewer, one assessor and one guide. 38 patients who underwent ridge augmentation procedure were analysed in the study. Age, gender, bone defect type and the type of bone graft used were collected. The collected data were tabulated in an excel sheet and using SPSS software the results were obtained. The results were obtained and statistically analysed through SPSS software, chi square test was done to check the association and a p value of 0.05 was said to be statistically significant.

RESULTS AND DISCUSSION:

From the study it is proven that the majority of the patients who have undergone ridge augmentation procedure are between the age group of 15-30 years (Figure 1) which correlates with the study done by Bradley S et al., 2007 [33]. As we know that permanent dentition extractions are more commonly done nowadays due to poor oral hygiene and follow up. Hence during extraction, there might be some chances of the bone to not regenerate completely and not adequate according to the need of implants [34]. So grafting is done commonly among younger adult age groups which indicates that implant procedures are most commonly done among younger adults [5].

Around 73.6% of the patients from the present study have undergone particulate bone grafting than block bone grafting (Figure 2) which correlates with the study done by Gerado et al., 2018 [35]. An adequate bone volume is needed in order to guarantee the long-term success of dental implant placement.

Particulate graft consists of small bone particles placed strategically around a tooth site. Particulate grafting is usually for a small single tooth area in preparation for a single implant placement. Particulate grafting can be done before or during implant placement [36]. Particulate grafts have been used in cases of small or peri-implant defects such as dehiscences and fenestrations, and combination with guided bone regeneration (GBR) techniques is also possible [36,37]

This study proves that around 44.4% of the patients had Class I siebert type defect commonly (Figure 3) which correlates with the study done by Christopher J et al., 2015 [7]. In prosthetic dentistry, dentists may face challenges in treating patients with alveolar ridge defects in edentulous area [38]. Localized alveolar ridge defect can be seen as a volumetric deficit of limited extent of soft tissue and bone within the alveolar process [39]. Alveolar ridge defect may occur due to injury, trauma, denture wears, and periodontitis. As a dentist who faces such cases, it is required for them to replace the missing tooth and close the defect for the patient to achieve esthetic, phonetic, and mastication [40].

Figure 4 represents the association between gender and type of bone graft and it is shown that particulate bone grafting has been done more in male patients but the results are not statistically significant (Chi-square analysis was done and P-value was found to be $0.9 > 0.05$, which is statistically not significant). Figure 5 represents the association between type of defect and type of bone graft, it is proven that particulate bone grafting has been done more in type 1 defect type (Chi-square analysis was done and P-value was found to be $0.01 < 0.05$, which is statistically significant). Packing of bone defect with particulate allografts is a commonly performed clinical procedure. However, the ideal size of bone particles used to fill bone defects is ill-defined. Figure 6 represents the association between age and type of bone graft, it is proven that particulate bone grafting has been done more in the age group of 15-30 years individuals than block bone graft (Chi-square analysis was done and P-value was found to be $0.02 < 0.05$, which is statistically significant). The age plays a vital role in determining the type of bone graft required for grafting procedure. From our current study it is shown that the young aged teens and adults between 15-30 years have undergone more bone grafting procedures. The limitations of the study is that it is a single centered study, so the results cannot be generalised and this study did not include all age groups. The future scope of the study is to focus further on better diagnosis and treatment plan for ridge and also the study can be done on a larger population.

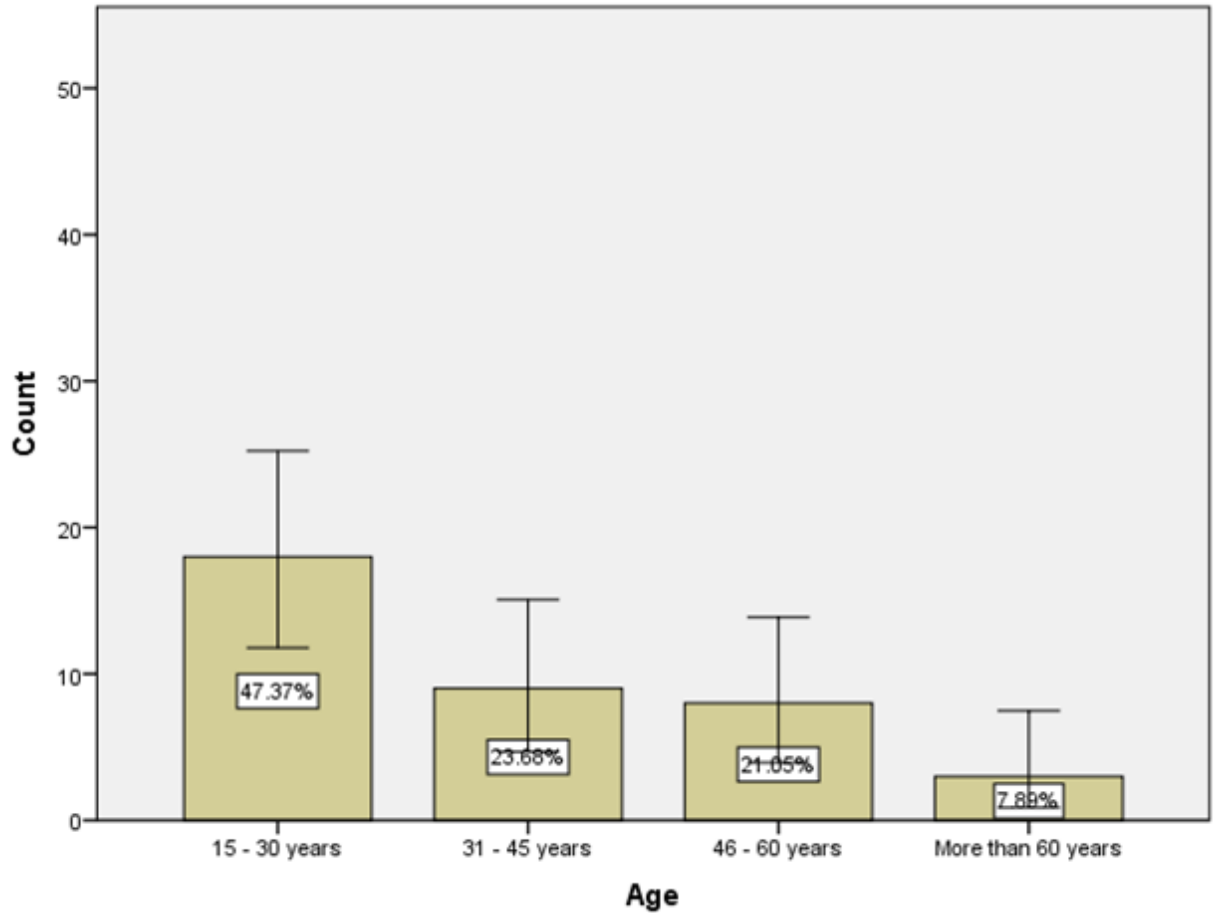


Fig. 1. This graph represents the demographic details of the participants like age. X-axis represents the age and Y-axis represents the percentage of participants who responded. Majority of the participants (47.37%) are around the age group of 15-30 years followed by 31-45 (23.6%).

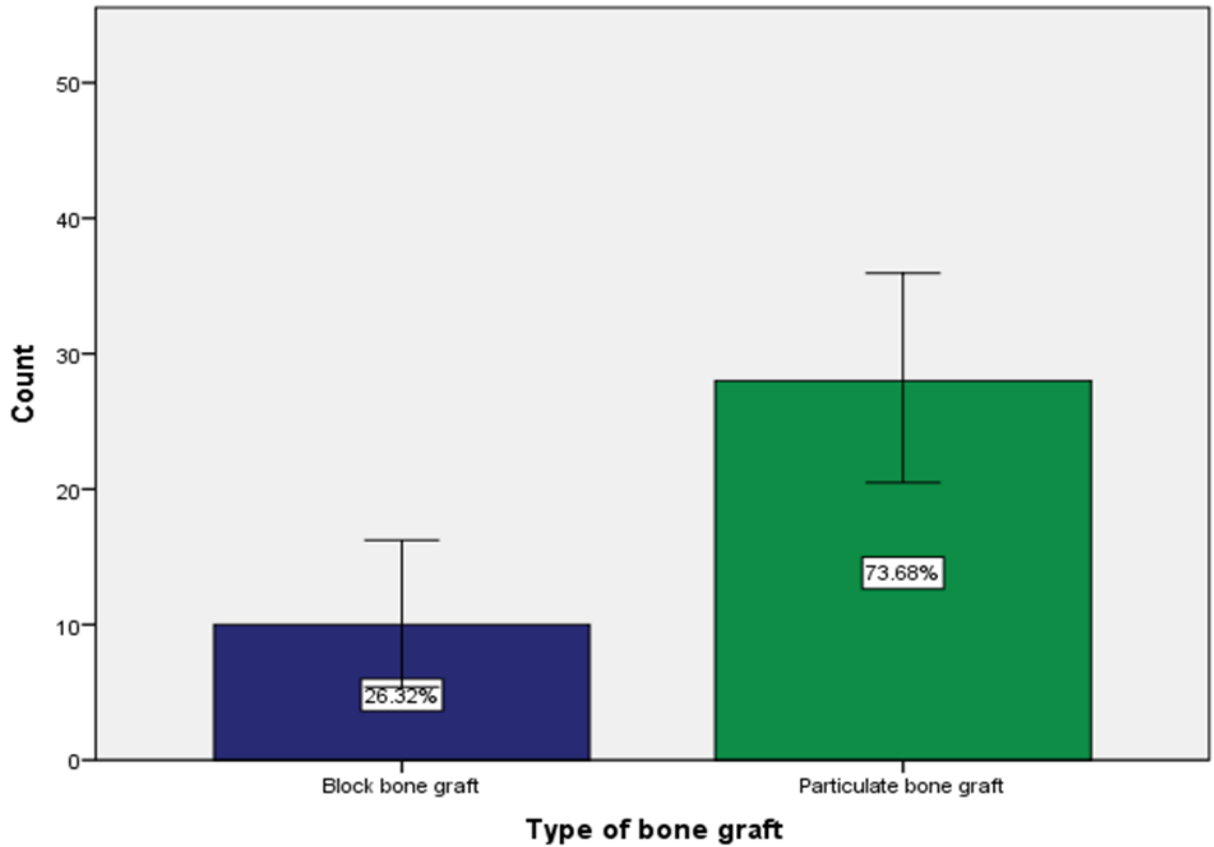


Fig. 2. This graph represents the type of bone graft used for the participants. X axis represents the type of bone graft and Y axis represents the percentage of participants who responded. For the majority of the participants (73.6%), particulate bone graft has been used.

UNDER PUBLICATION

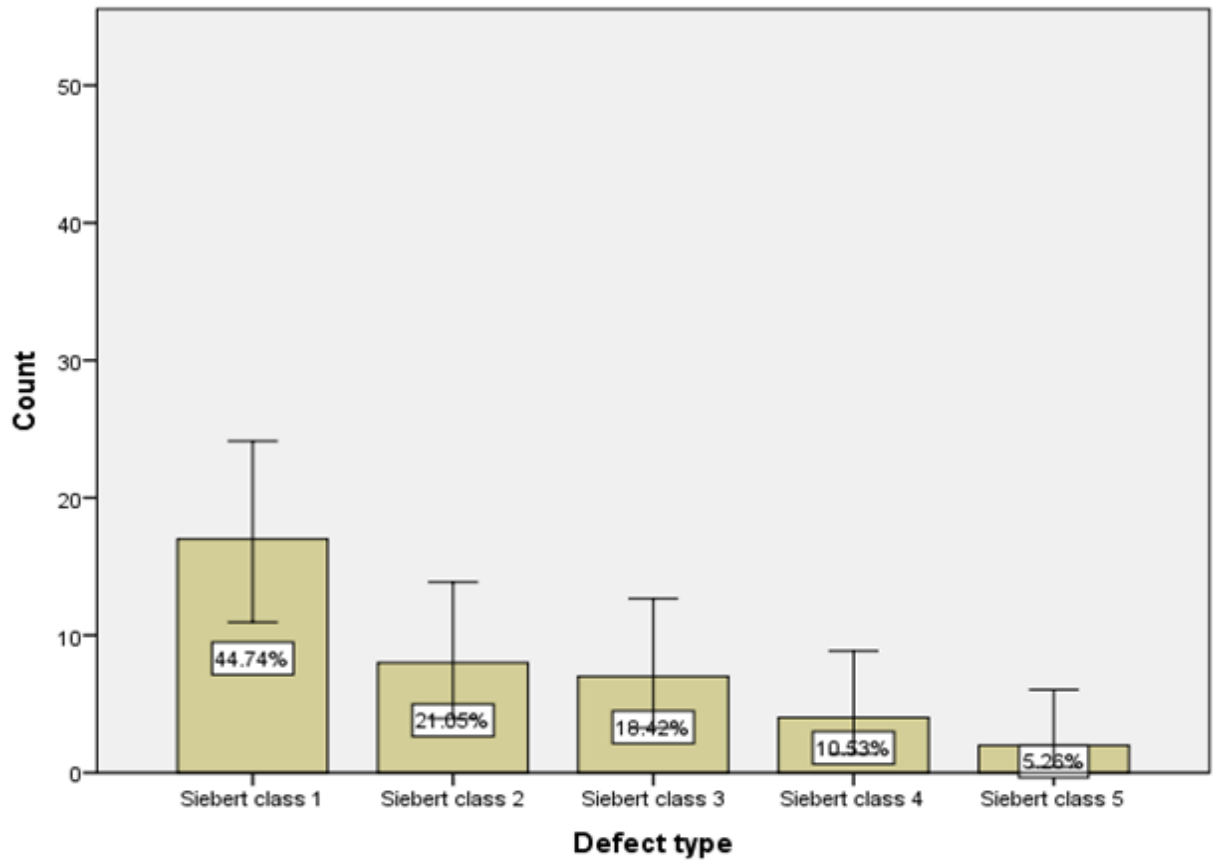


Fig. 3. This graph represents the defect type of the alveolar ridge. X axis represents the defect type and Y axis represents the percentage of participants responded. Around 44.4% of the participants have had siebert class I defect.

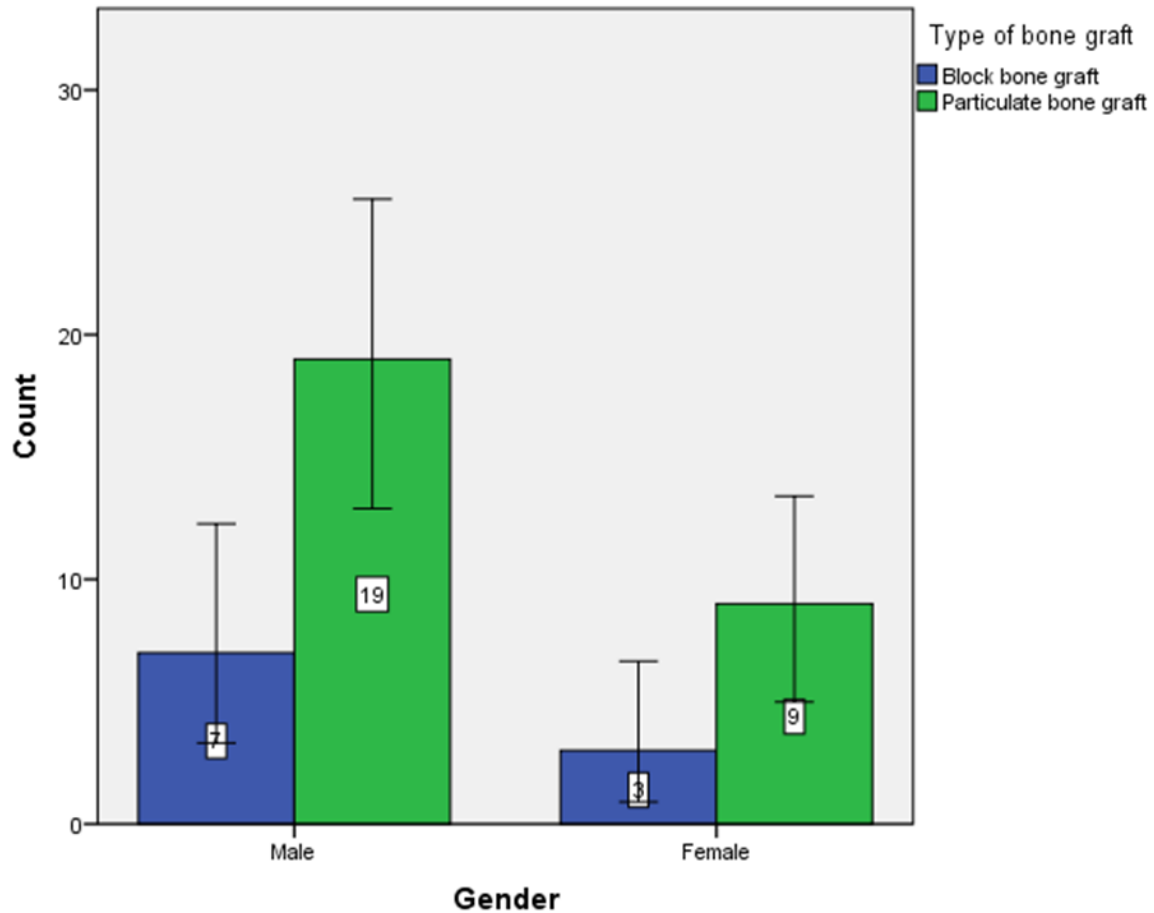


Fig 4. This graph represents the association between gender and type of graft. X axis represents the gender and Y axis represents the type of graft. Blue represents block bone graft and Green represents particulate bone graft. Association between gender and type of bone graft was done and P-value was found to be $0.9 > 0.05$, which is statistically not significant.

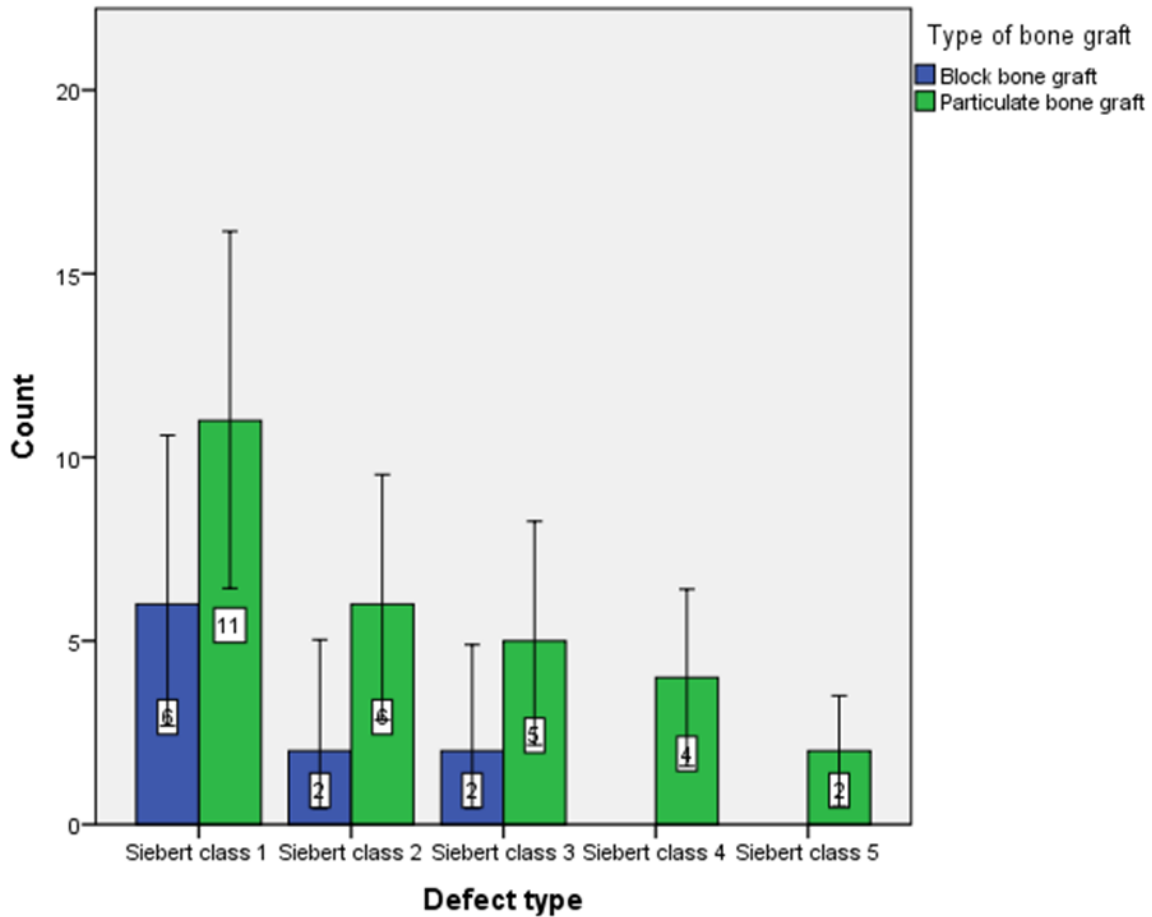


Fig. 5. This graph represents the association between defect type and type of graft. X axis represents the defect type and Y axis represents the type of graft. Blue represents block bone graft and Green represents particulate bone graft. Association between defect type and type of bone graft was done and P-value was found to be $0.01 < 0.05$, which is statistically significant.

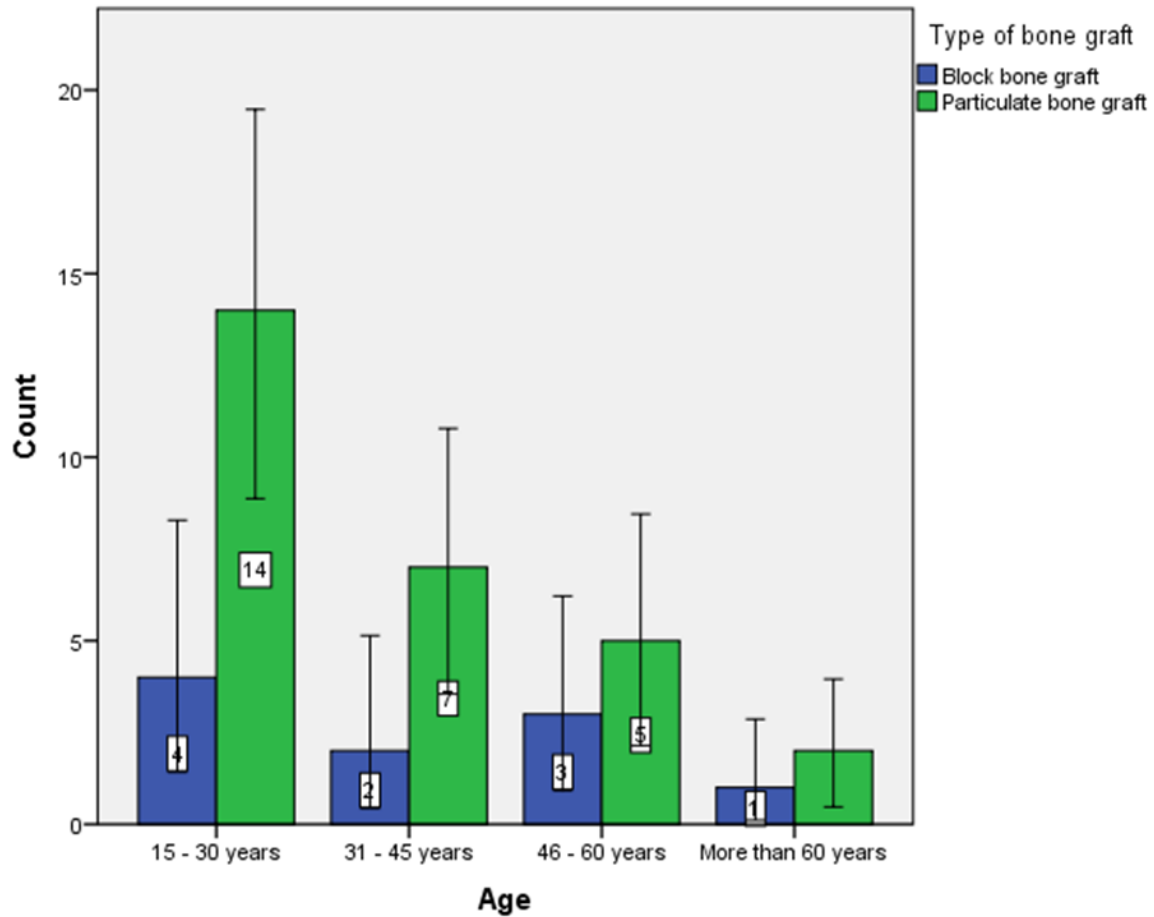


Fig. 6. This graph represents the association between age and type of graft. X axis represents the age and Y axis represents the type of graft. Blue represents block bone graft and Green represents particulate bone graft. Association between age and type of bone graft was done and P-value was found to be $0.02 < 0.05$, which is statistically significant.

4. CONCLUSION:

Hence from the study it is proven that particulate graft is more commonly opted than block bone graft. However, some have used particulate block graft to secure vertical or horizontal increments of the alveolar process. The present study also shown that particulate bone grafting has been done more in type 1 defect type. Further multi-centered studies are required to analyse the current trends in bone grafting.

COMPETING INTERESTS DISCLAIMER:

Authors have declared that no competing interests exist. The products used for this research are commonly and predominantly use products in our area of research and country. There is absolutely no conflict of interest between the authors and producers of the products because we do not intend to use these products as an avenue for any litigation but for the advancement of knowledge. Also, the research was not funded by the producing company rather it was funded by personal efforts of the authors.

REFERENCES

- [1] Froum SJ, Kadi RO, Wangsrimgkol B, Hengjeerajaras P, Reis N, Yu PYC, et al. The Custom Alveolar Ridge-Splitting (CARS) Technique for Predictable Horizontal Ridge Augmentation in the Atrophic Anterior Maxilla: A Retrospective Case Series Study. *Int J Periodontics Restorative Dent* 2021;41:397–403.
- [2] S C, Chaturvedi S. Immediate Implant with simultaneous Ridge Augmentation. *Journal of Dental Problems and Solutions* 2017:036–9. <https://doi.org/10.17352/2455-8418.000045>.
- [3] Alveolar Ridge Augmentation with Titanium Mesh and Particulate Allograft. *International Journal of Science and Research (IJSR)* 2016;5:2234–9. <https://doi.org/10.21275/v5i2.nov161773>.
- [4] Renapurkar S, Troulis MJ. Alveolar Distraction Osteogenesis for Vertical Ridge Augmentation: Surgical Principles and Technique. *Vertical Alveolar Ridge Augmentation in Implant Dentistry : A Surgical Manual* 2016:222–8. <https://doi.org/10.1002/9781119082835.ch21>.
- [5] Tolstunov L. Alternative Intraoral Block Bone Grafting Techniques for Horizontal Alveolar Ridge Augmentation in Implant Dentistry. *Horizontal Alveolar Ridge Augmentation in Implant Dentistry: A Surgical Manual* 2016:166–70. <https://doi.org/10.1002/9781119019916.ch15b>.
- [6] Kumar V, Rattan V, Rai S, Singh SP, Mahajan JK. Comparative Assessment of Autogenous Cancellous Bone Graft and Bovine-Derived Demineralized Bone Matrix for Secondary Alveolar Bone Grafting in Patients With Unilateral Cleft Lip and Palate. *Cleft Palate Craniofac J* 2021:10556656211025197.
- [7] Nunes MP, Nunes LFP, Filho DPN, Pinho RCM, Cimões R. Bone Ring Technique for the Treatment of Vertical and Horizontal Bone Defects with Immediate Implants: A Report of Two Cases. *Int J Periodontics Restorative Dent* 2021;41:413–21.
- [8] Kim SG. Bone Grafting Using Particulate Dentin. *Advanced Biomaterials VII* 2007:29–32. <https://doi.org/10.4028/0-87849-436-7.29>.
- [9] Ngoc N. Basic Knowledge of Bone Grafting. *Bone Grafting* 2012. <https://doi.org/10.5772/30442>.
- [10] Czitrom AA. Immunology of Bone Grafting. *Bone Implant Grafting* 1992:3–7. https://doi.org/10.1007/978-1-4471-1934-0_1.
- [11] Learmonth I, Blom A. Bone Graft Substitutes for Impaction Grafting. *Impaction Bone Grafting in Revision Arthroplasty* 2004. <https://doi.org/10.1201/9780203913680.ch10>.
- [12] Çelik M. Craniofacial Bone Grafting. *Bone Grafting - Recent Advances with Special References to*

Cranio-Maxillofacial Surgery 2018. <https://doi.org/10.5772/intechopen.78787>.

- [13] Ramesh A, Varghese S, Jayakumar ND, Malaiappan S. Comparative estimation of sulfiredoxin levels between chronic periodontitis and healthy patients - A case-control study. *J Periodontol* 2018;89:1241–8.
- [14] Paramasivam A, Priyadharsini JV, Raghunandhakumar S, Elumalai P. A novel COVID-19 and its effects on cardiovascular disease. *Hypertens Res* 2020;43:729–30.
- [15] S G, T G, K V, Faleh A A, Sukumaran A, P N S. Development of 3D scaffolds using nanochitosan/silk-fibroin/hyaluronic acid biomaterials for tissue engineering applications. *Int J Biol Macromol* 2018;120:876–85.
- [16] Del Fabbro M, Karanxha L, Panda S, Bucchi C, Nadathur Doraiswamy J, Sankari M, et al. Autologous platelet concentrates for treating periodontal infrabony defects. *Cochrane Database Syst Rev* 2018;11:CD011423.
- [17] Paramasivam A, Vijayashree Priyadharsini J. MitomiRs: new emerging microRNAs in mitochondrial dysfunction and cardiovascular disease. *Hypertens Res* 2020;43:851–3.
- [18] Jayaseelan VP, Arumugam P. Dissecting the theranostic potential of exosomes in autoimmune disorders. *Cell Mol Immunol* 2019;16:935–6.
- [19] Vellappally S, Al Kheraif AA, Divakar DD, Basavarajappa S, Anil S, Fouad H. Tooth implant prosthesis using ultra low power and low cost crystalline carbon bio-tooth sensor with hybridized data acquisition algorithm. *Comput Commun* 2019;148:176–84.
- [20] Vellappally S, Al Kheraif AA, Anil S, Assery MK, Kumar KA, Divakar DD. Analyzing Relationship between Patient and Doctor in Public Dental Health using Particle Memetic Multivariable Logistic Regression Analysis Approach (MLRA2). *J Med Syst* 2018;42:183.
- [21] Varghese SS, Ramesh A, Veeraiyan DN. Blended Module-Based Teaching in Biostatistics and Research Methodology: A Retrospective Study with Postgraduate Dental Students. *J Dent Educ* 2019;83:445–50.
- [22] Venkatesan J, Singh SK, Anil S, Kim S-K, Shim MS. Preparation, Characterization and Biological Applications of Biosynthesized Silver Nanoparticles with Chitosan-Fucoidan Coating. *Molecules* 2018;23. <https://doi.org/10.3390/molecules23061429>.
- [23] Alsubait SA, Al Aylan R, Mitwalli H, Aburaisi N, Mahmood A, Muthurangan M, et al. Cytotoxicity of Different Concentrations of Three Root Canal Sealers on Human Mesenchymal Stem Cells. *Biomolecules* 2018;8. <https://doi.org/10.3390/biom8030068>.
- [24] Venkatesan J, Rekha PD, Anil S, Bhatnagar I, Sudha PN, Dechsakulwatana C, et al. Hydroxyapatite from Cuttlefish Bone: Isolation, Characterizations, and Applications. *Biotechnol Bioprocess Eng* 2018;23:383–93.
- [25] Vellappally S, Al Kheraif AA, Anil S, Wahba AA. IoT medical tooth mounted sensor for monitoring teeth and food level using bacterial optimization along with adaptive deep learning neural network. *Measurement* 2019;135:672–7.
- [26] PradeepKumar AR, Shemesh H, Nivedhitha MS, Hashir MMJ, Arockiam S, Uma Maheswari TN, et al. Diagnosis of Vertical Root Fractures by Cone-beam Computed Tomography in Root-filled Teeth with Confirmation by Direct Visualization: A Systematic Review and Meta-Analysis. *J Endod* 2021;47:1198–214.
- [27] R H, Ramani P, Tilakaratne WM, Sukumaran G, Ramasubramanian A, Krishnan RP. Critical appraisal of different triggering pathways for the pathobiology of pemphigus vulgaris-A review. *Oral Dis* 2021. <https://doi.org/10.1111/odi.13937>.
- [28] Ezhilarasan D, Lakshmi T, Subha M, Deepak Nallasamy V, Raghunandhakumar S. The ambiguous role of sirtuins in head and neck squamous cell carcinoma. *Oral Dis* 2021. <https://doi.org/10.1111/odi.13798>.
- [29] Sarode SC, Gondivkar S, Sarode GS, Gadbaile A, Yuwanati M. Hybrid oral potentially malignant disorder: A neglected fact in oral submucous fibrosis. *Oral Oncol* 2021:105390.
- [30] Kavarthapu A, Gurumoorthy K. Linking chronic periodontitis and oral cancer: A review. *Oral Oncol* 2021:105375.
- [31] Vellappally S, Abdullah Al-Kheraif A, Anil S, Basavarajappa S, Hassanein AS. Maintaining patient oral health by using a xeno-genetic spiking neural network. *J Ambient Intell Humaniz Comput* 2018. <https://doi.org/10.1007/s12652-018-1166-8>.
- [32] Aldhuwayhi S, Mallineni SK, Sakhamuri S, Thakare AA, Mallineni S, Sajja R, et al. Covid-19 Knowledge and Perceptions Among Dental Specialists: A Cross-Sectional Online Questionnaire

- Survey. Risk Manag Healthc Policy 2021;14:2851–61.
- [33] Sheikh Z, Sima C, Glogauer M. Bone Replacement Materials and Techniques Used for Achieving Vertical Alveolar Bone Augmentation. *Materials* 2015;8:2953–93. <https://doi.org/10.3390/ma8062953>.
- [34] McAllister BS, Haghghat K. Bone Augmentation Techniques. *Journal of Periodontology* 2007;78:377–96. <https://doi.org/10.1902/jop.2007.060048>.
- [35] Palmer RM, Howe LC, Palmer PJ. *Implants in Clinical Dentistry*. CRC Press; 2002.
- [36] Tsesis I, Nemcovsky CE, Nissan J, Rosen E. *Endodontic-Periodontal Lesions: Evidence-Based Multidisciplinary Clinical Management*. Springer; 2019.
- [37] Jensen OT. *Alveolar Distraction Osteogenesis*. Quintessence Publishing (IL); 2002.
- [38] Adel-Khattab D. Autogenous Bone Ring with and without Simultaneous Implant Placement for Localized Alveolar Ridge Augmentation (Clinical Study) n.d. <https://doi.org/10.26226/morressier.5ac3832c2afeeb00097a3919>.
- [39] Palacci P. Classification of Alveolar Ridge Defects in Implant Dentistry. *Horizontal Alveolar Ridge Augmentation in Implant Dentistry: A Surgical Manual* 2016:72–80. <https://doi.org/10.1002/9781119019916.ch07>.
- [40] Simoncic B. Stem Cell based Alveolar Ridge Regeneration Technique n.d. <https://doi.org/10.26226/morressier.5ac3831d2afeeb00097a38ee>.